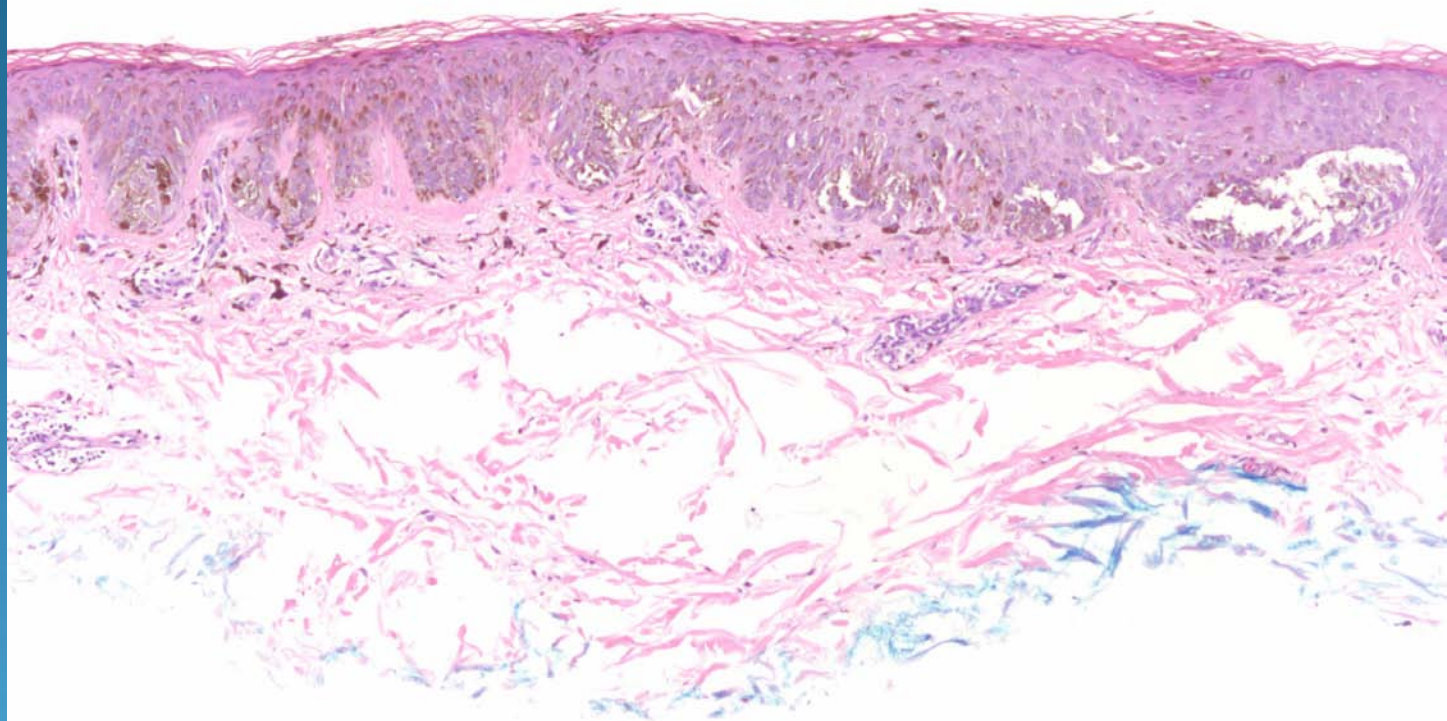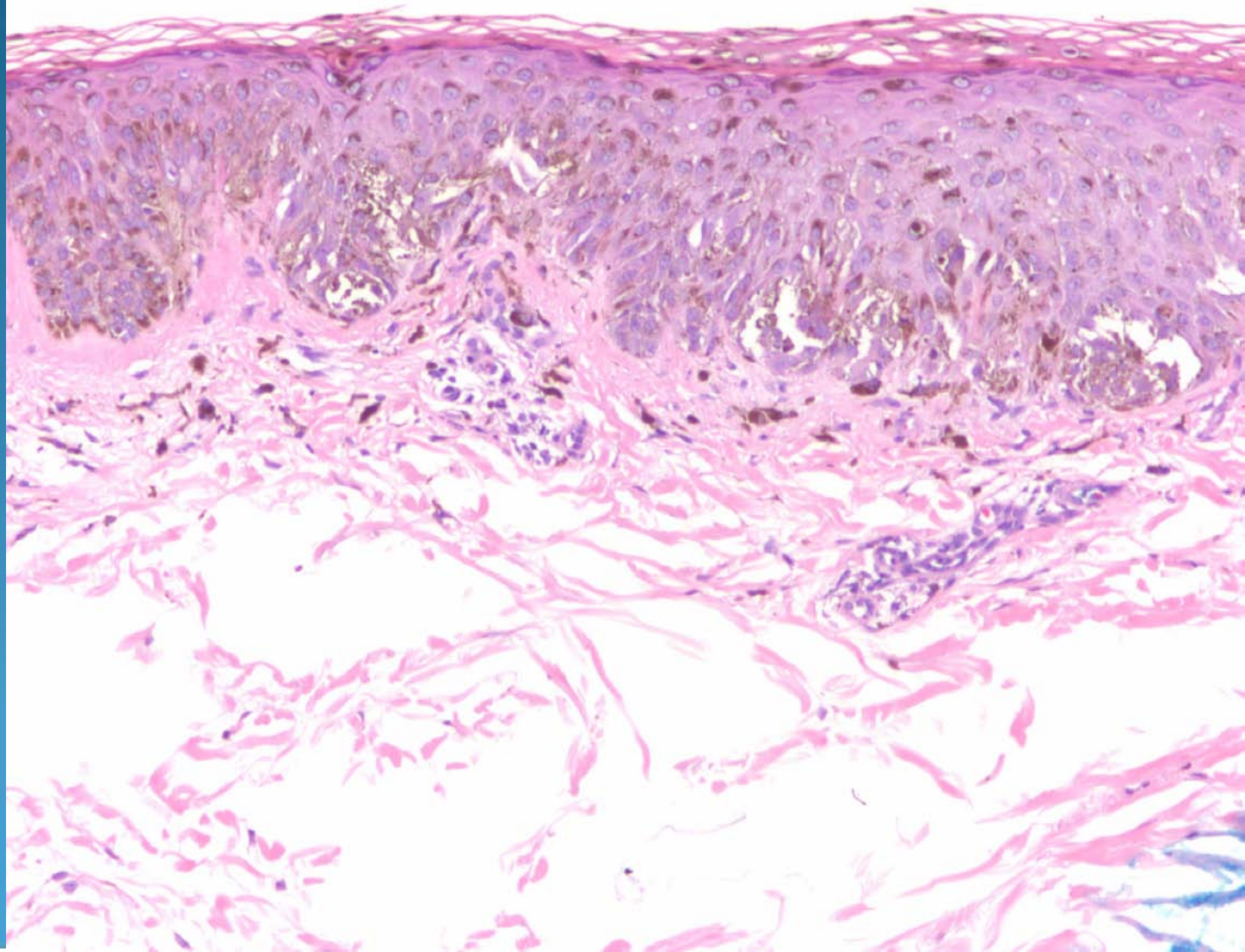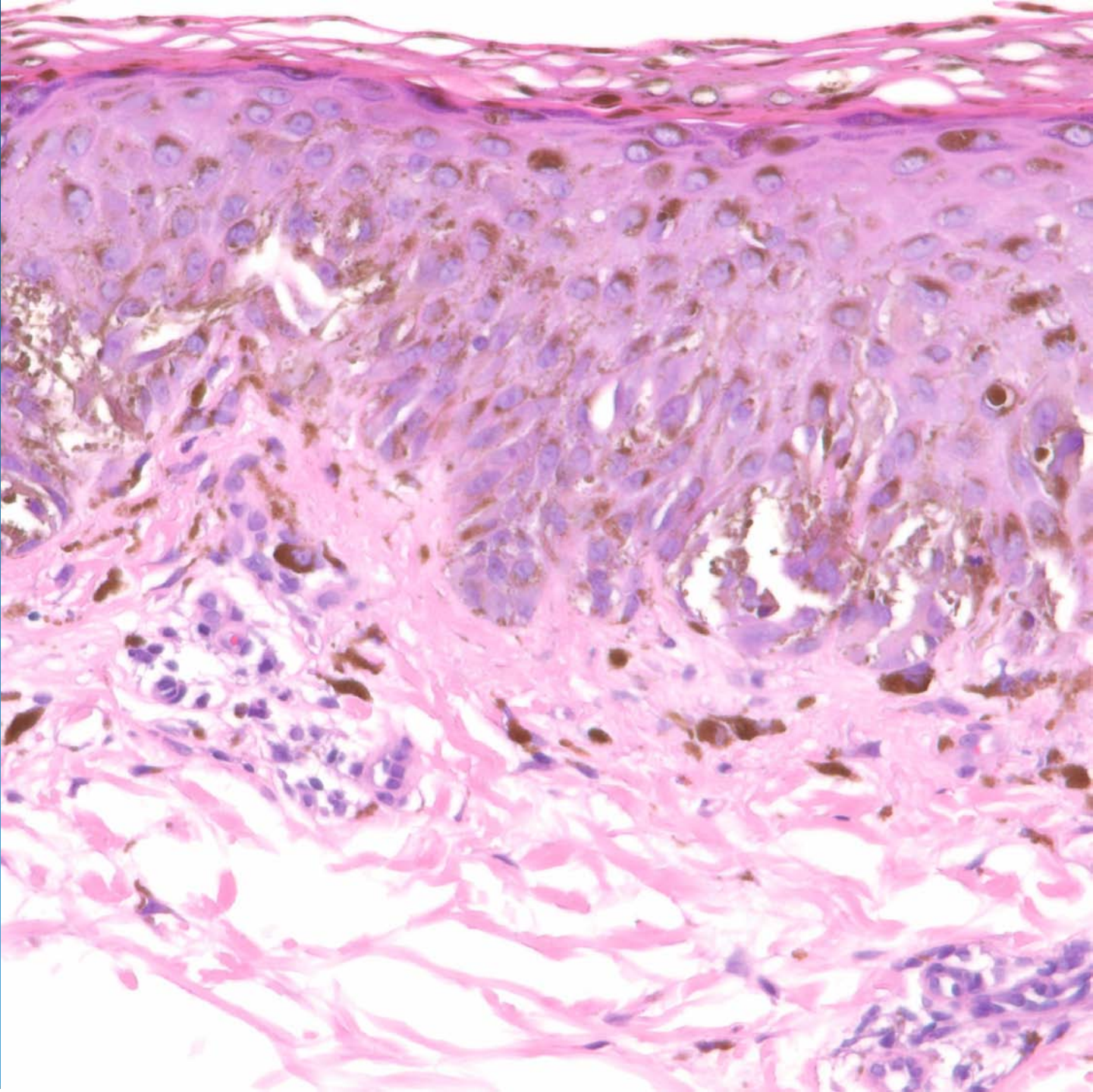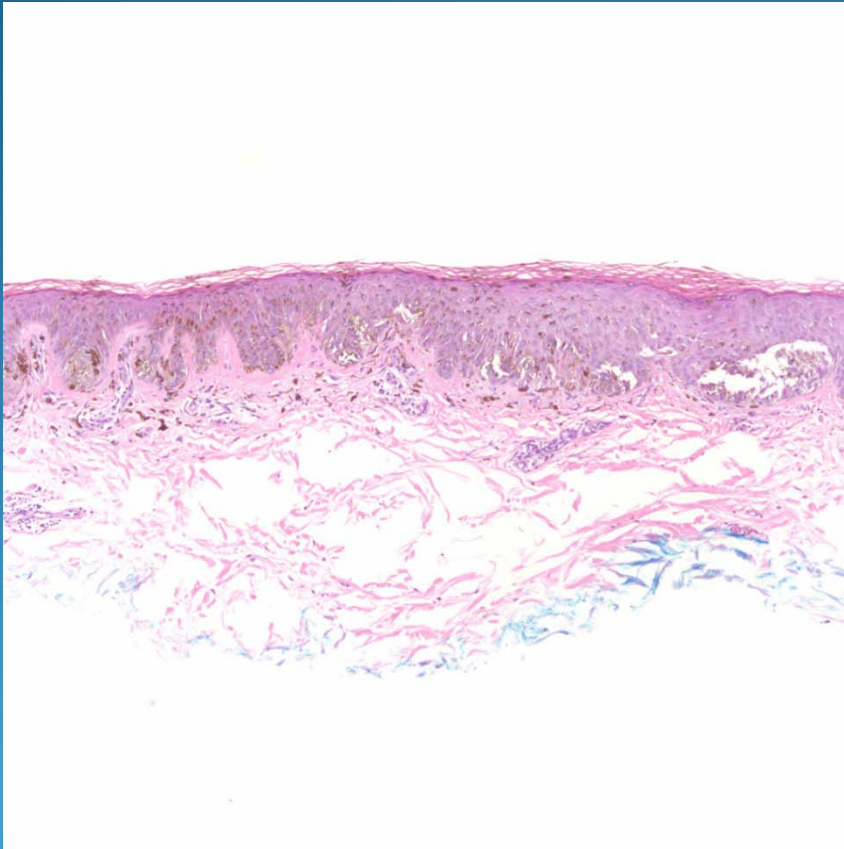


Pigmented Spindle Cell Nevus

Pearls



- Circumscribed proliferation of spindled melanocytes with heavy but even melanin pigmentation
- Minimal variation in size and shape of melanocytes