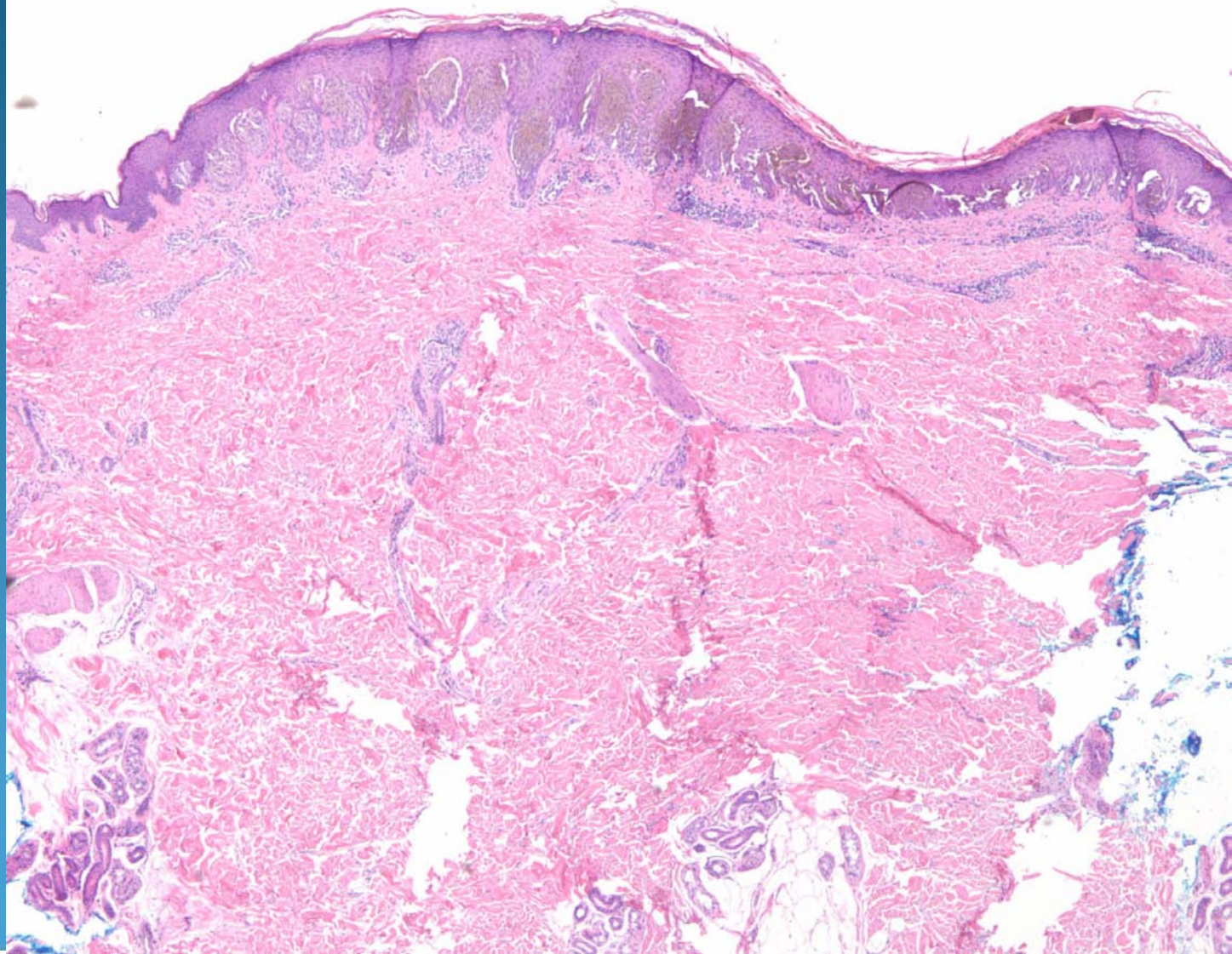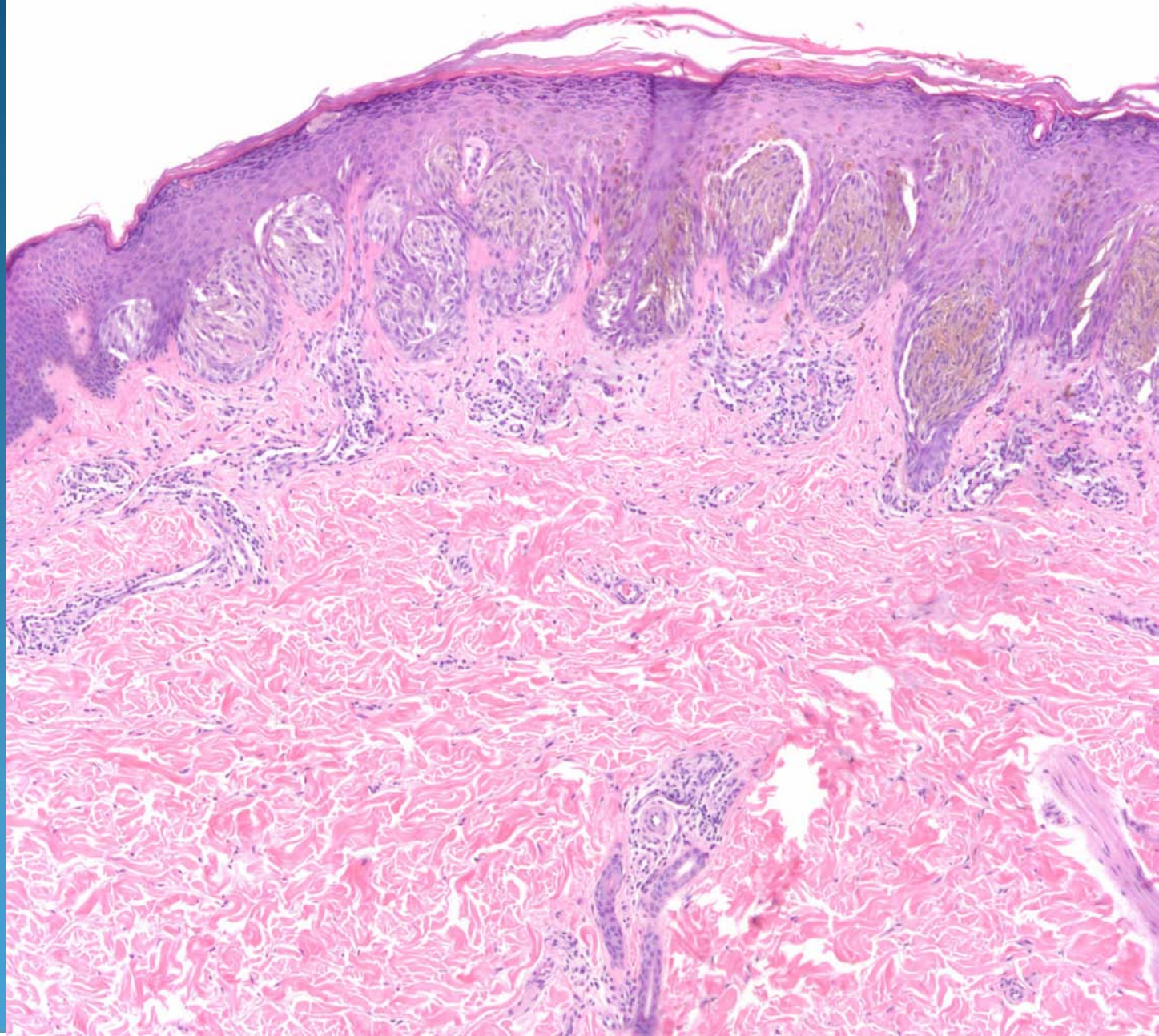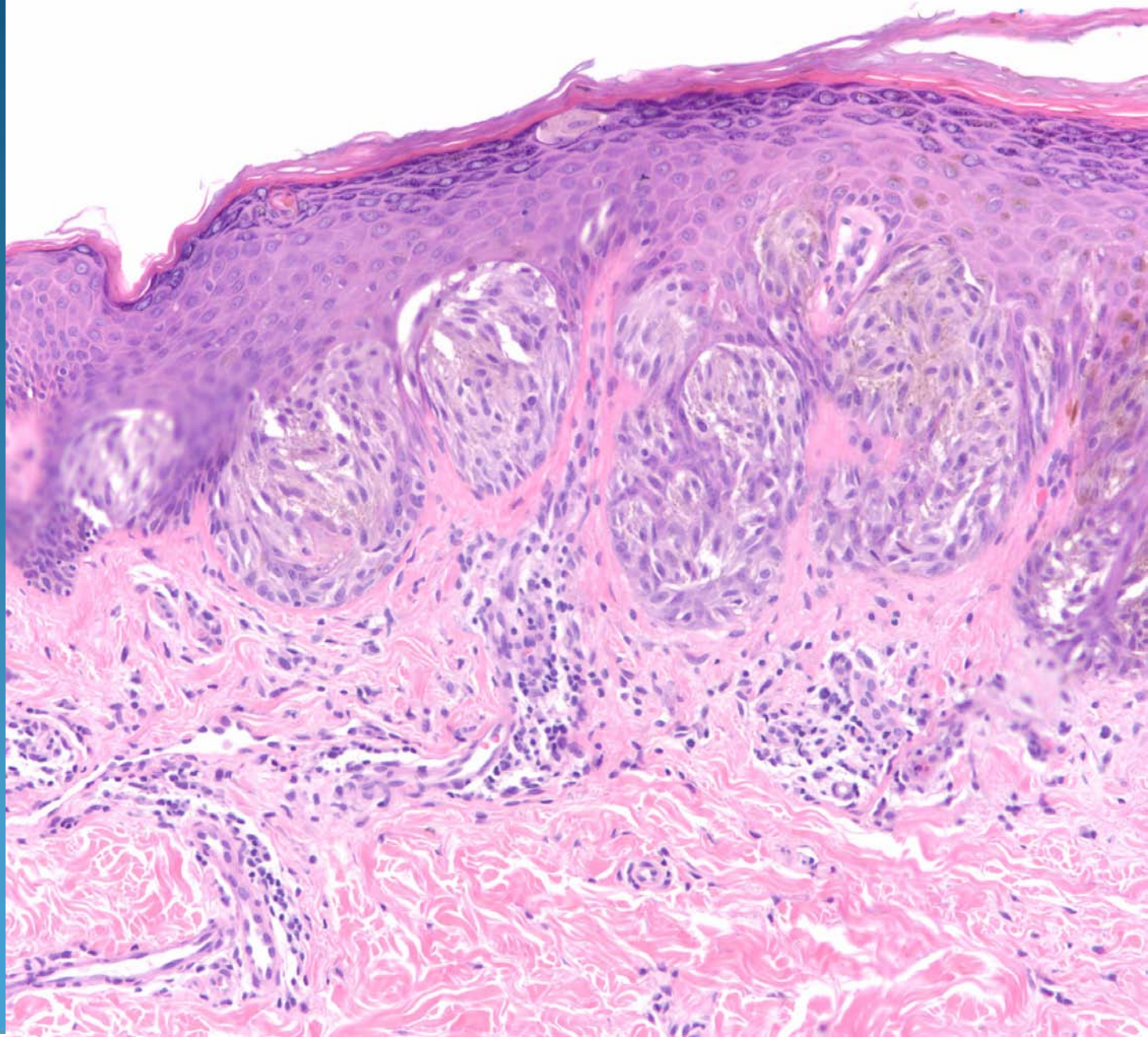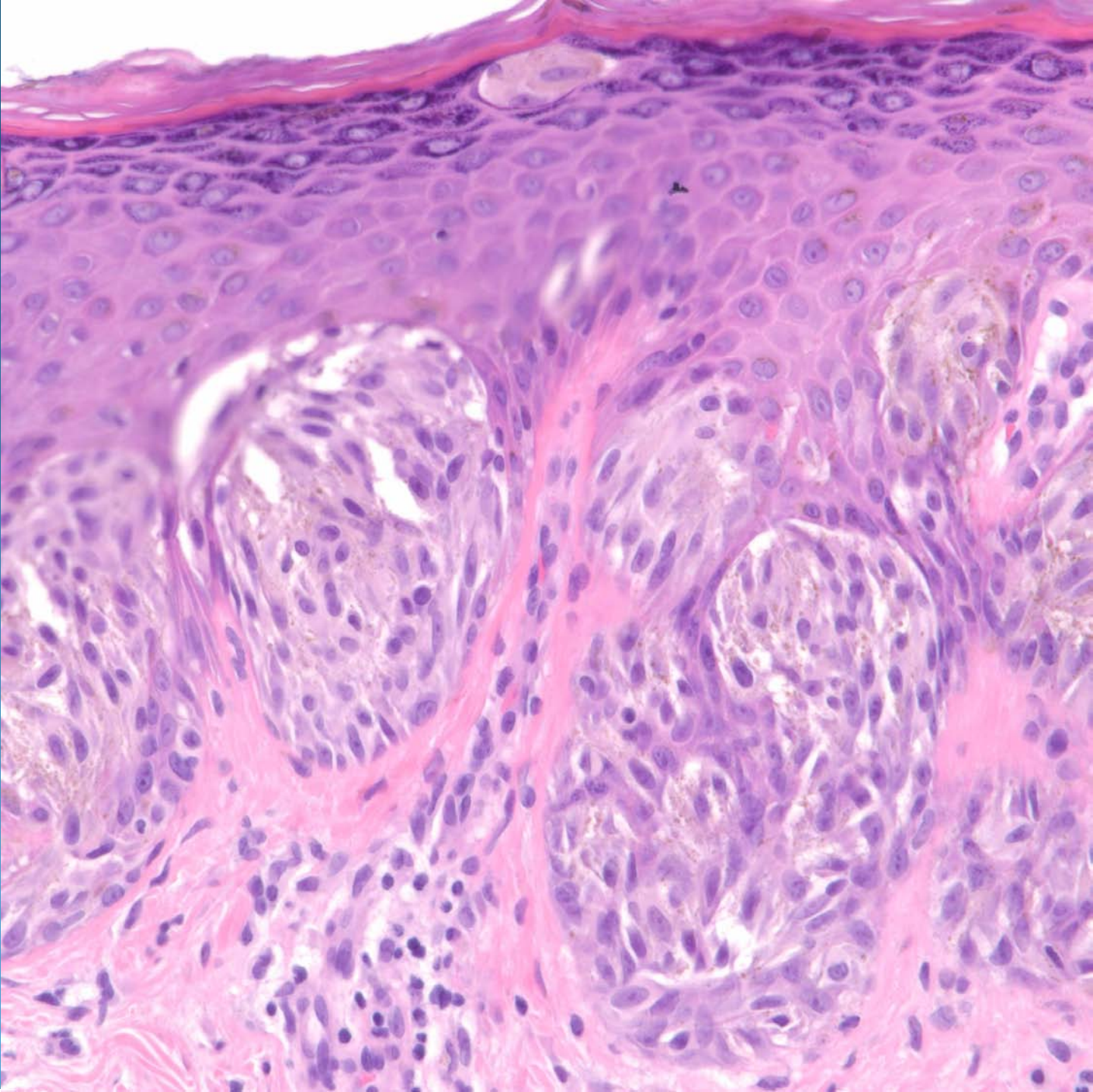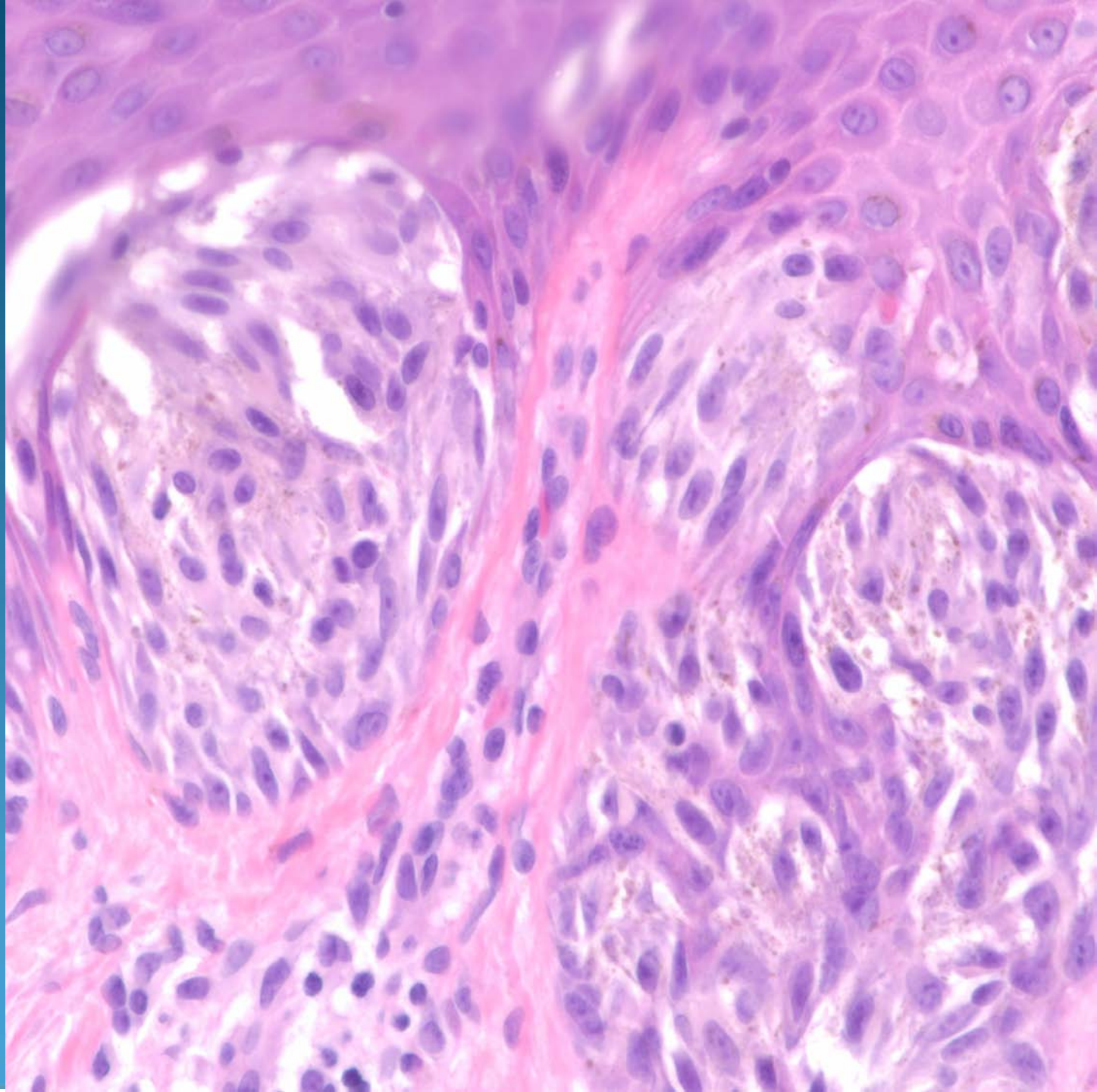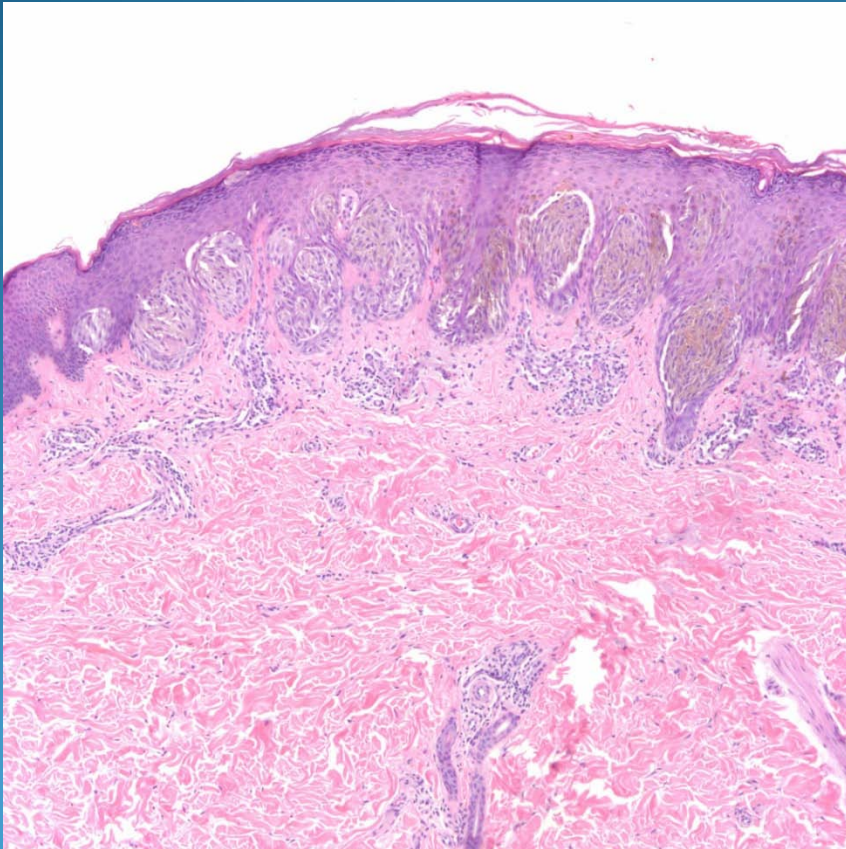


Pigmented Spindle Cell Nevus

Pearls



- Melanocytic nevus with spindled melanocytes and heavy but even melanin pigmentation
- Sharp peripheral circumscription
- Kamino bodies uncommon
- Minimal cytologic atypia