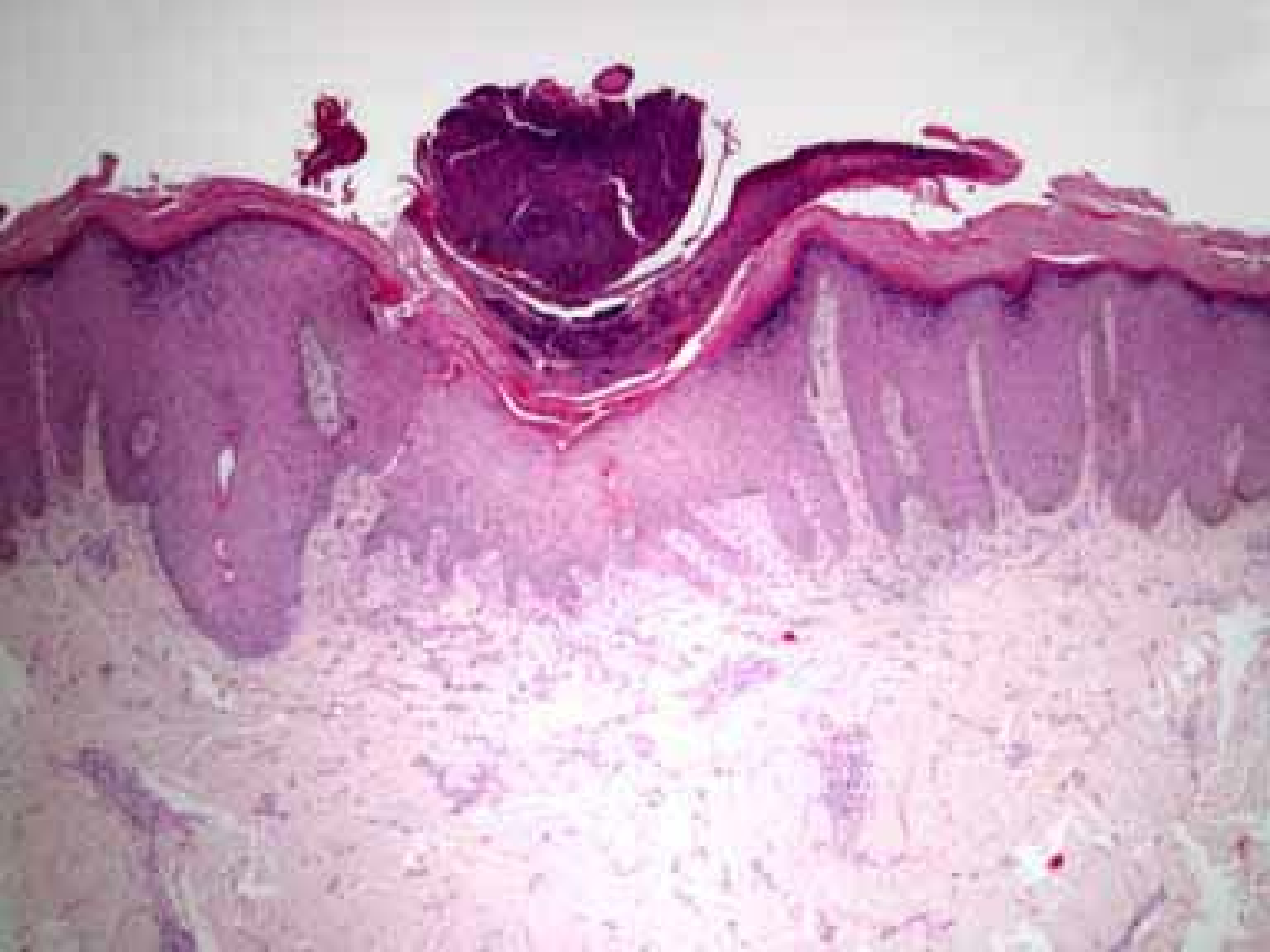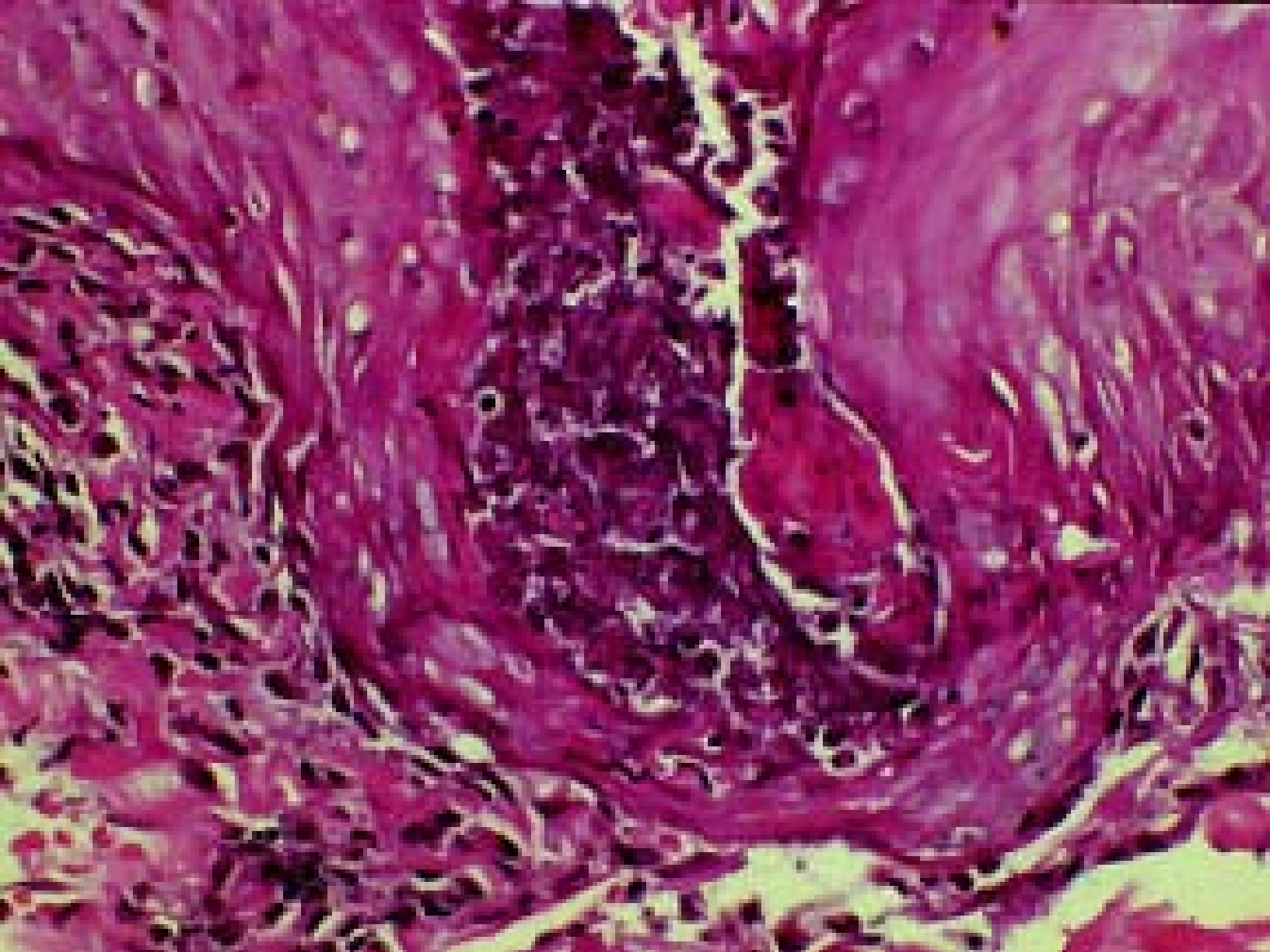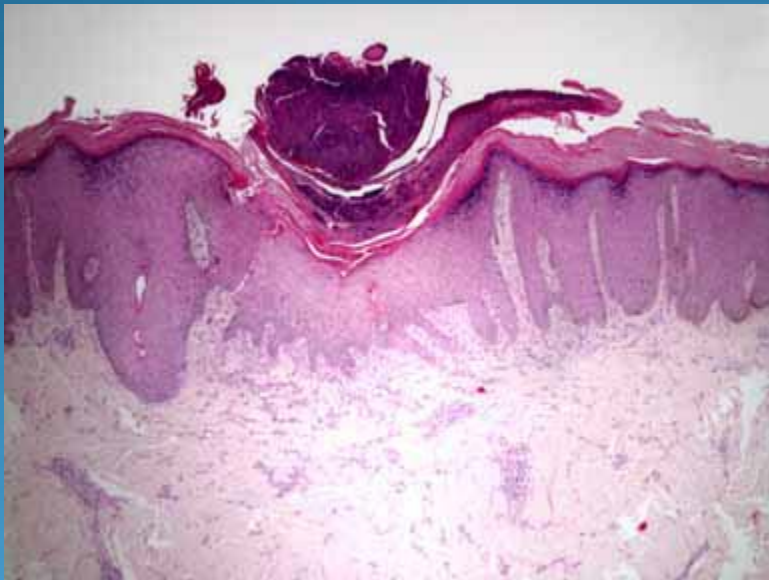


Perforating folliculitis- Kyrle's Disease

Pearls



- Keratotic plug on top of follicle
- Hyperkeratosis and acanthosis
- Basophilic amorphous material in follicle (transepidermal elimination)