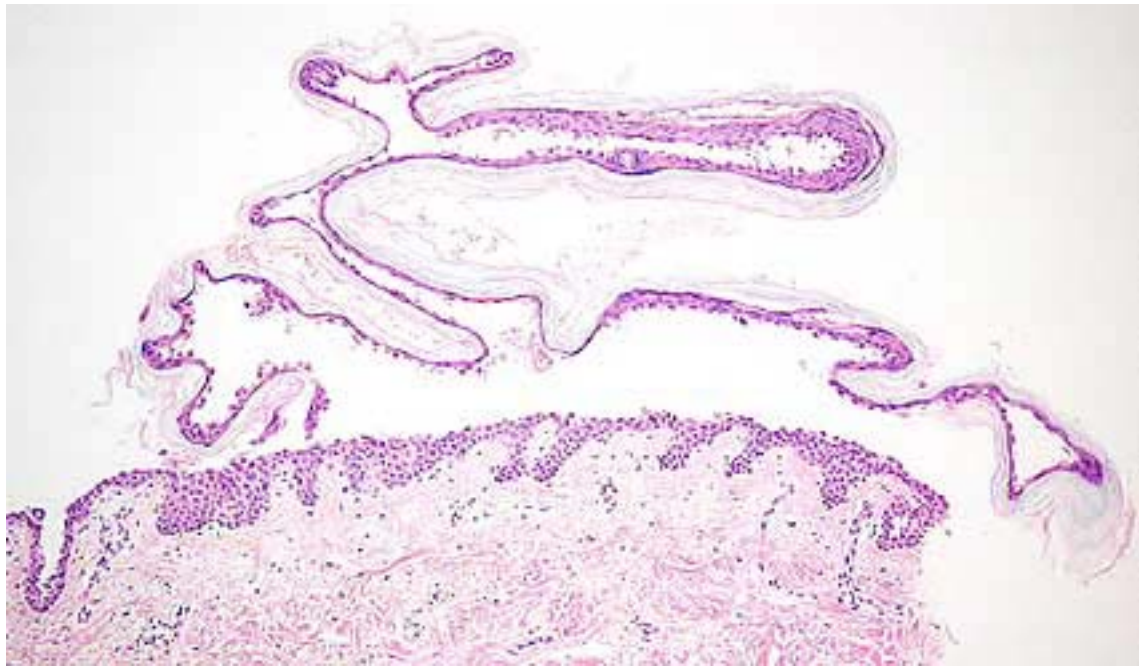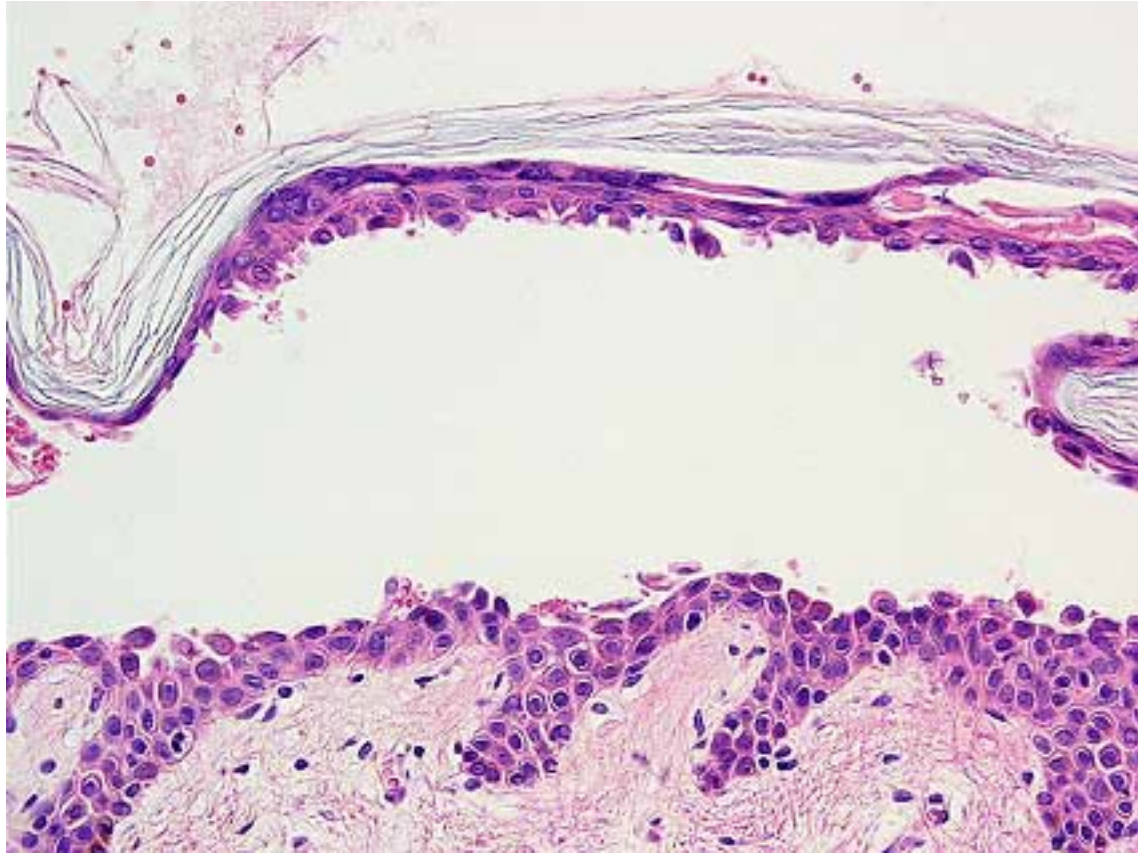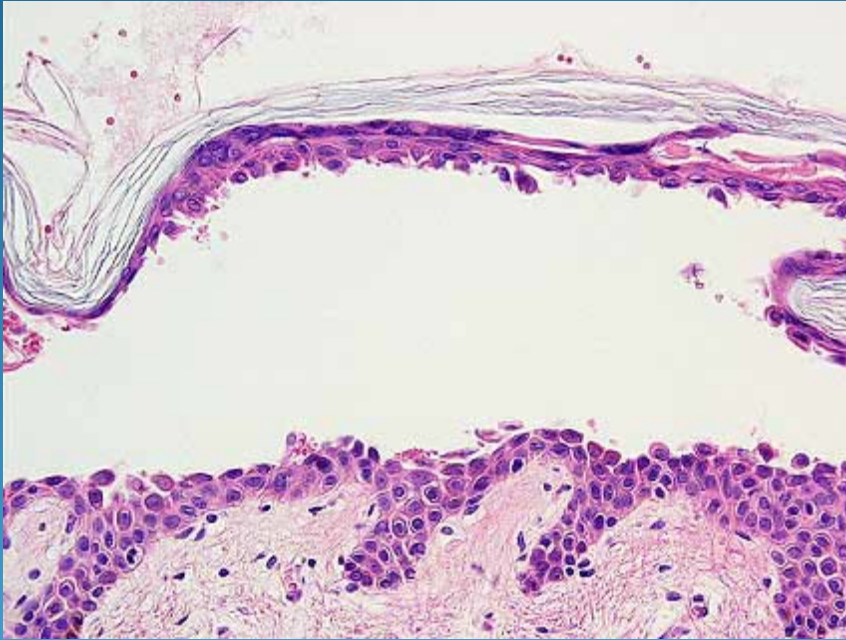


Pemphigus Erythematosis

Pearls



- Subcorneal/
intragranular split
- Acantholytic cells poking
up
- Minimally inflamed with
few neutrophils