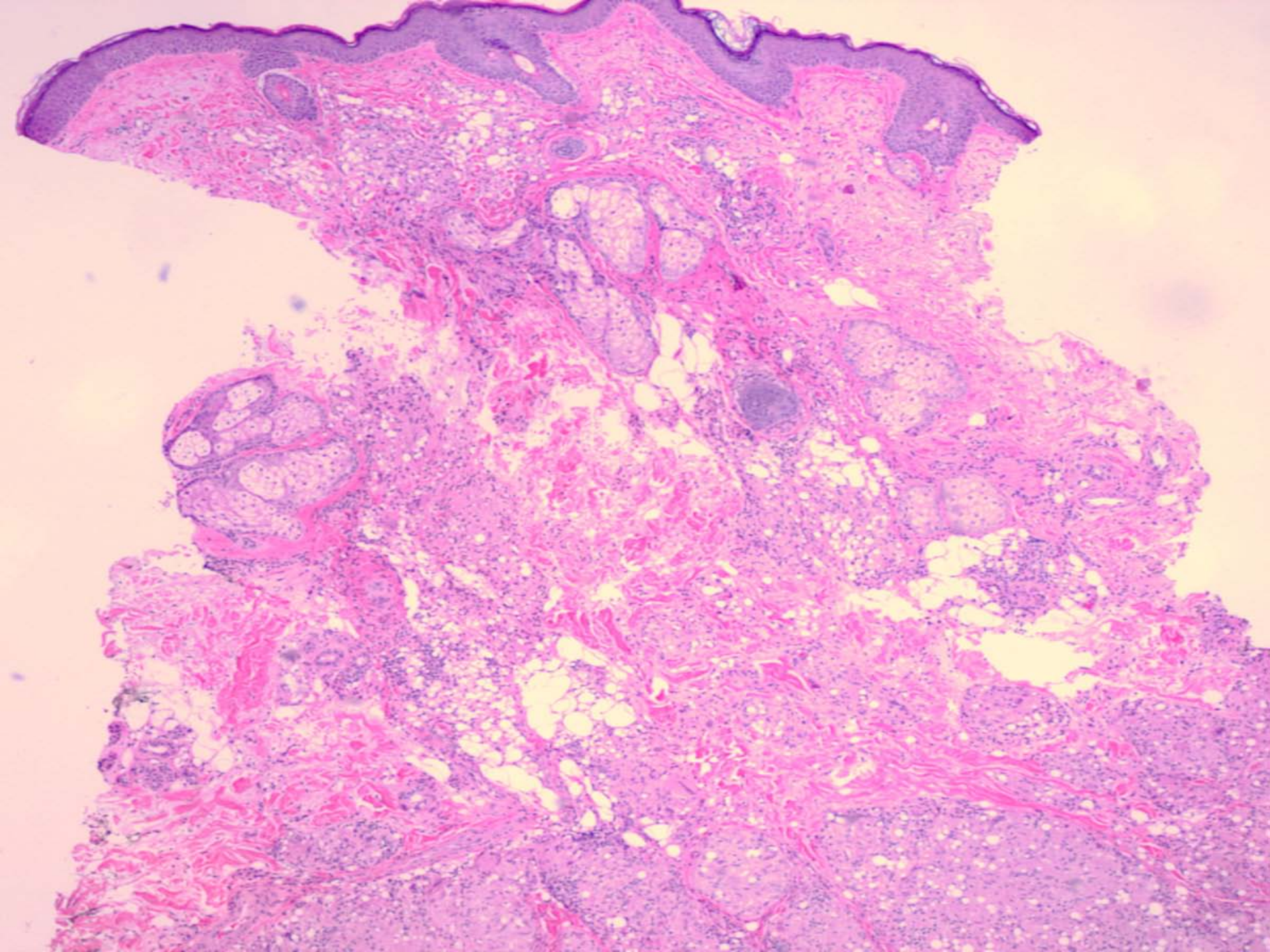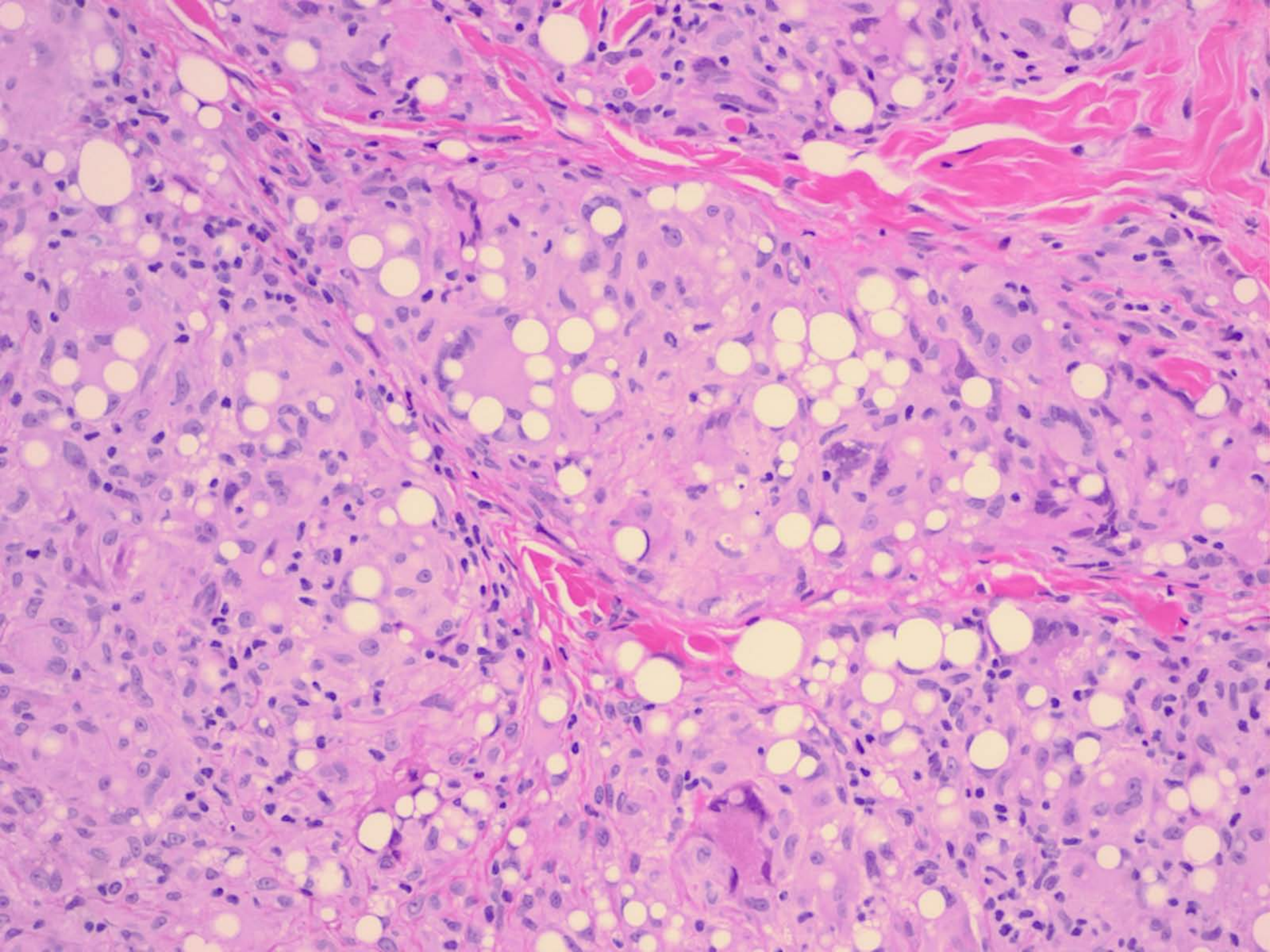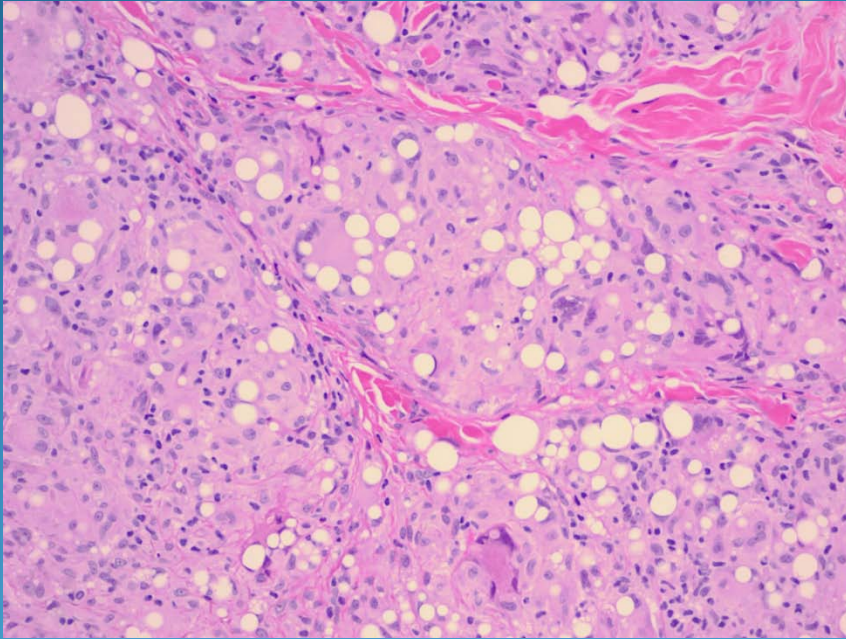


# Paraffinoma/ Sclerosing Lipogranuloma

# Pearls



- May have no epidermis
- Waxy, red (sclerotic) stroma with big holes-  
vacuoles
- “Swiss cheese” appearance
- No lipomembranous  
changes