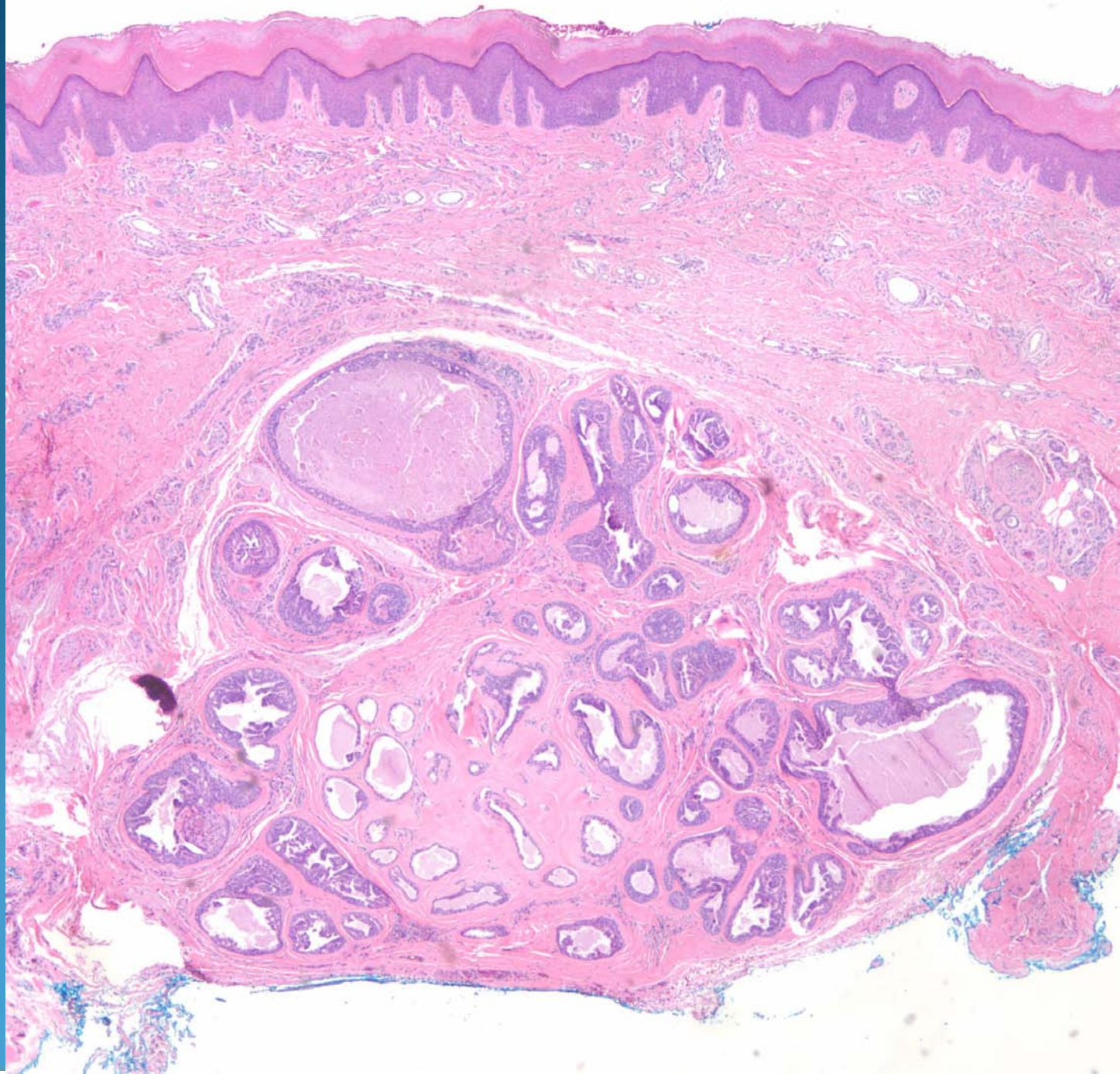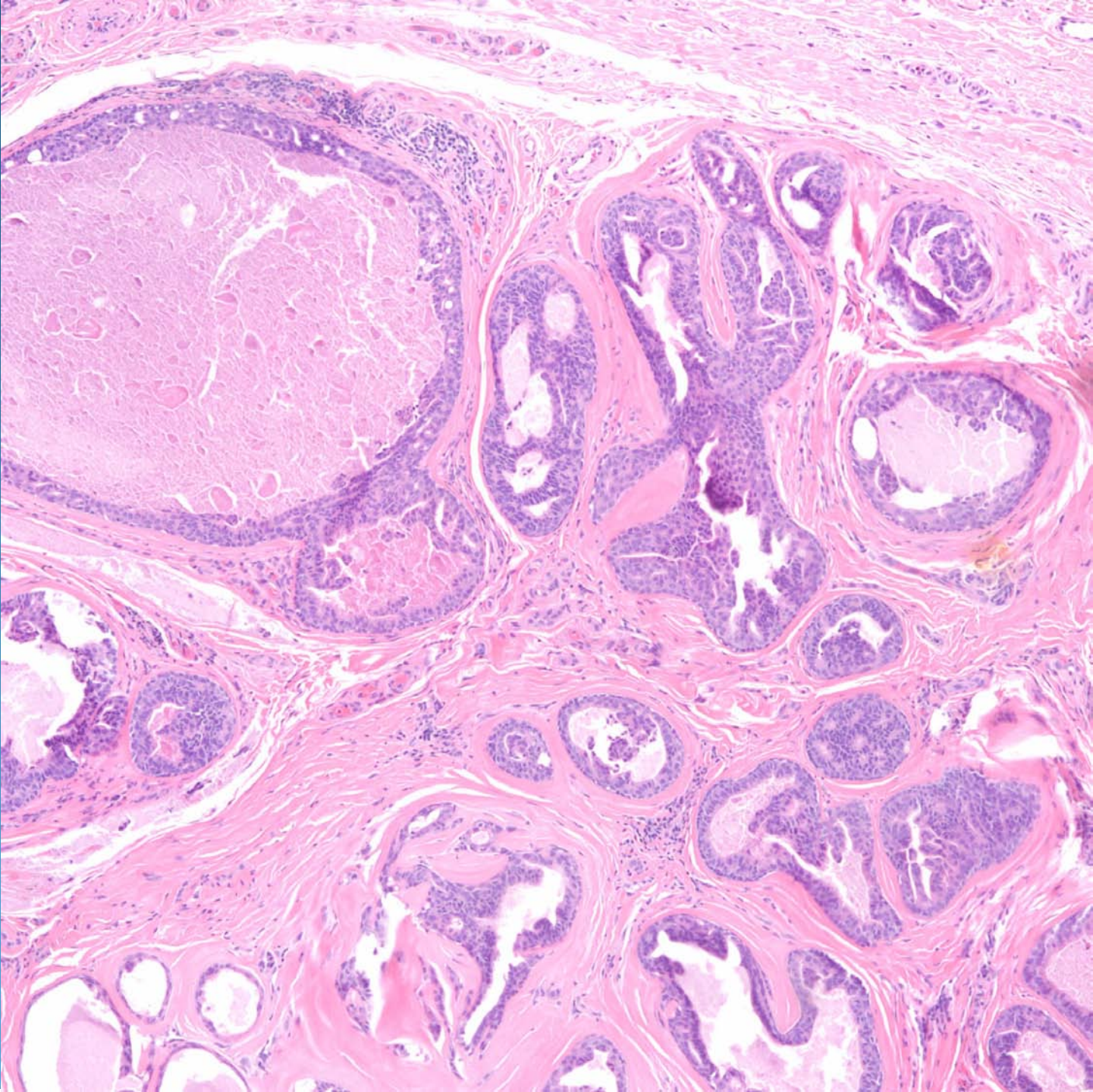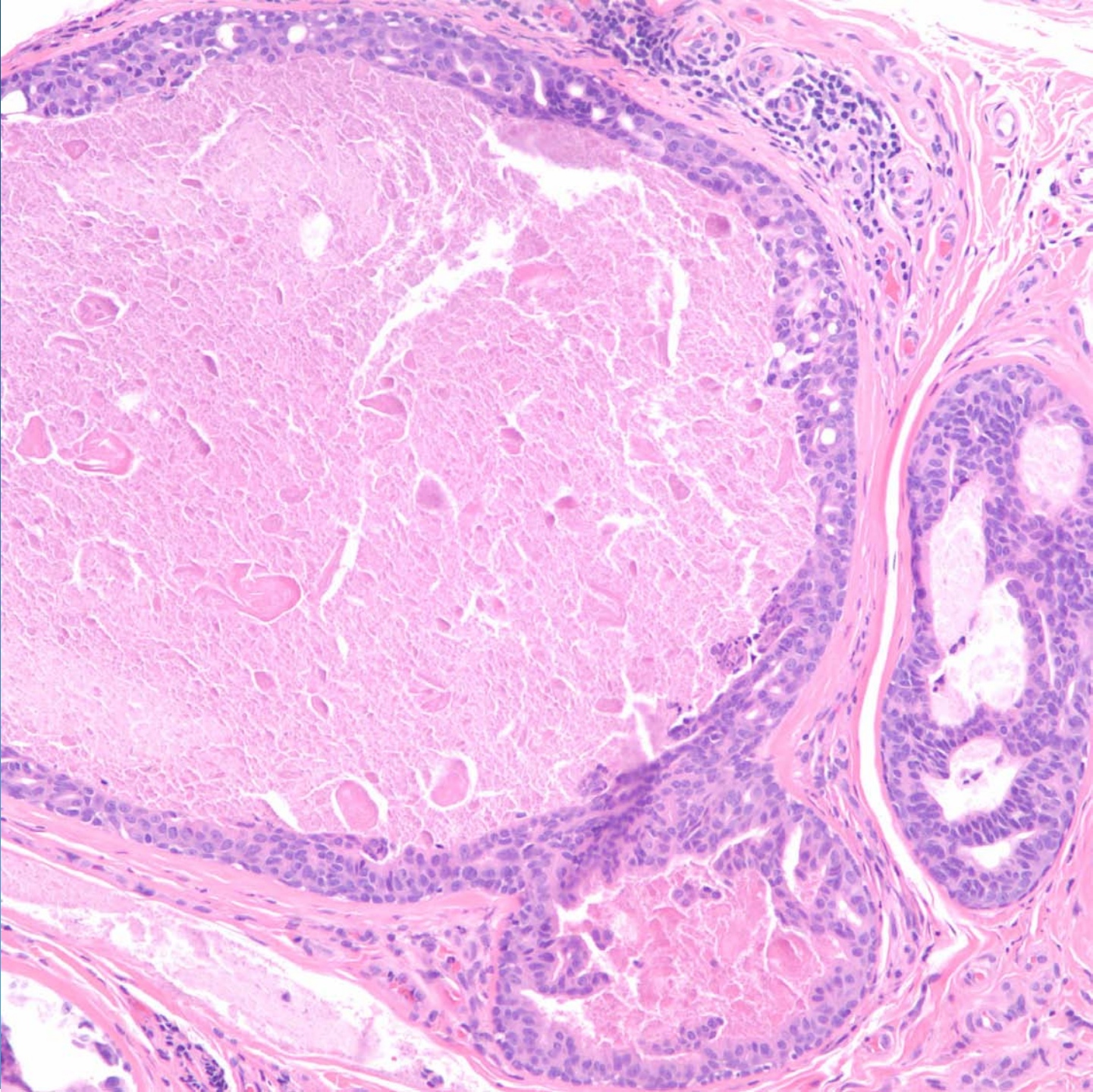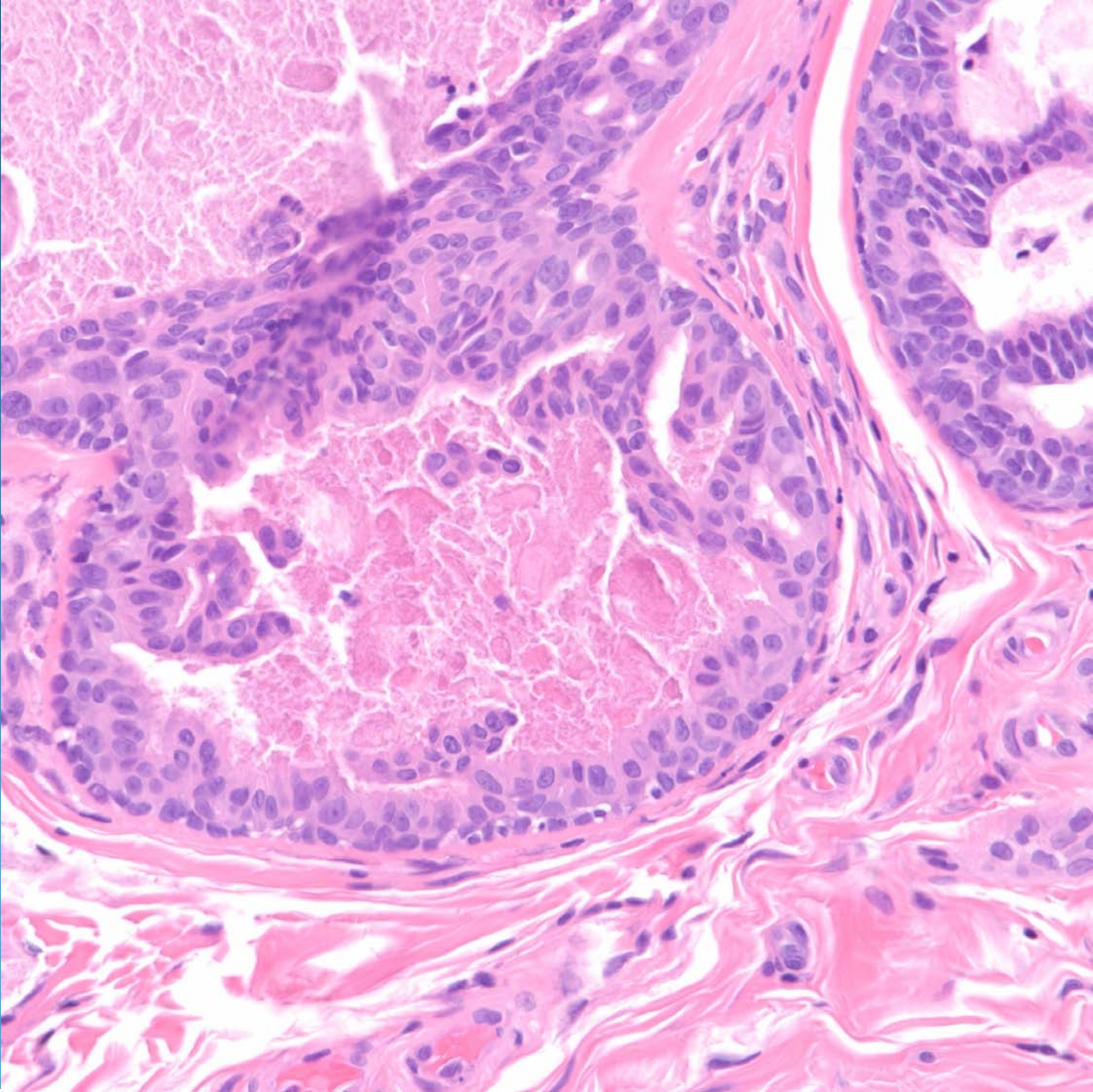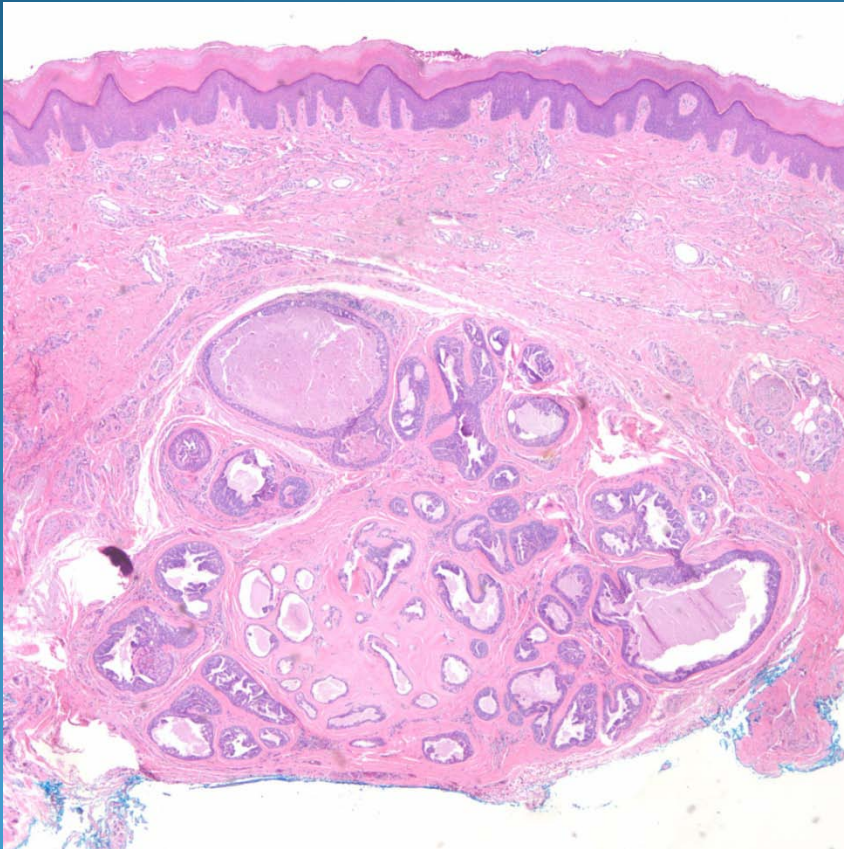


Papillary Eccrine Adenoma

Pearls



- Collection of ducts and glands with micro-papillary intraluminal projections
- May have necrosis
- Minimal cytologic atypia of epithelial cells
- Resembles DCIS of the breast