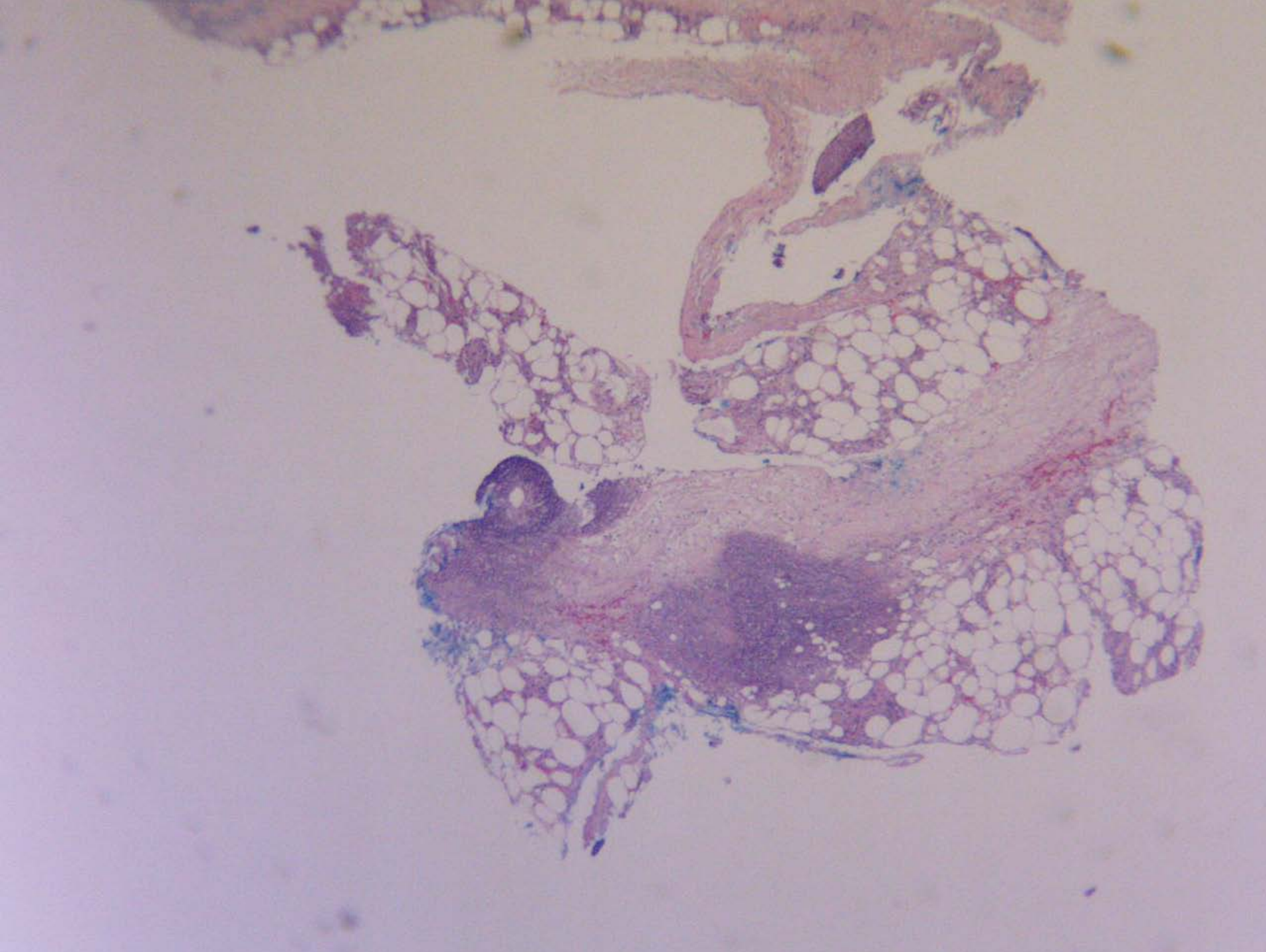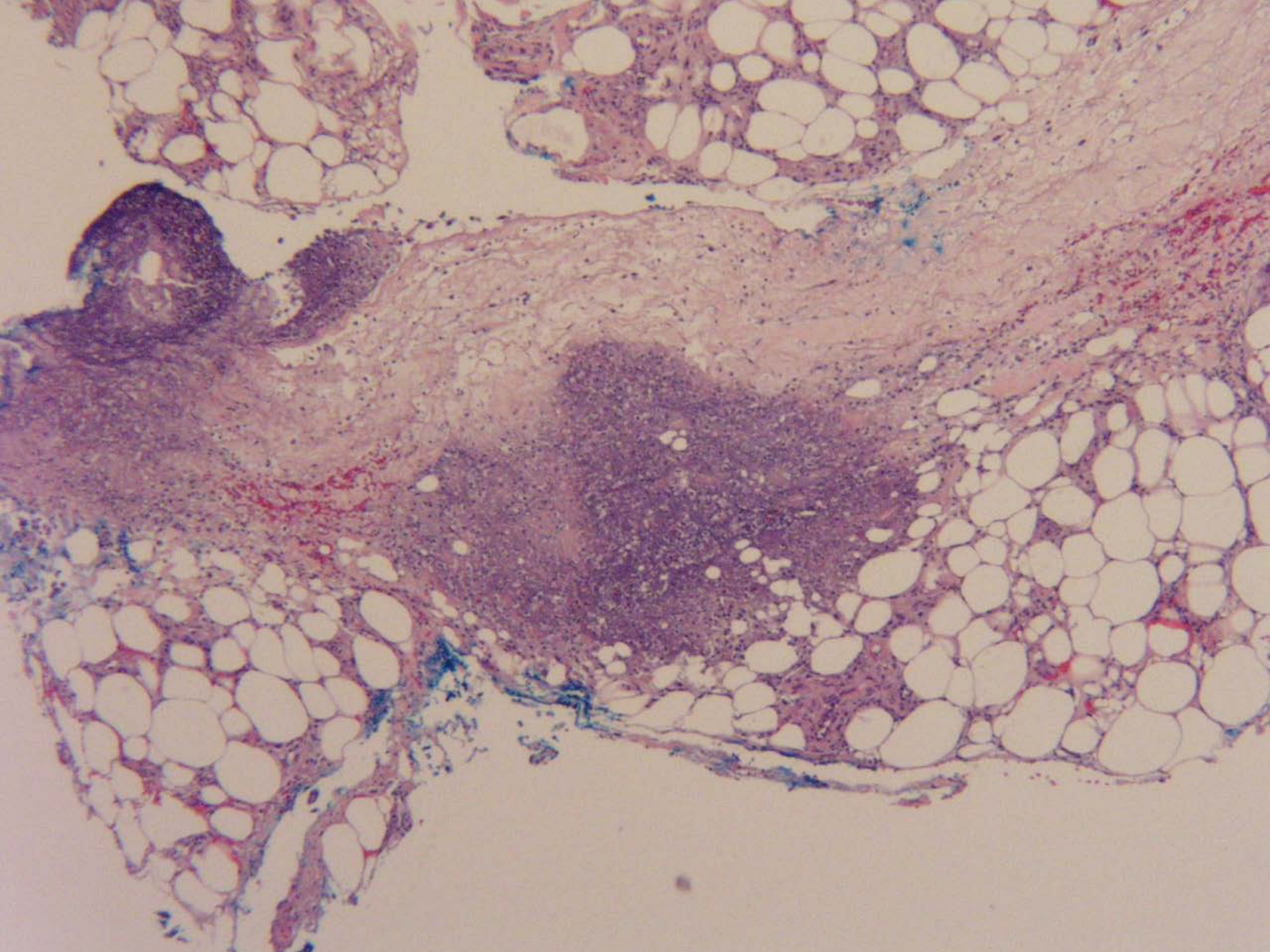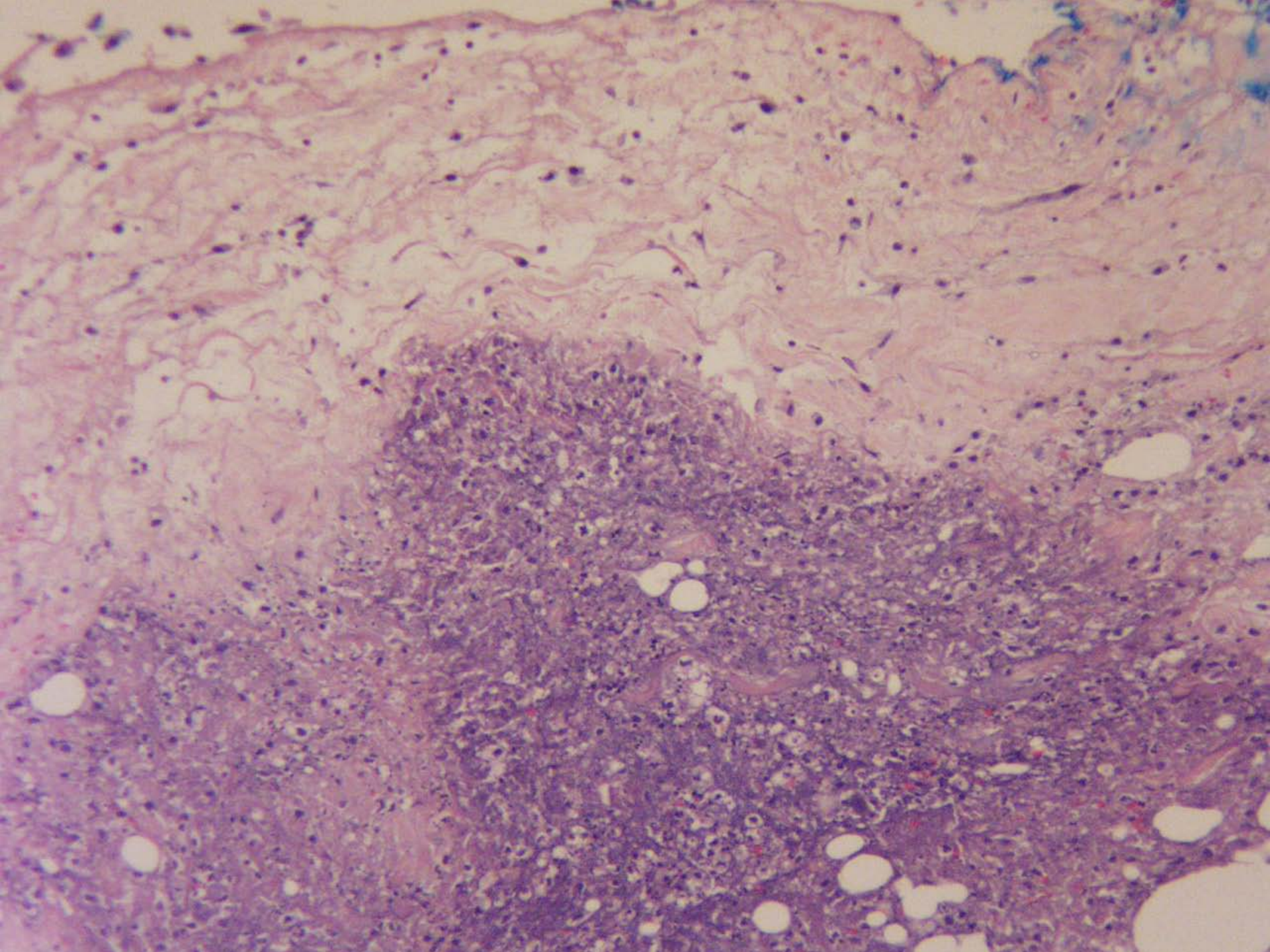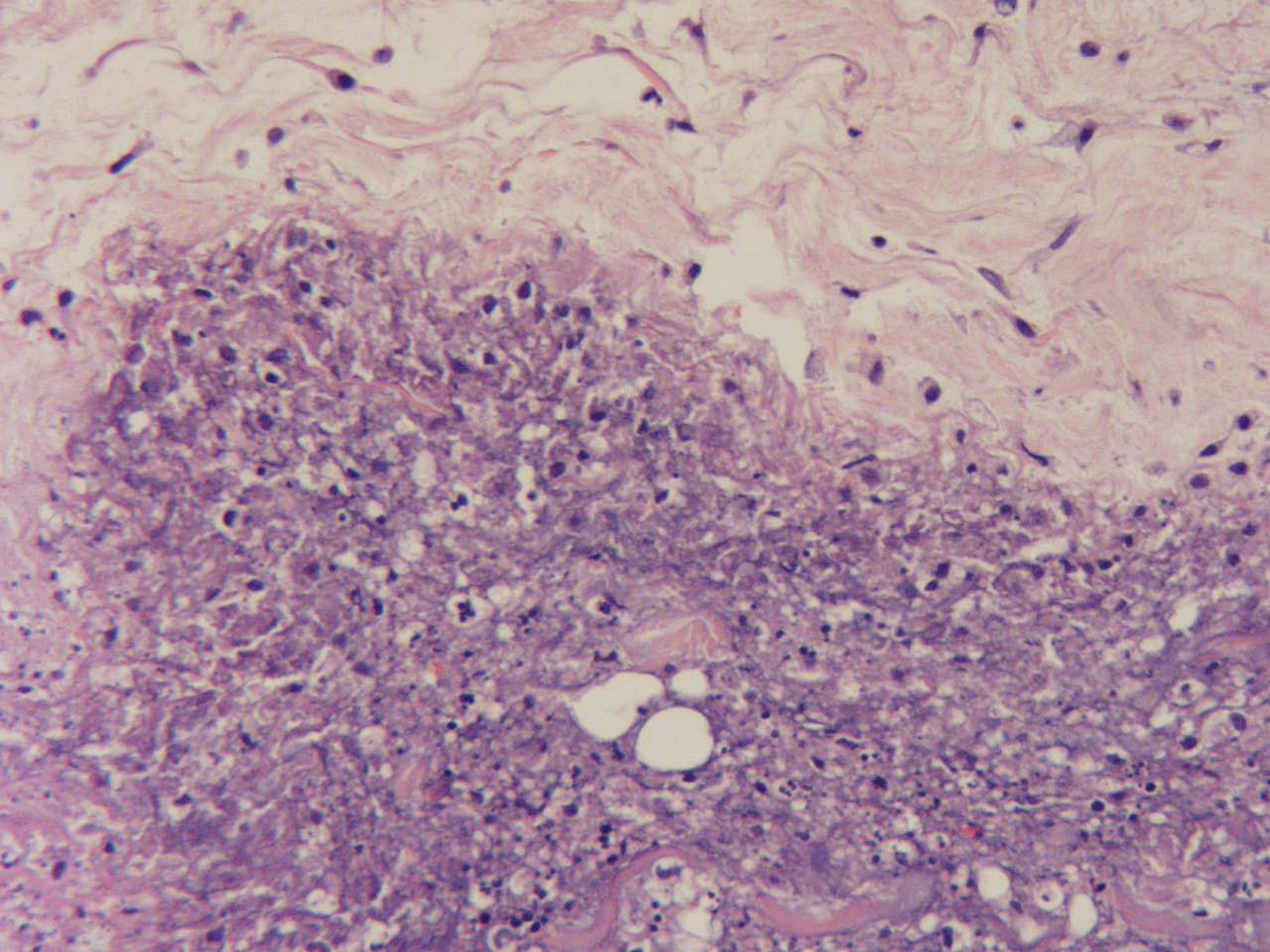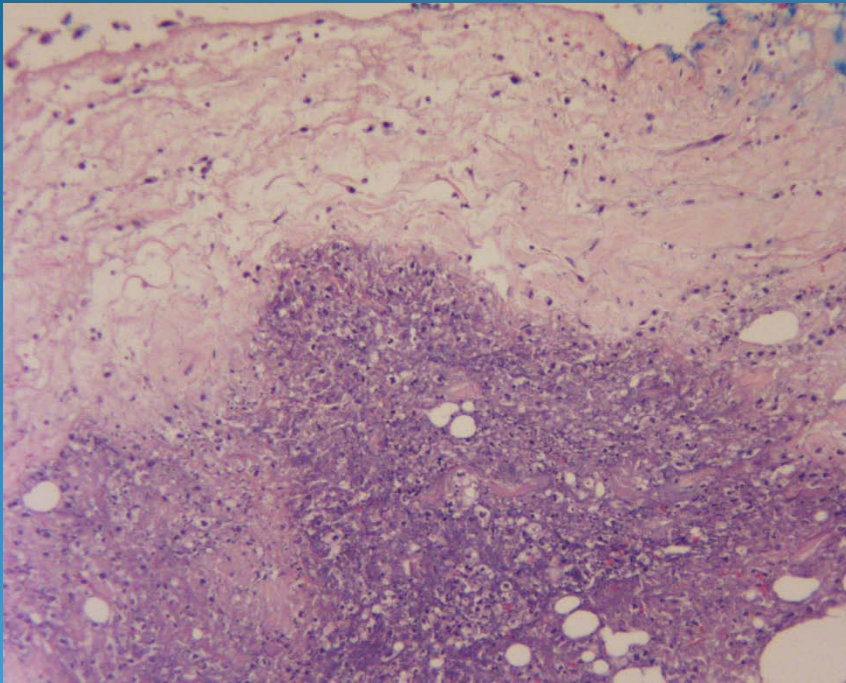


Pancreatic Fat Necrosis

Pearls



- Pink degeneration of adipocytes surrounded by blue calcified rim and neutrophils
- Small foci of abnormal fat, not entire subcutaneous fat involved