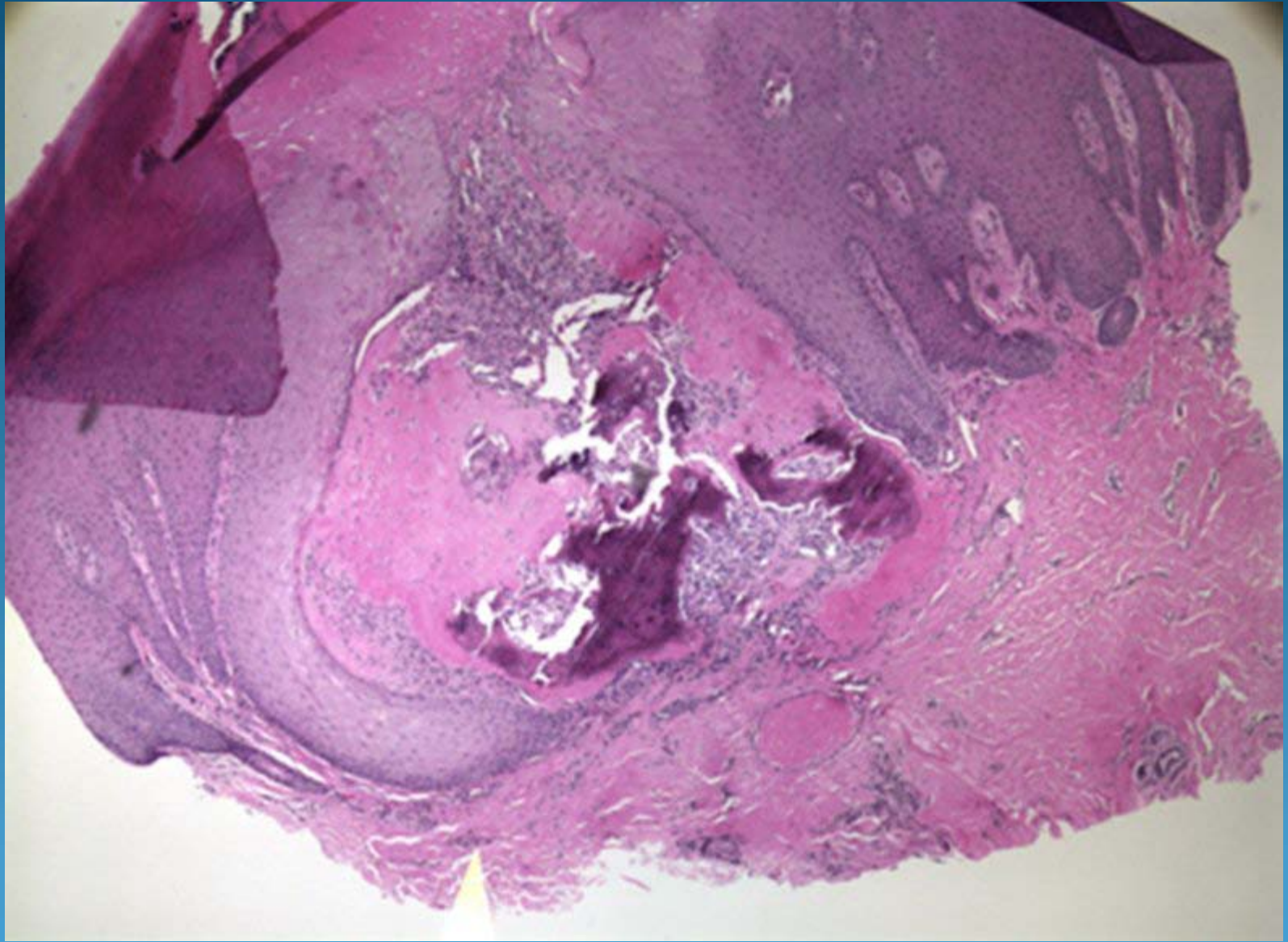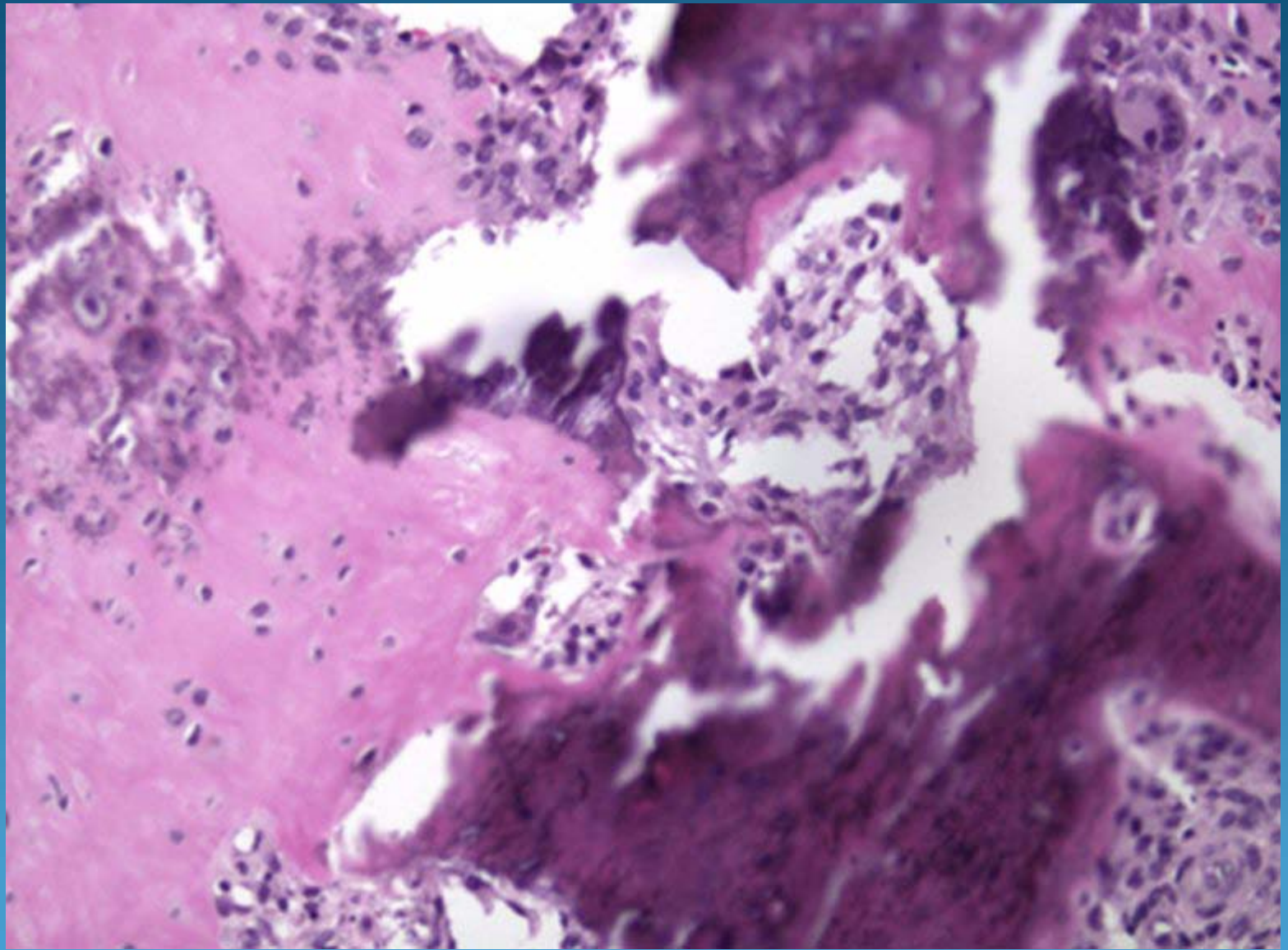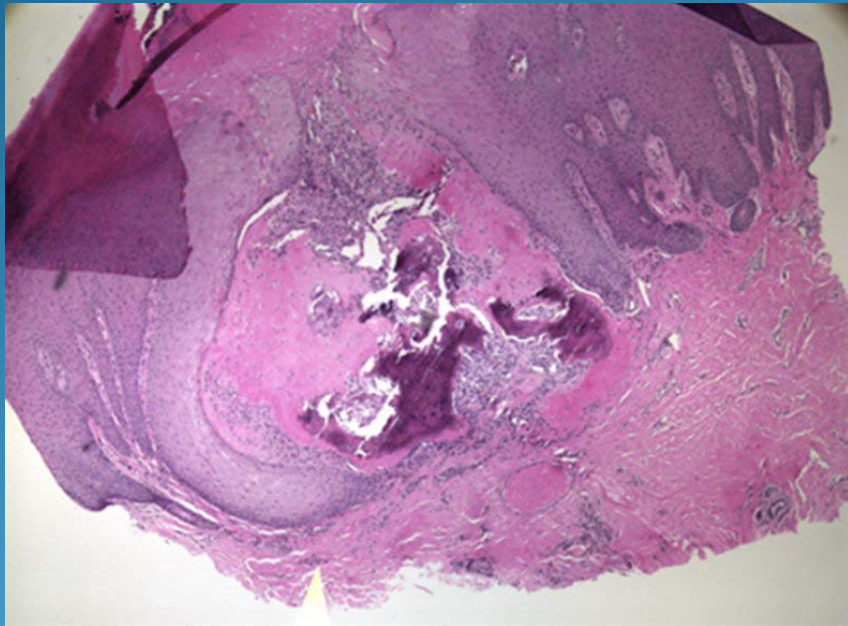


Osteoma Cutis

Pearls



- Bone spicules and Haversian canals
- Look for calcium and ghost cells to rule out ossified pilomatricoma