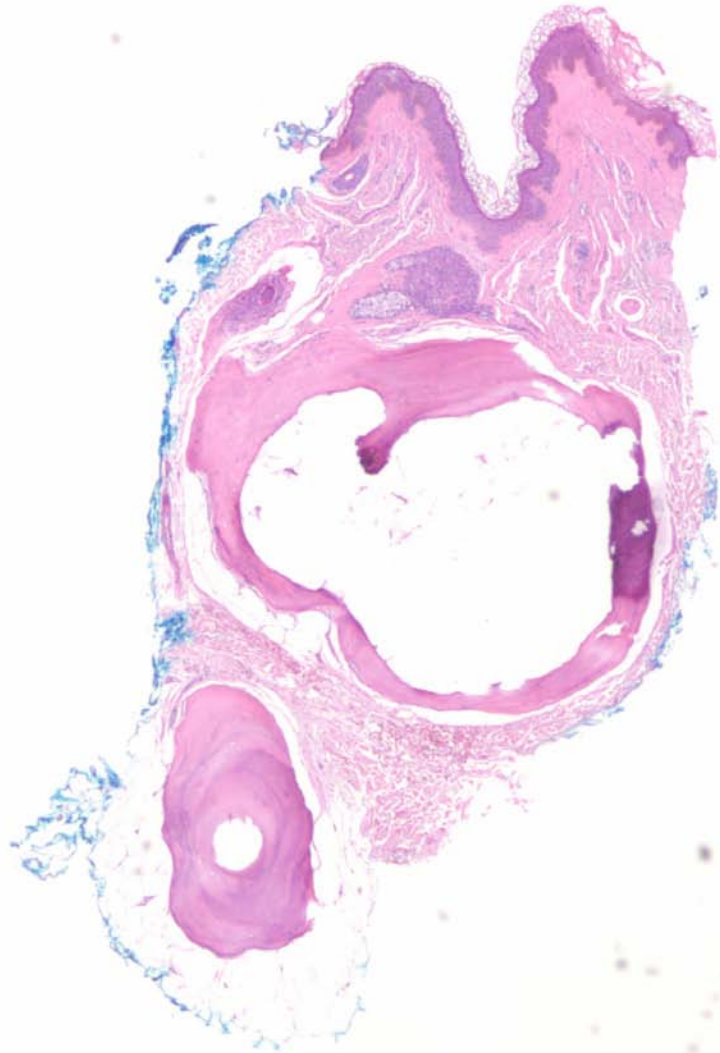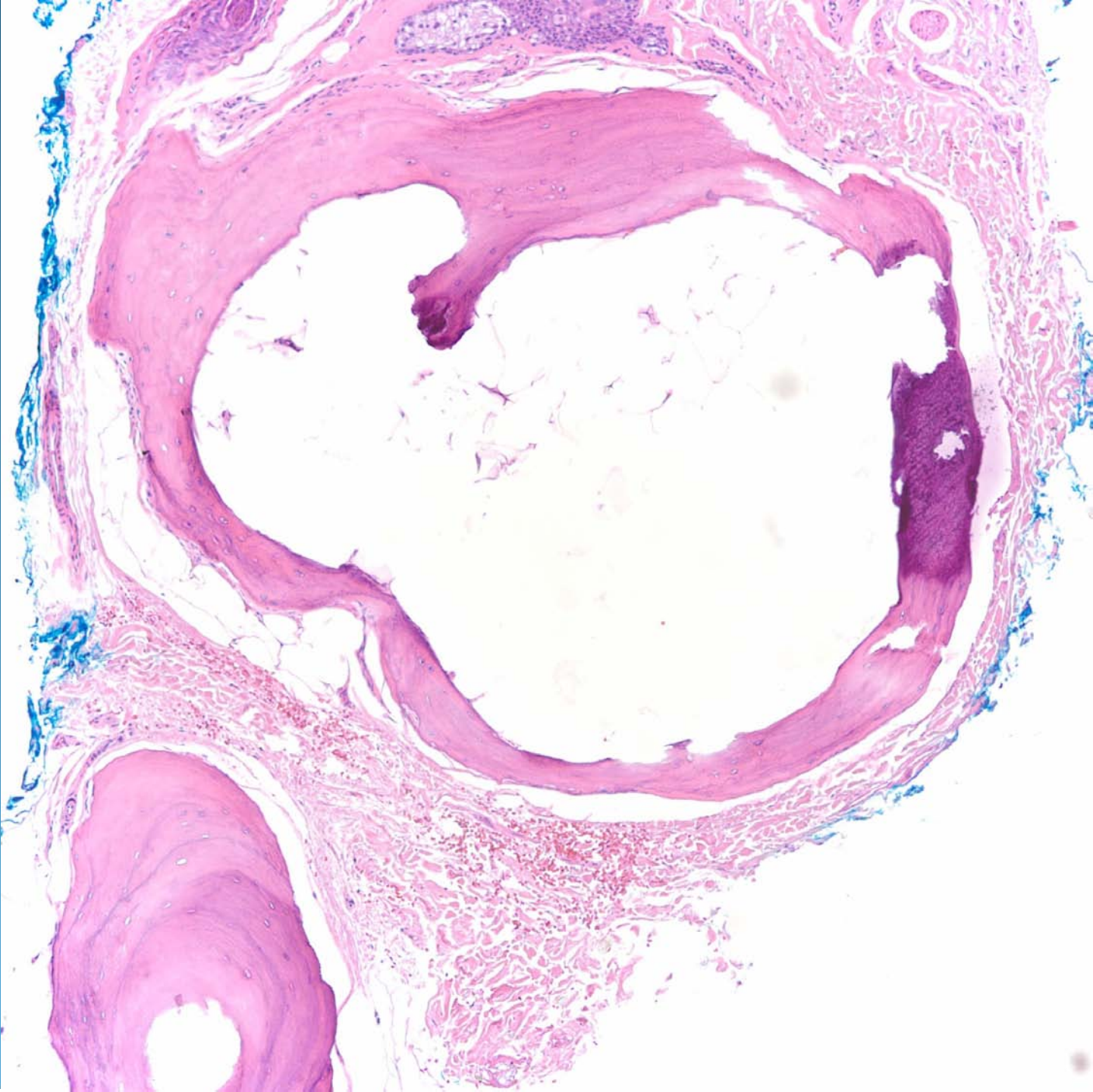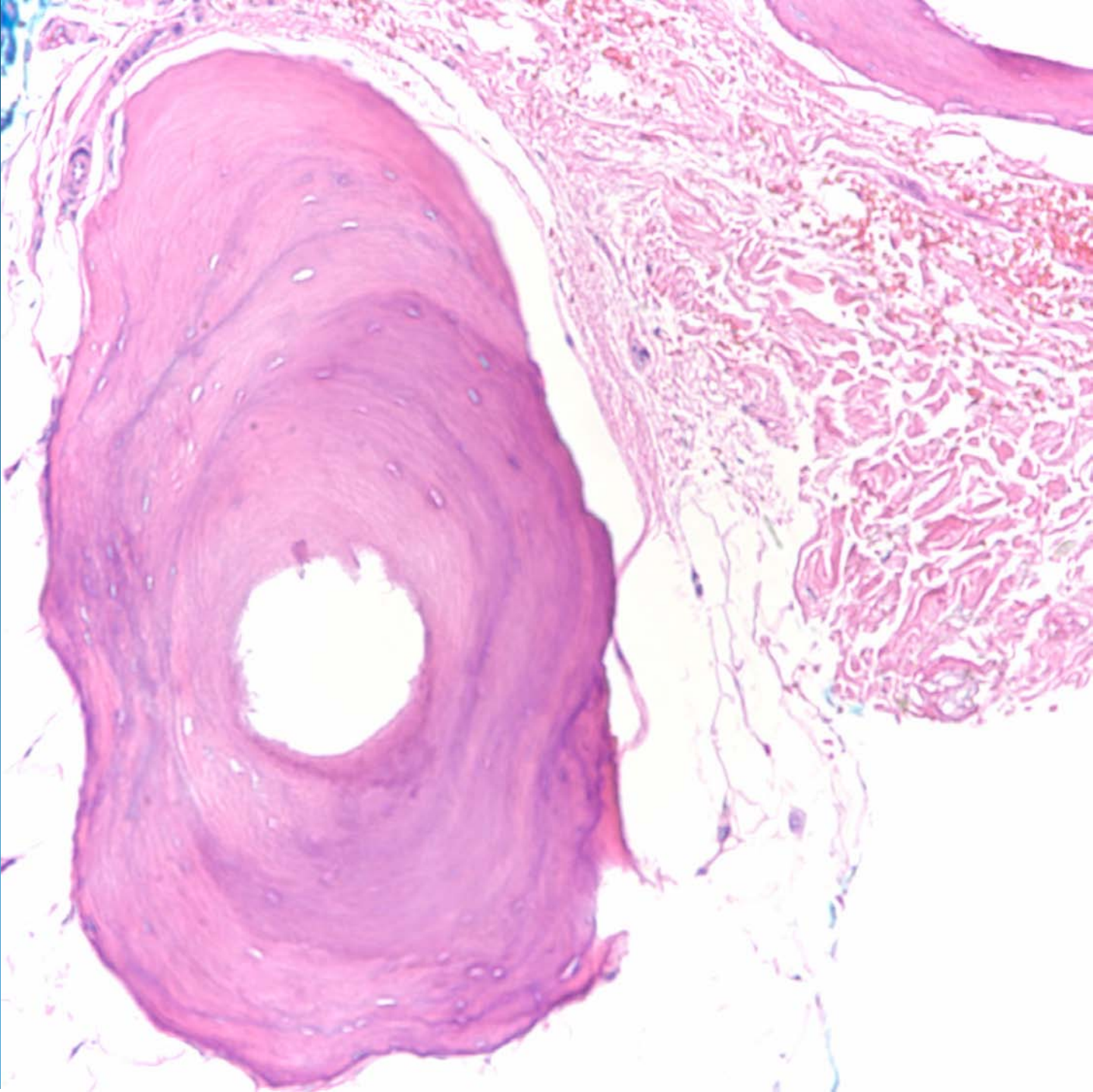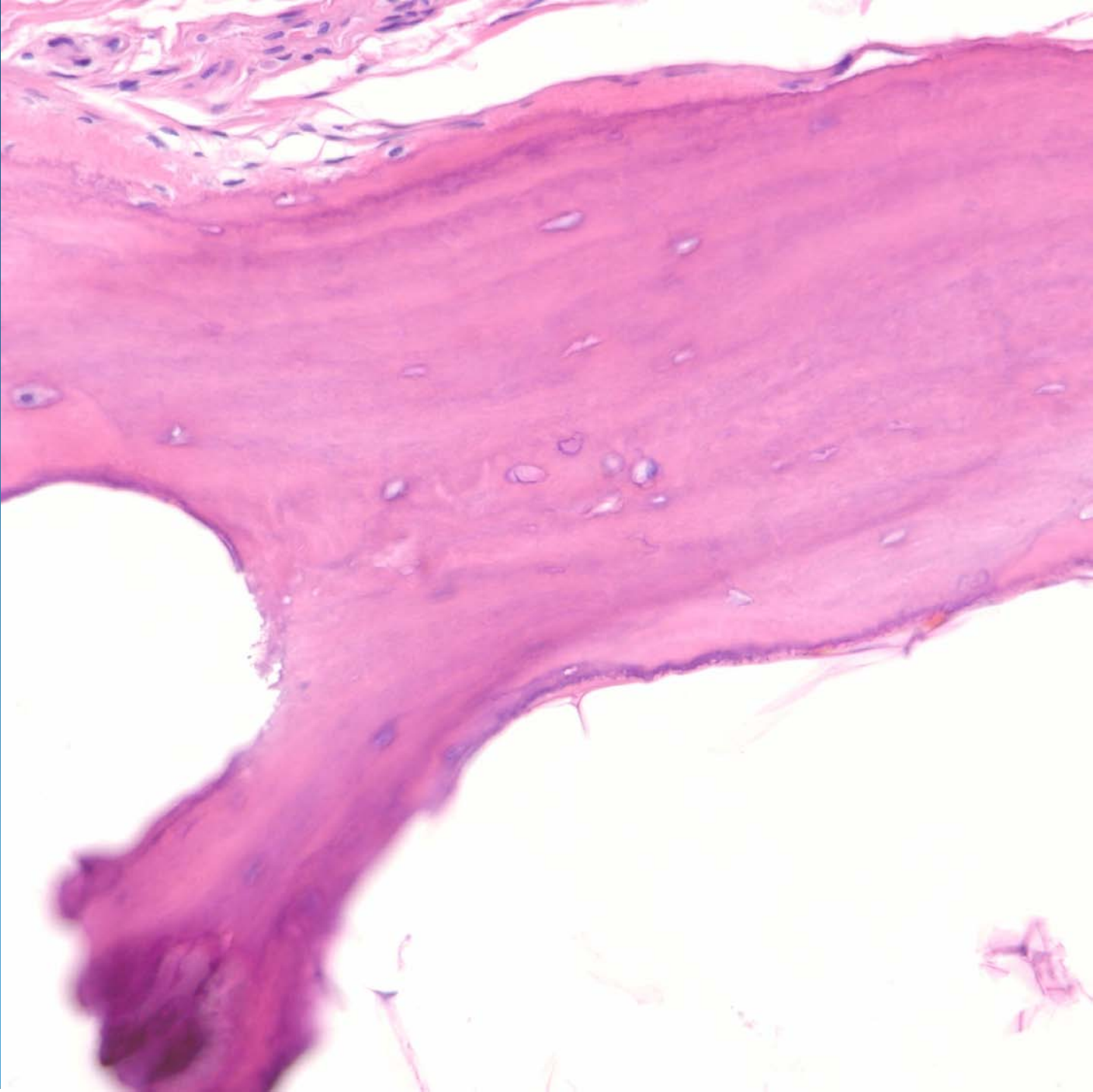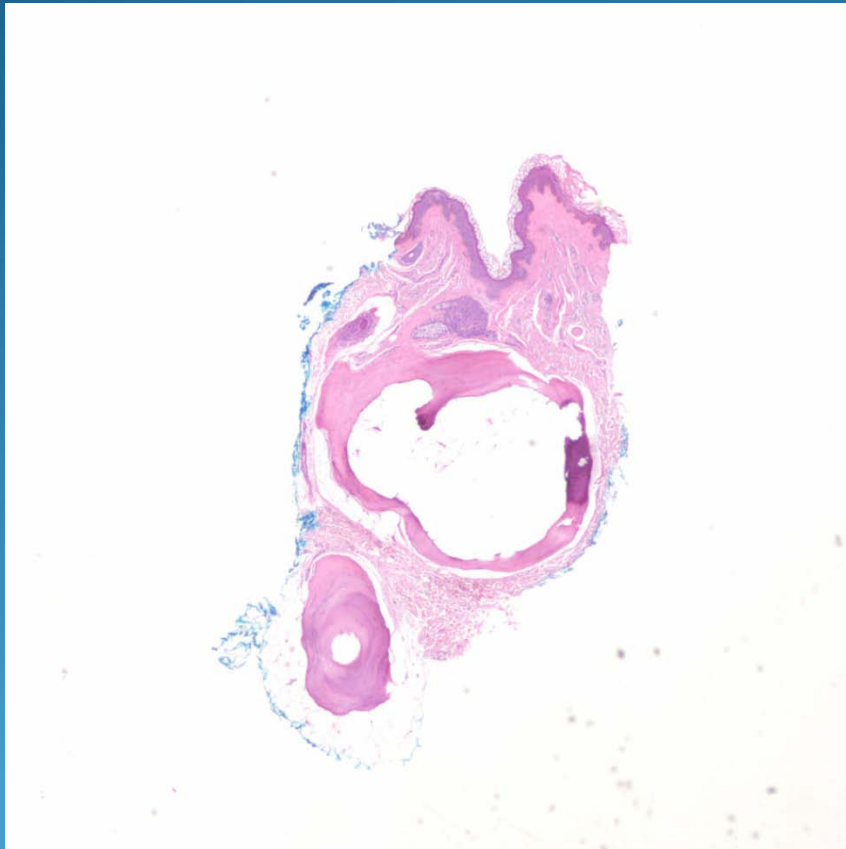


Osteoma Cutis

Pearls



- Mature lamellar bone in dermis
- No cytologic atypia of the osteocytes
- Variable inflammation and may have vascular changes