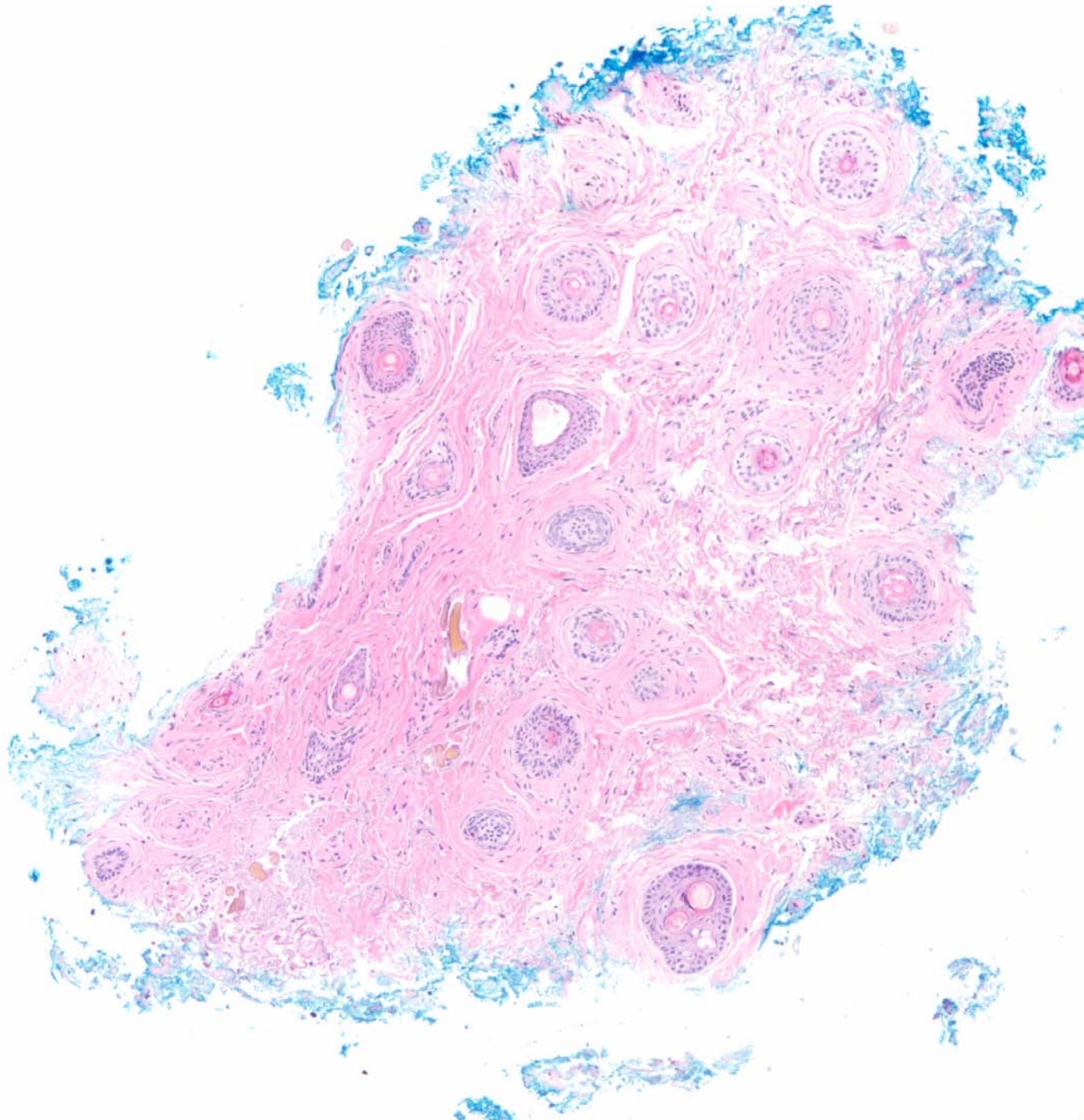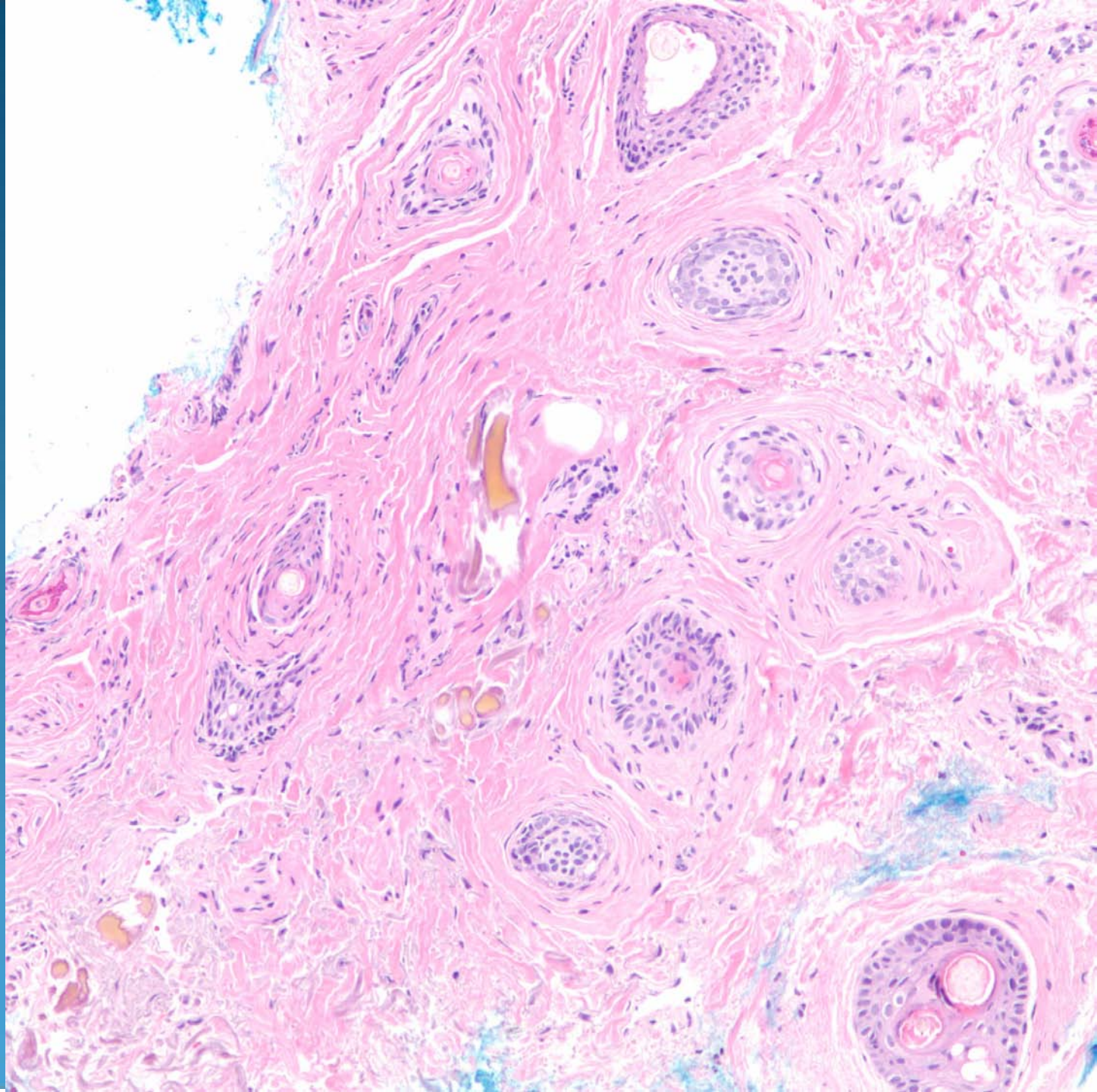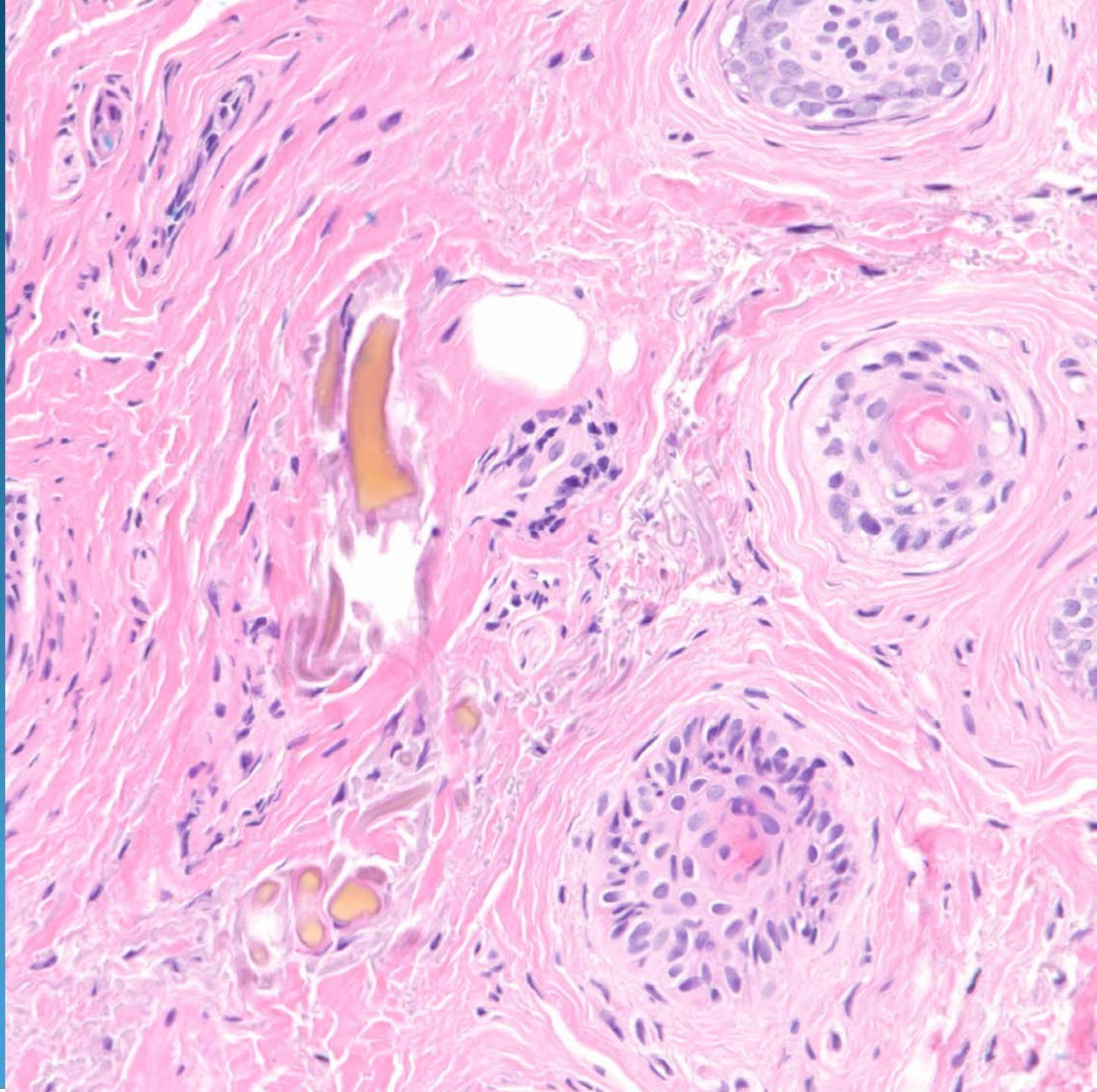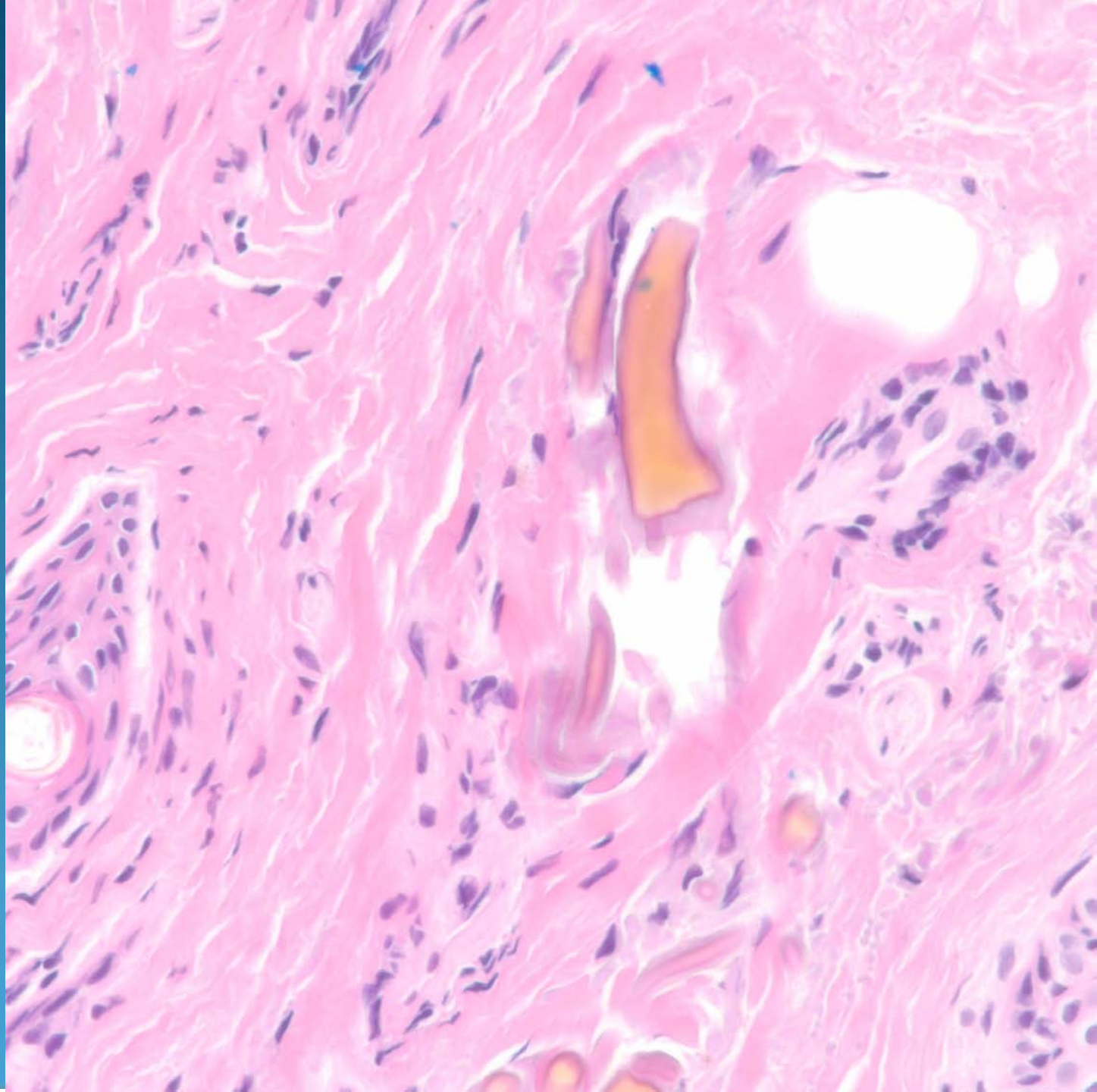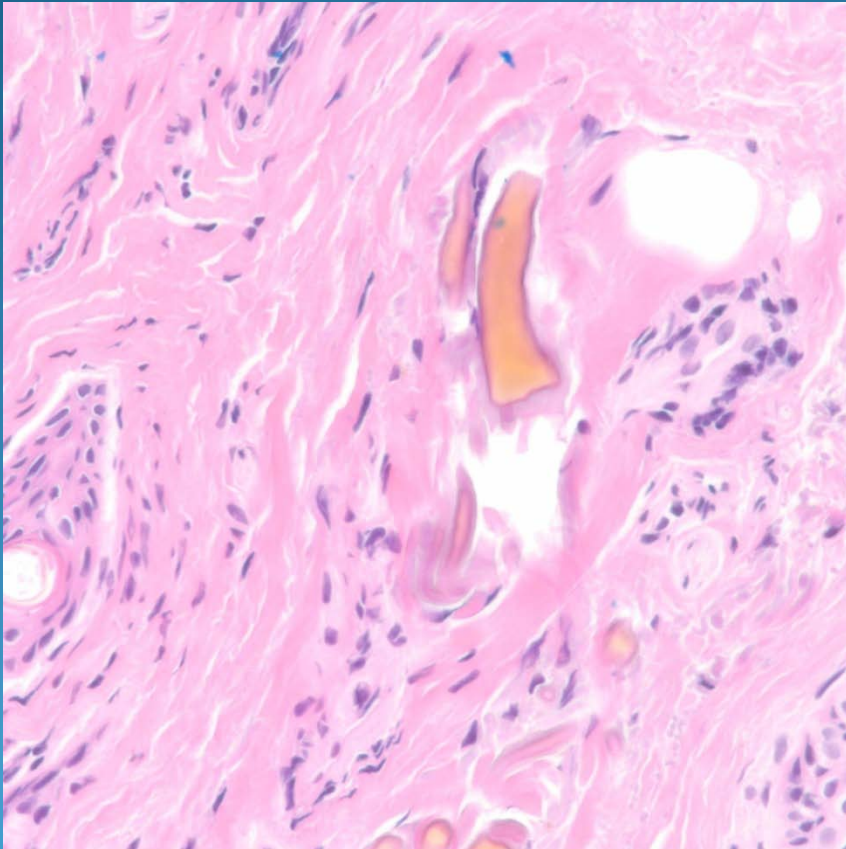


Ochronosis

Pearls



- Yellow brown “banana” structures with minimal inflammatory cell infiltrate
- Primary and secondary cases histologically identical
- Clinical correlation