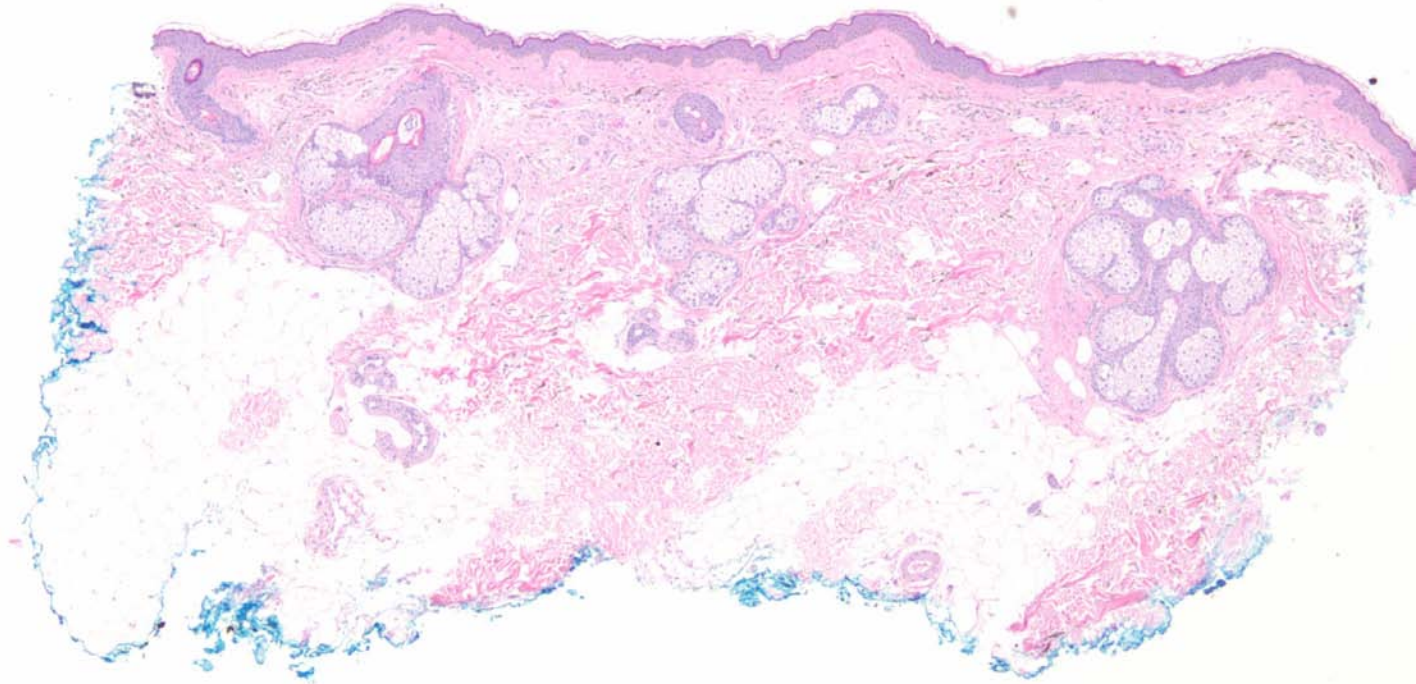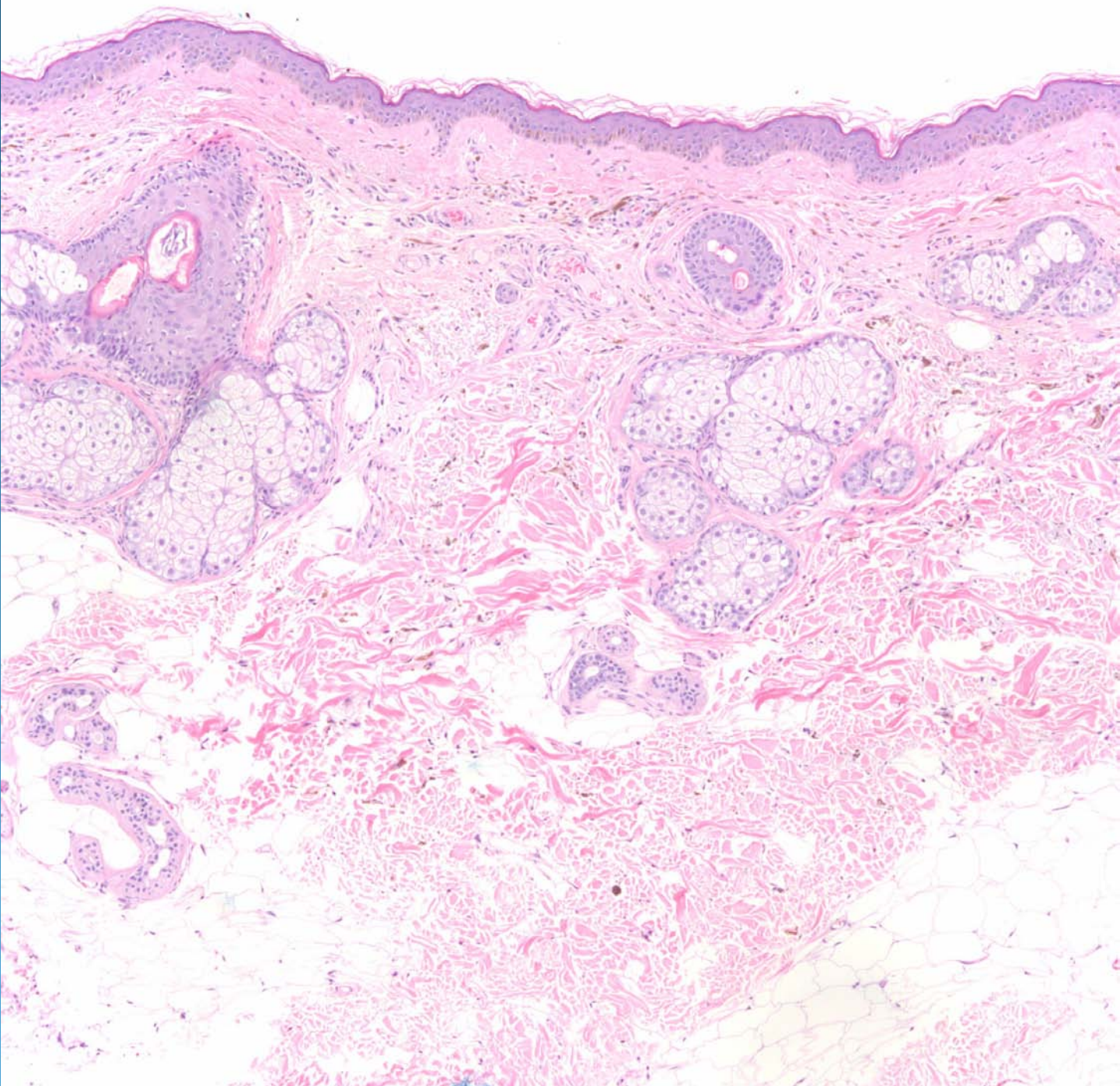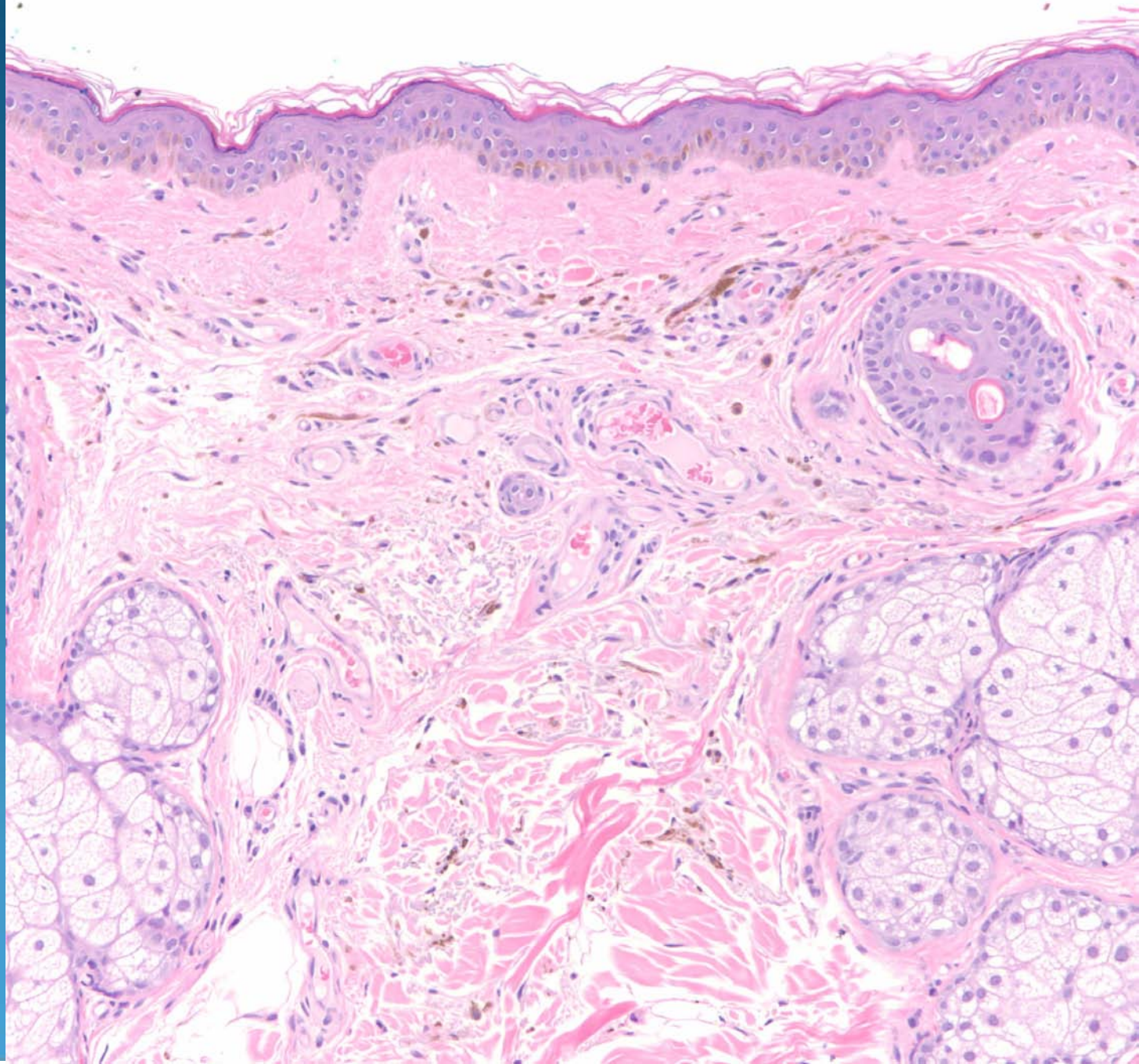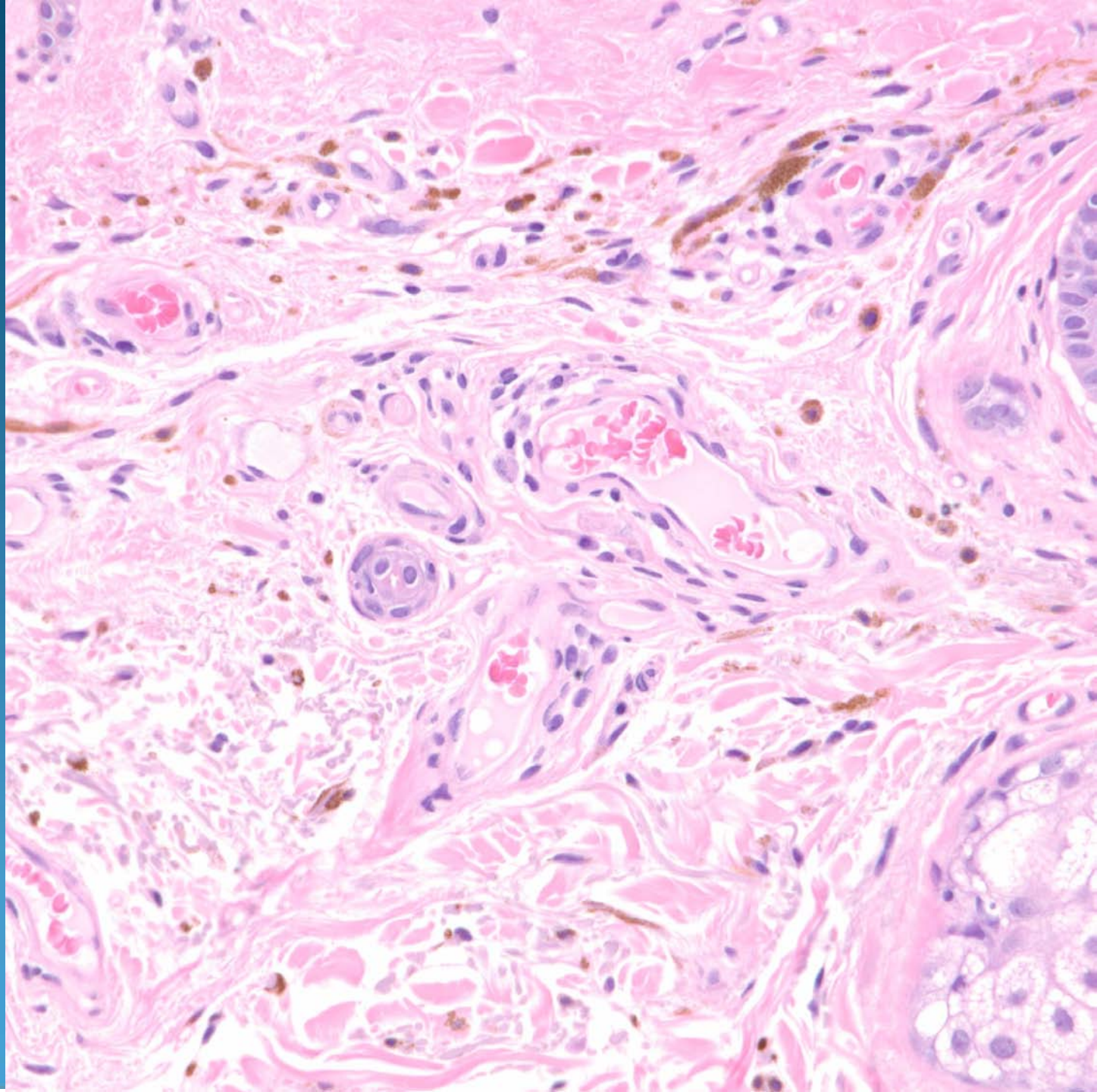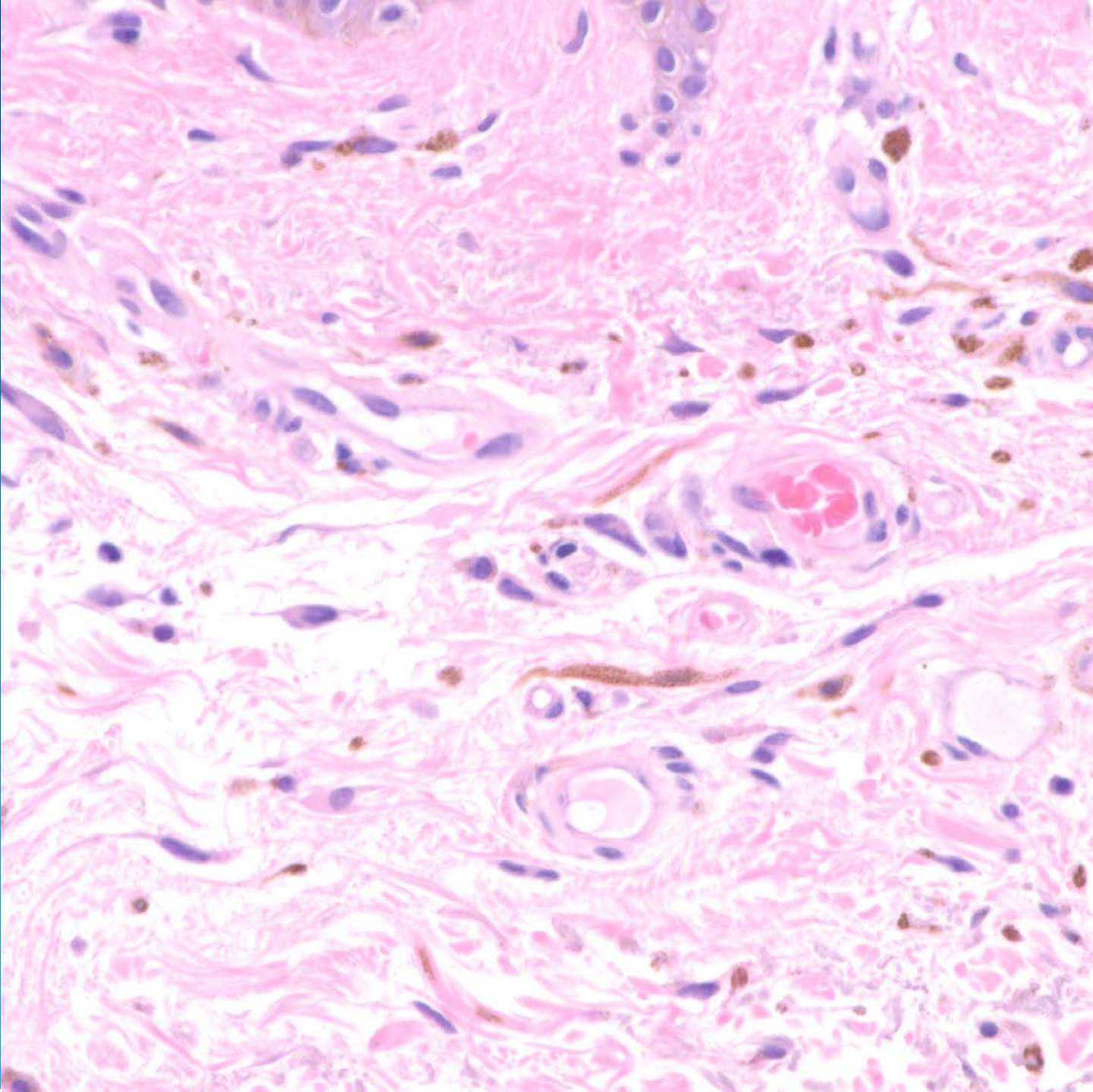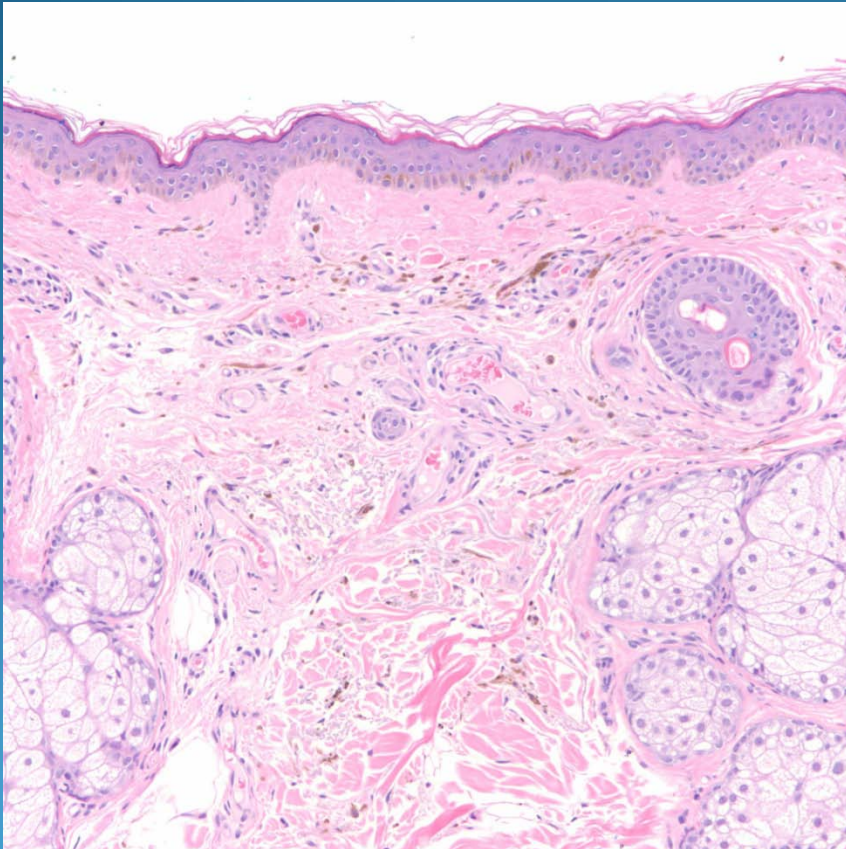


# Nevus of Ota

# Pearls



- Note location of biopsy both clinical and histopathology
- Pigmented dendritic melanocytes, usually sparser than blue nevus
- DDX: Blue nevus, Mongolian spot, Nevus of Ito, tattoo