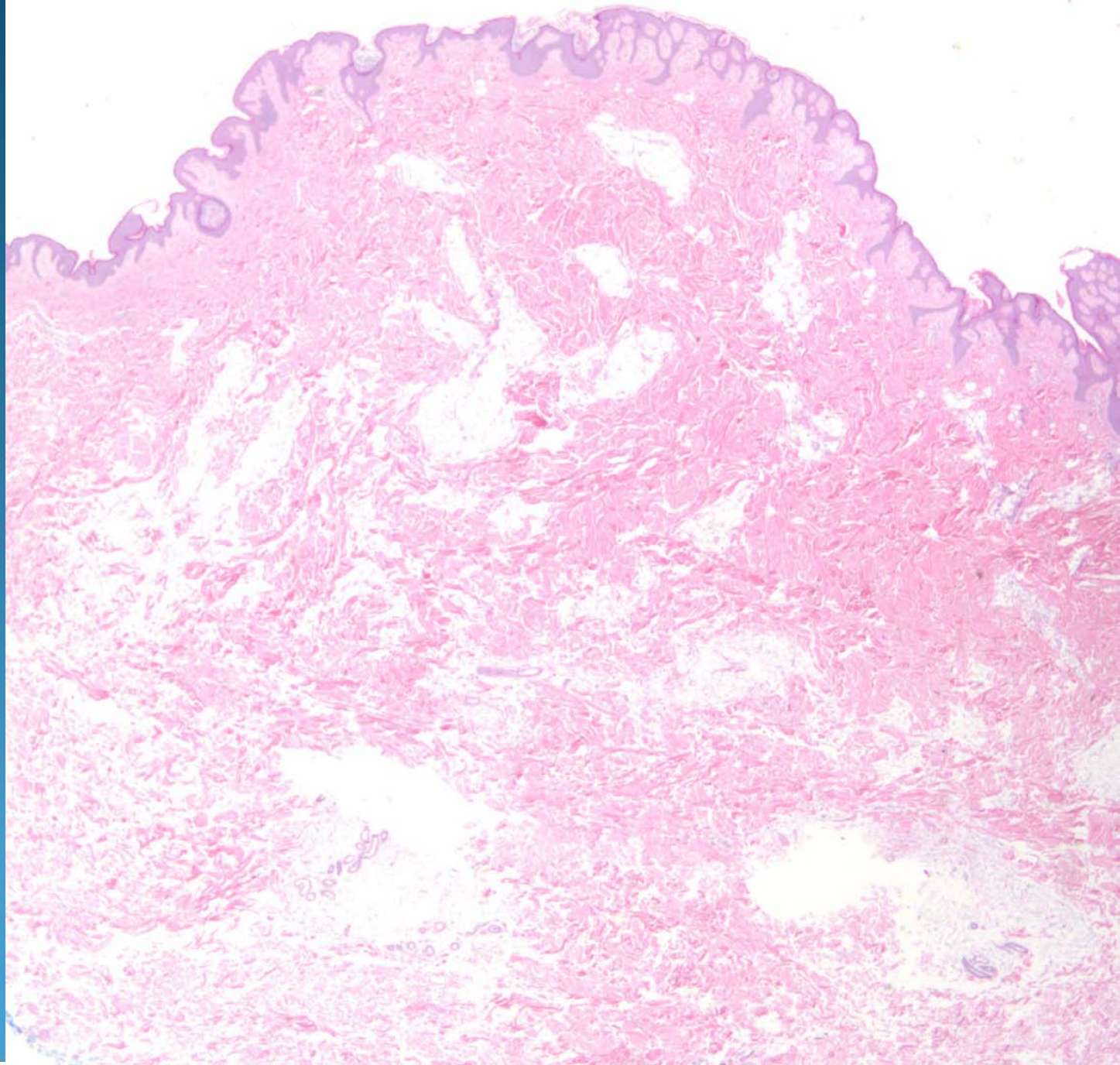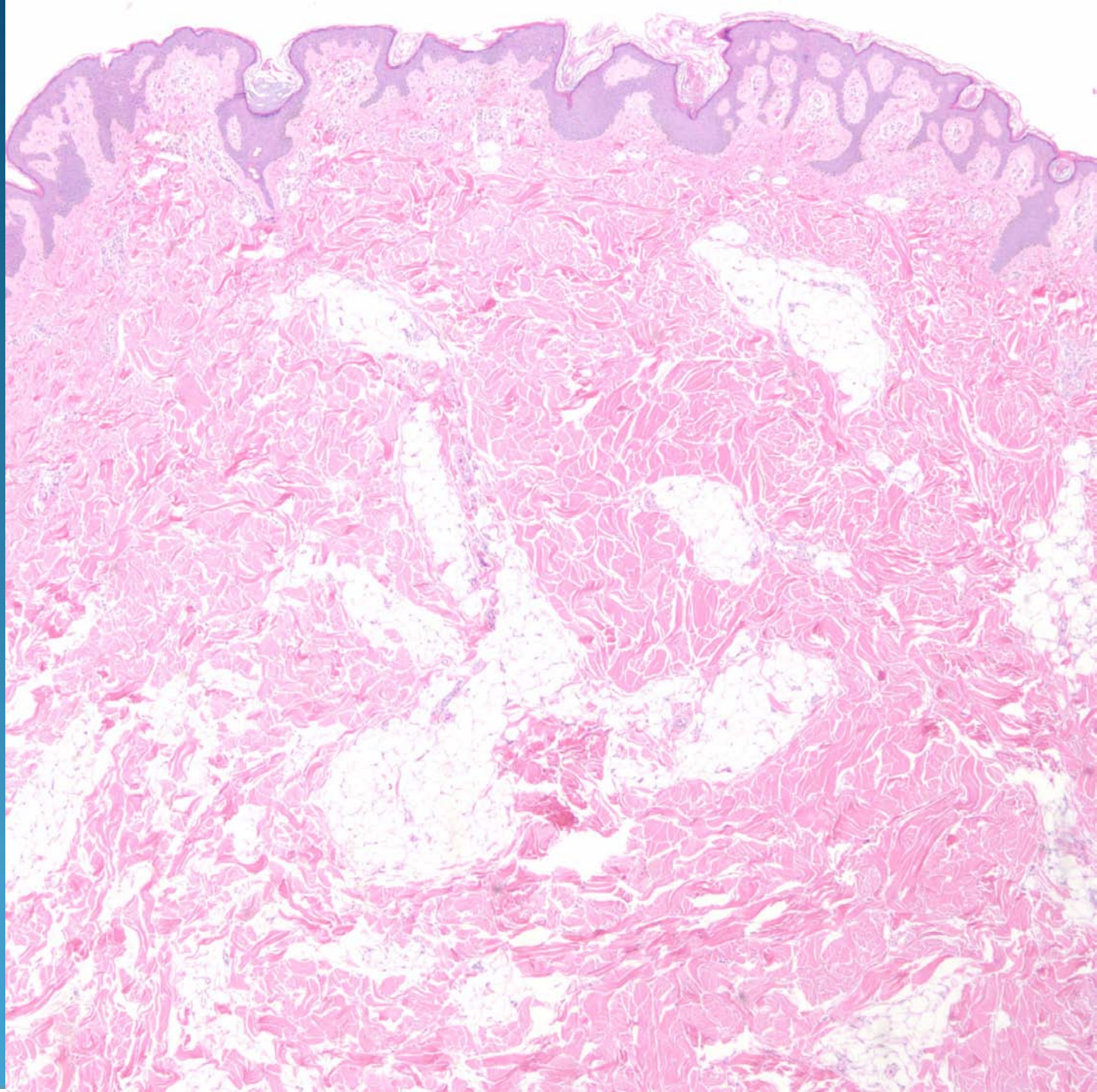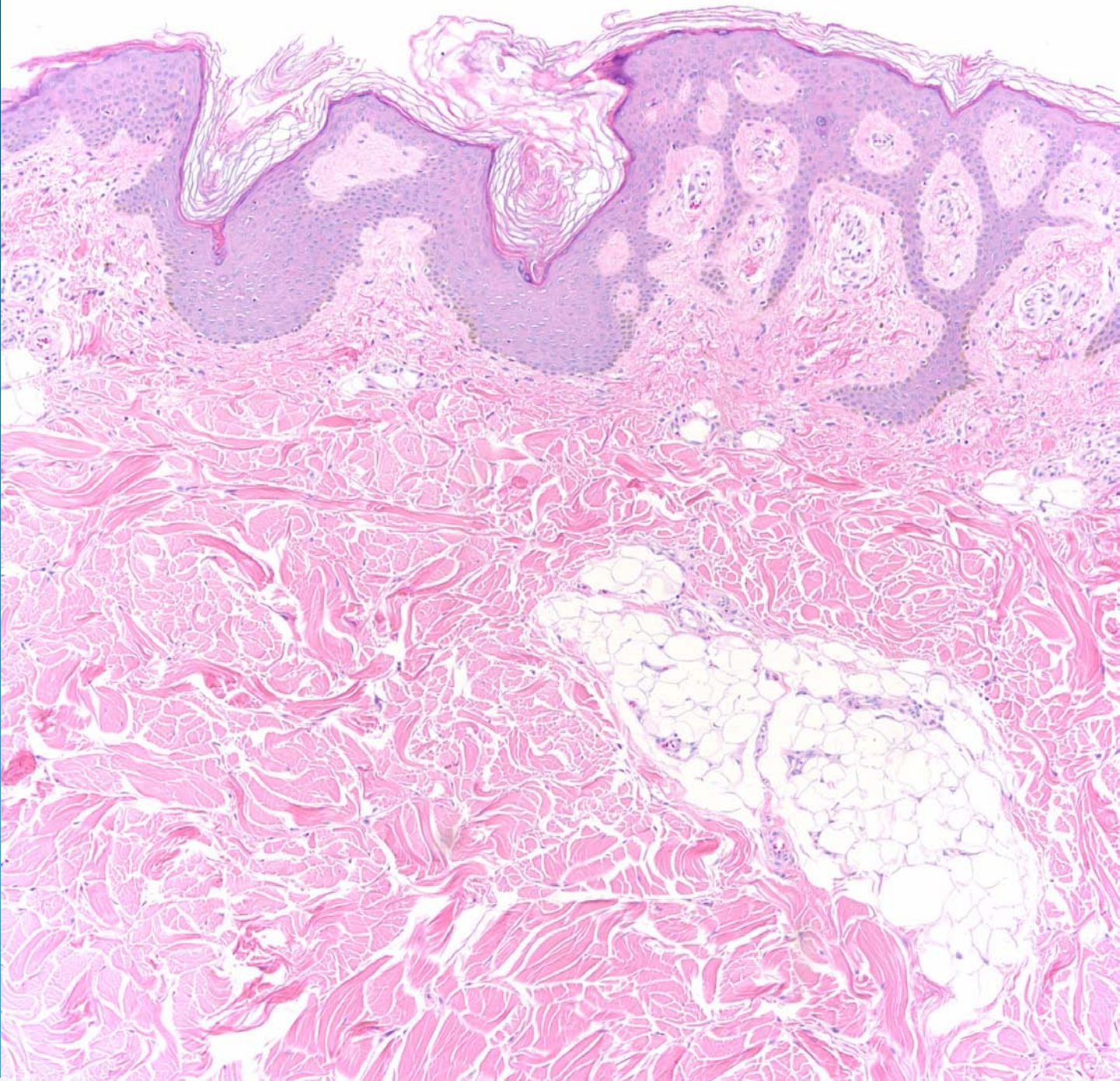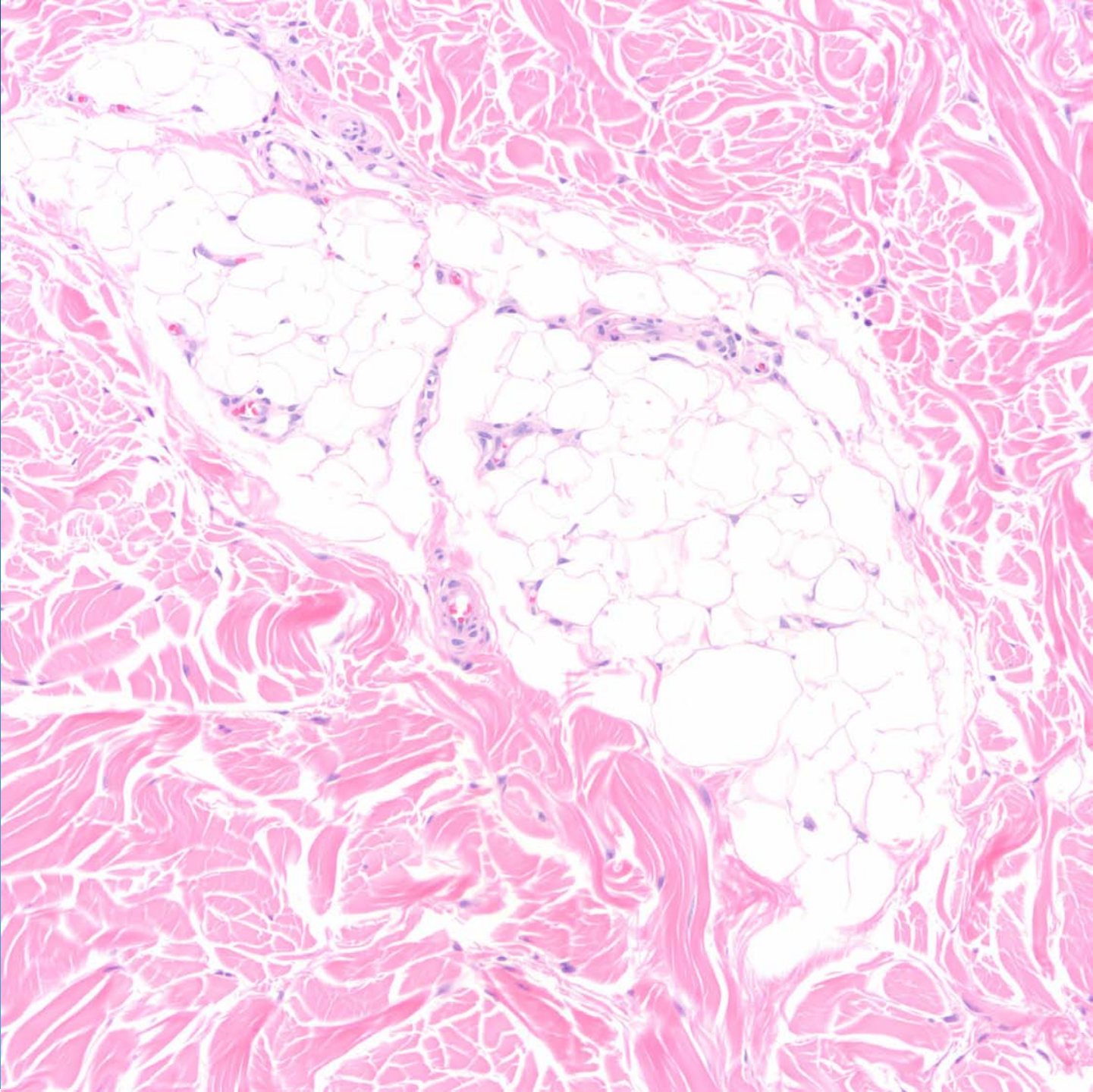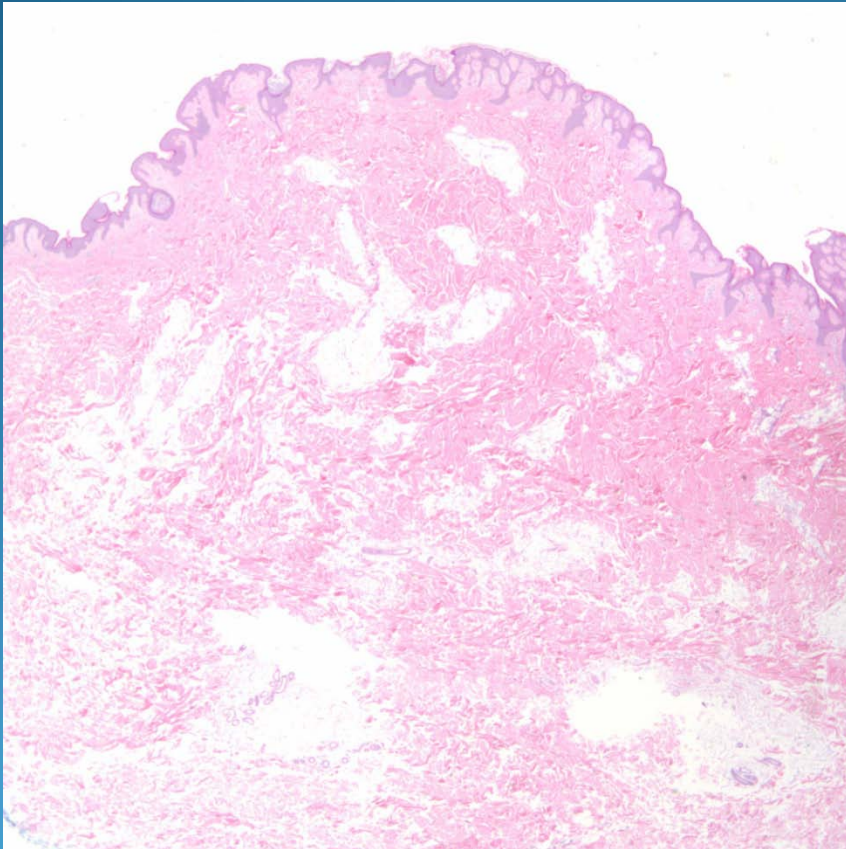


Nevus lipomatosus

Pearls



- Nodular collection of mature adipose tissue extending into papillary dermis
- Overlying epidermis with variable hyperplasia and papillomatosis