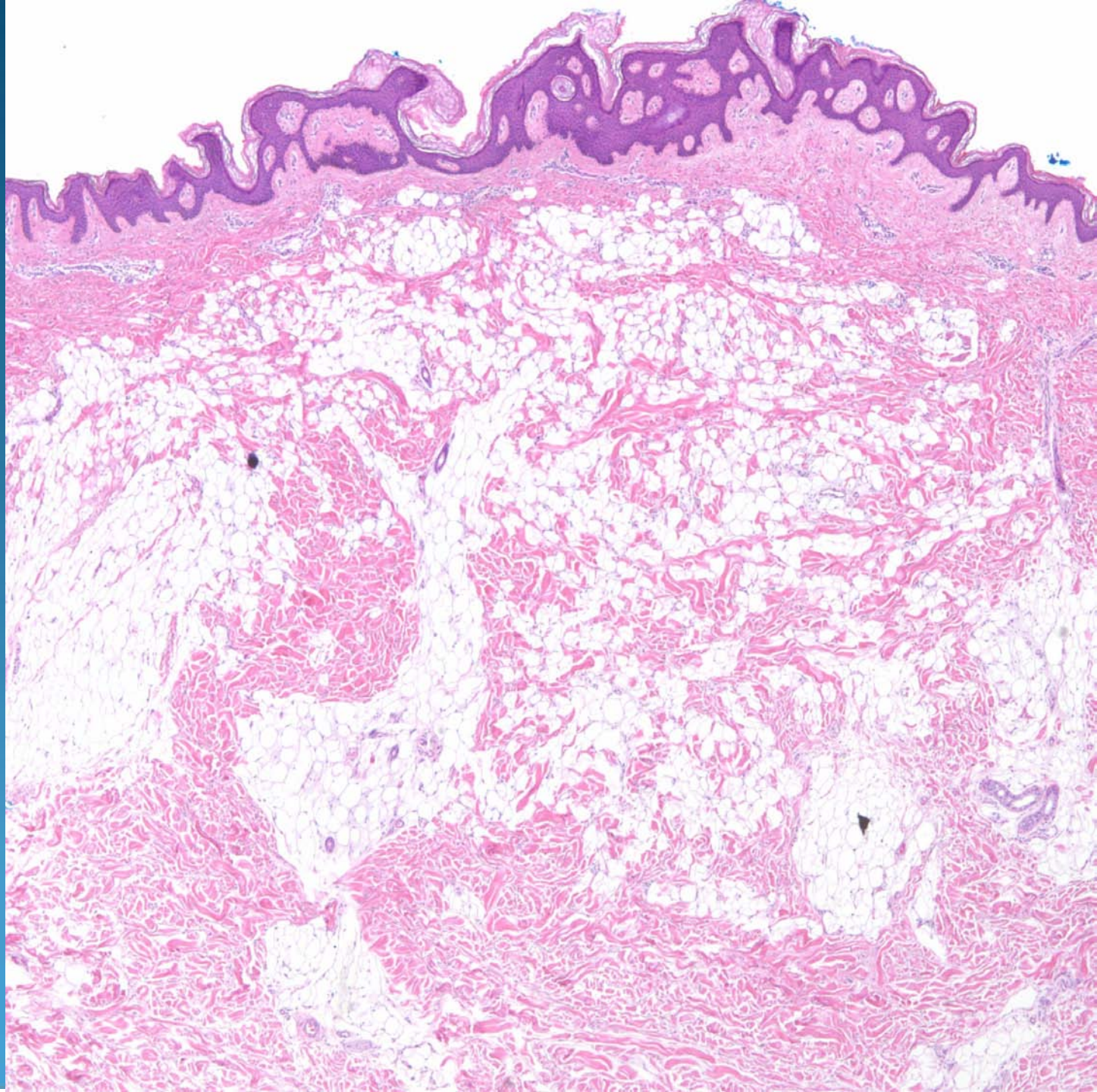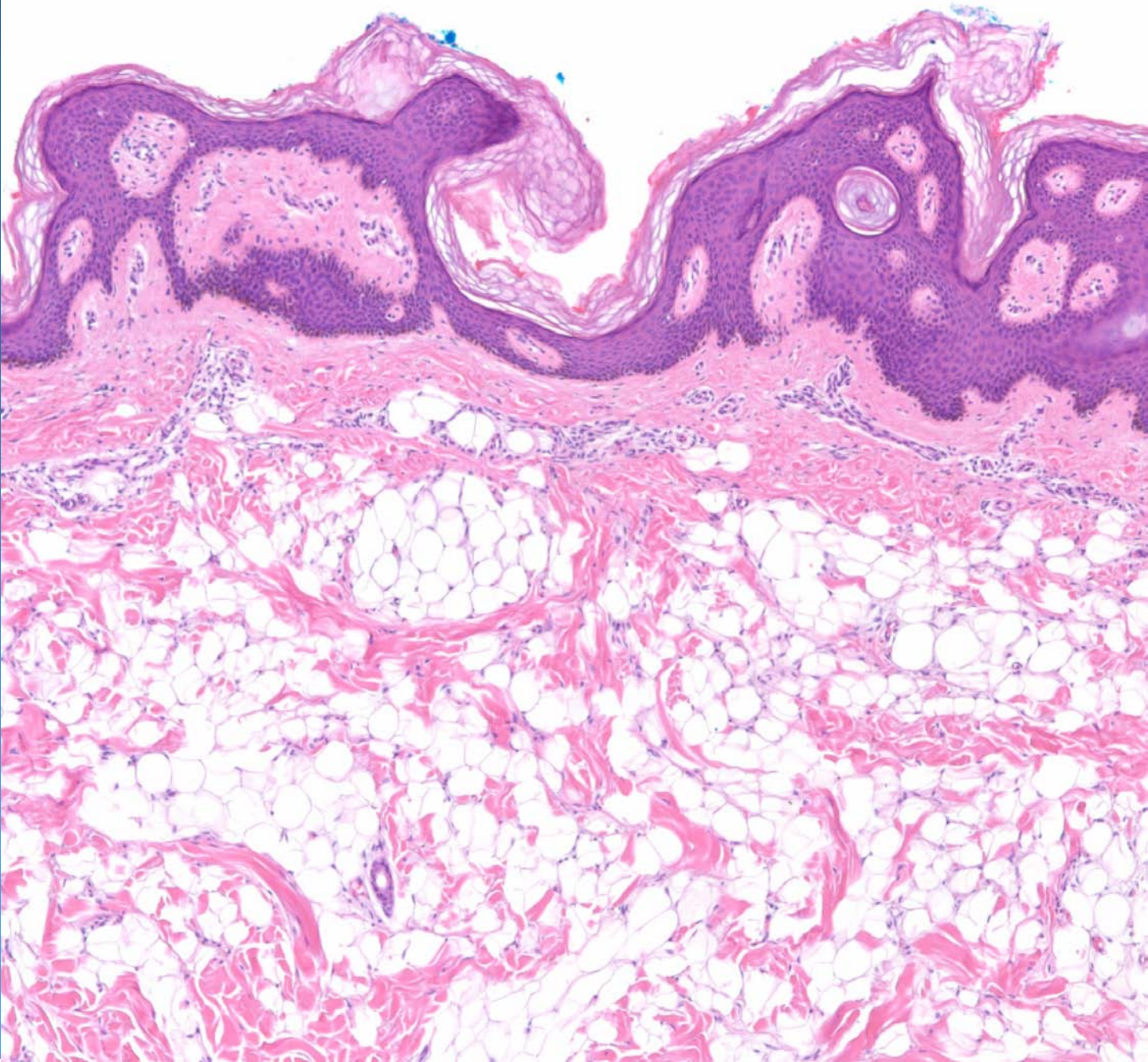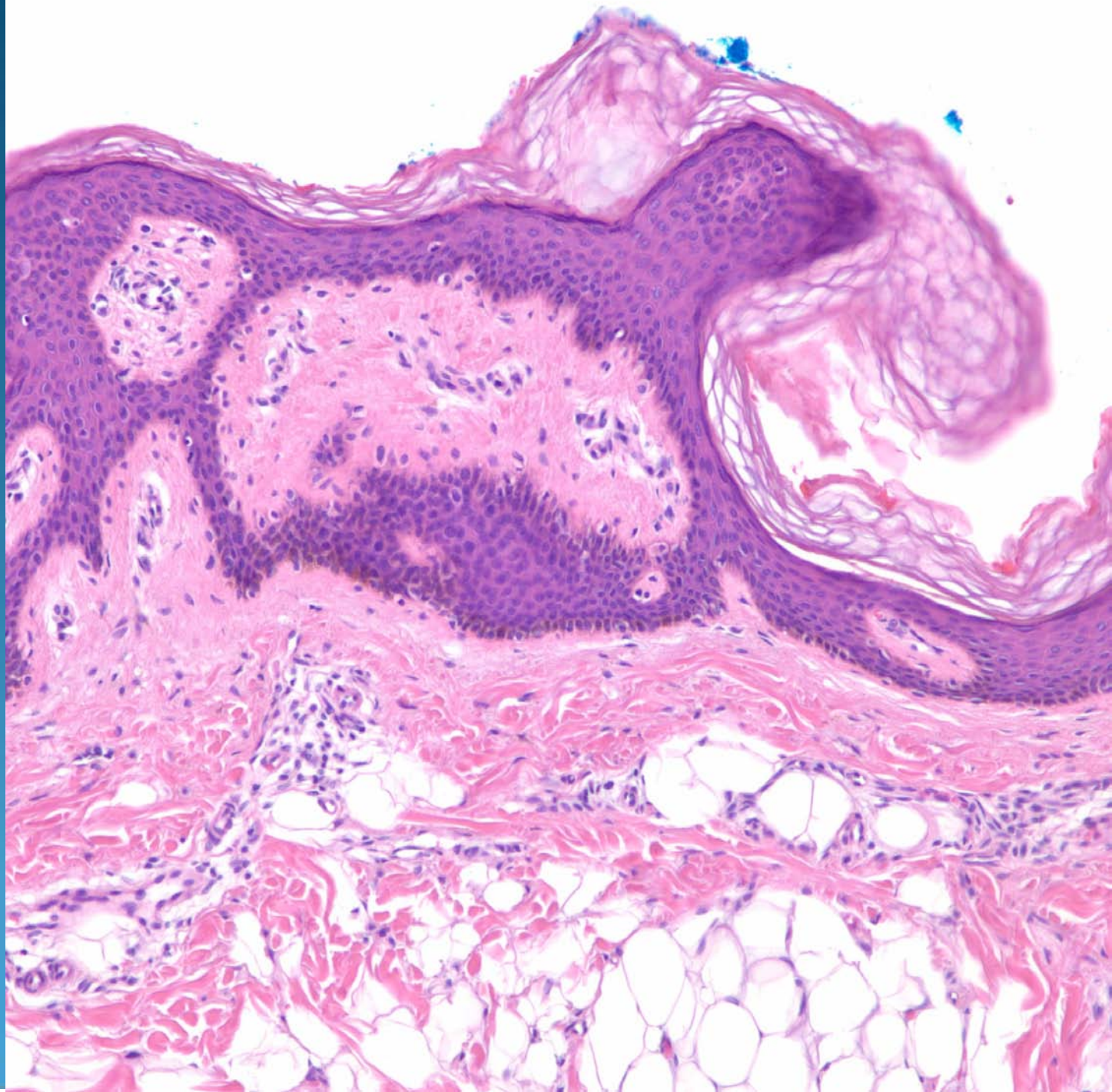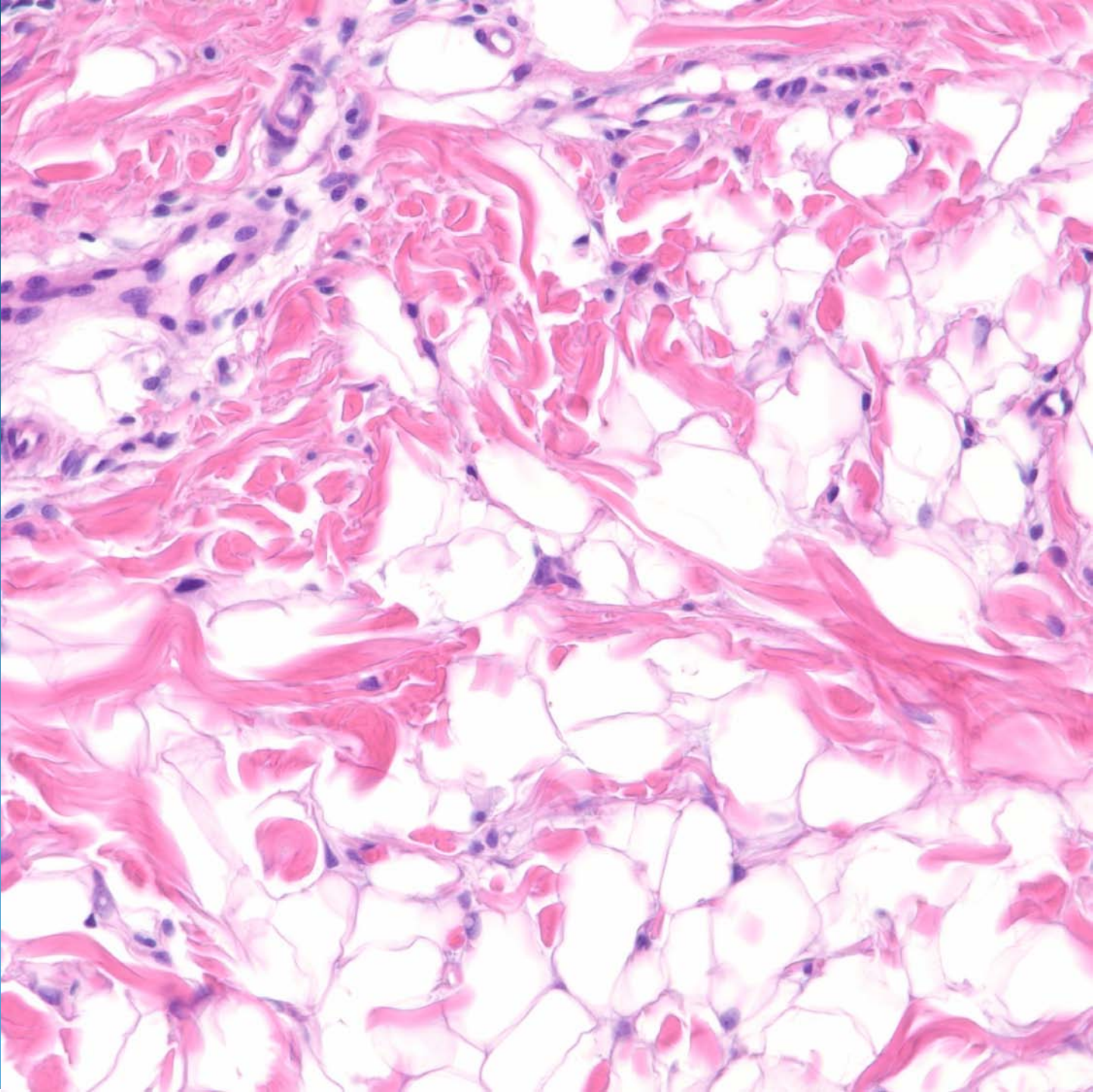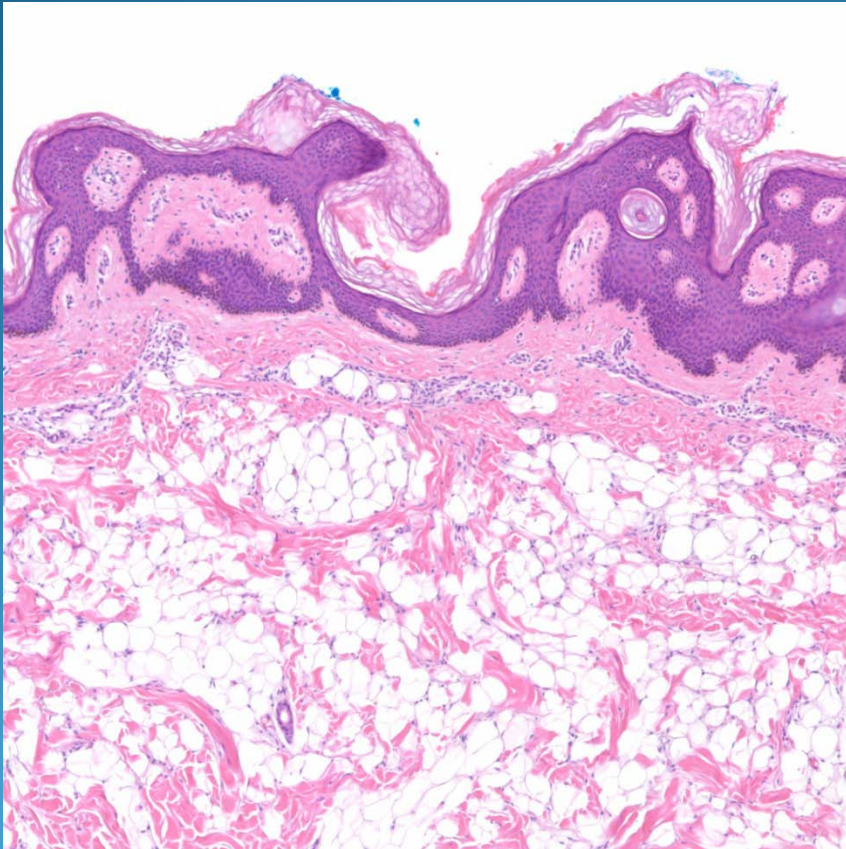


Nevus Lipomatosis

Pearls



- Epidermal hyperplasia with papillomatosis
- Mature adipose tissue extending into papillary dermis