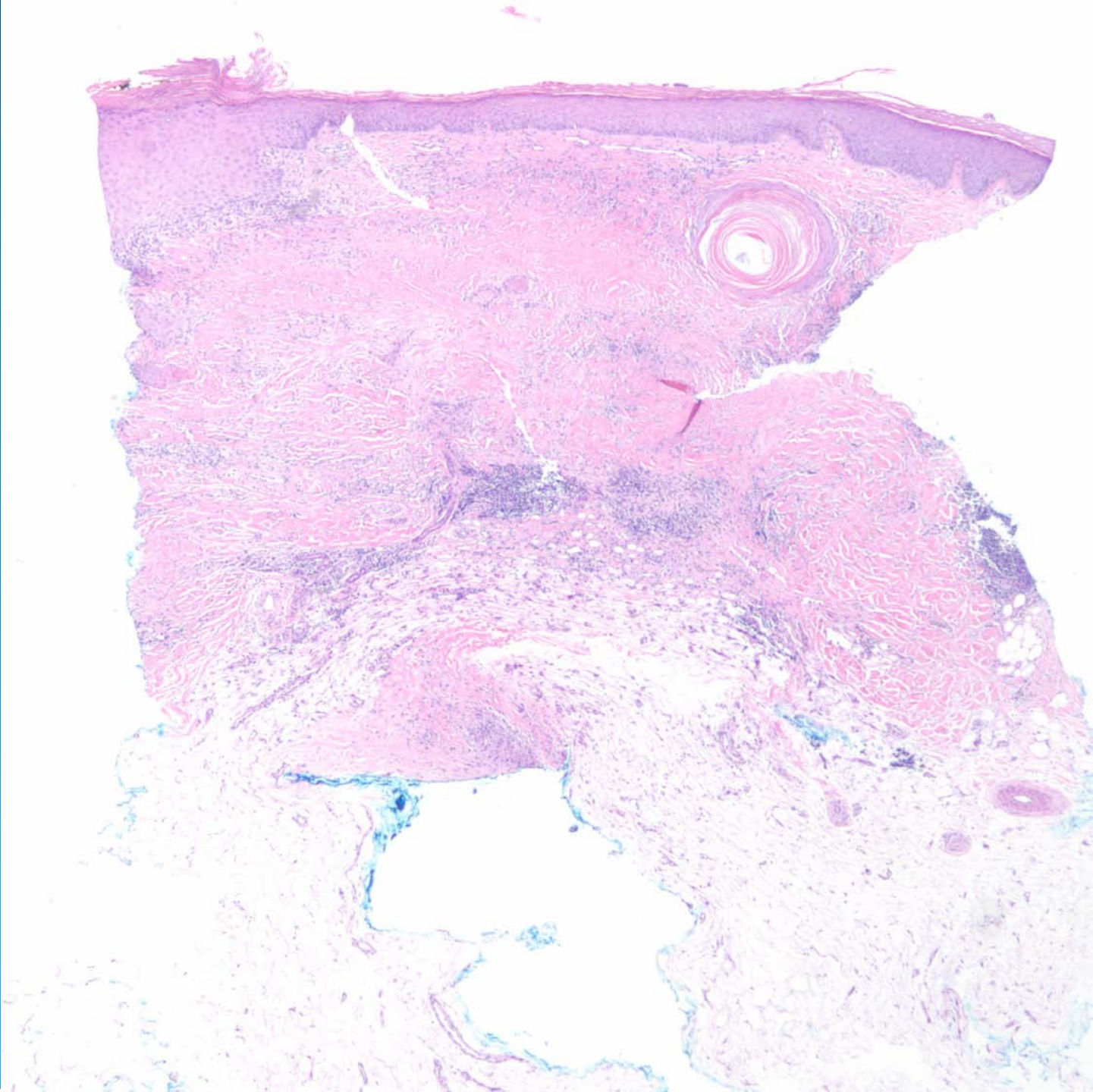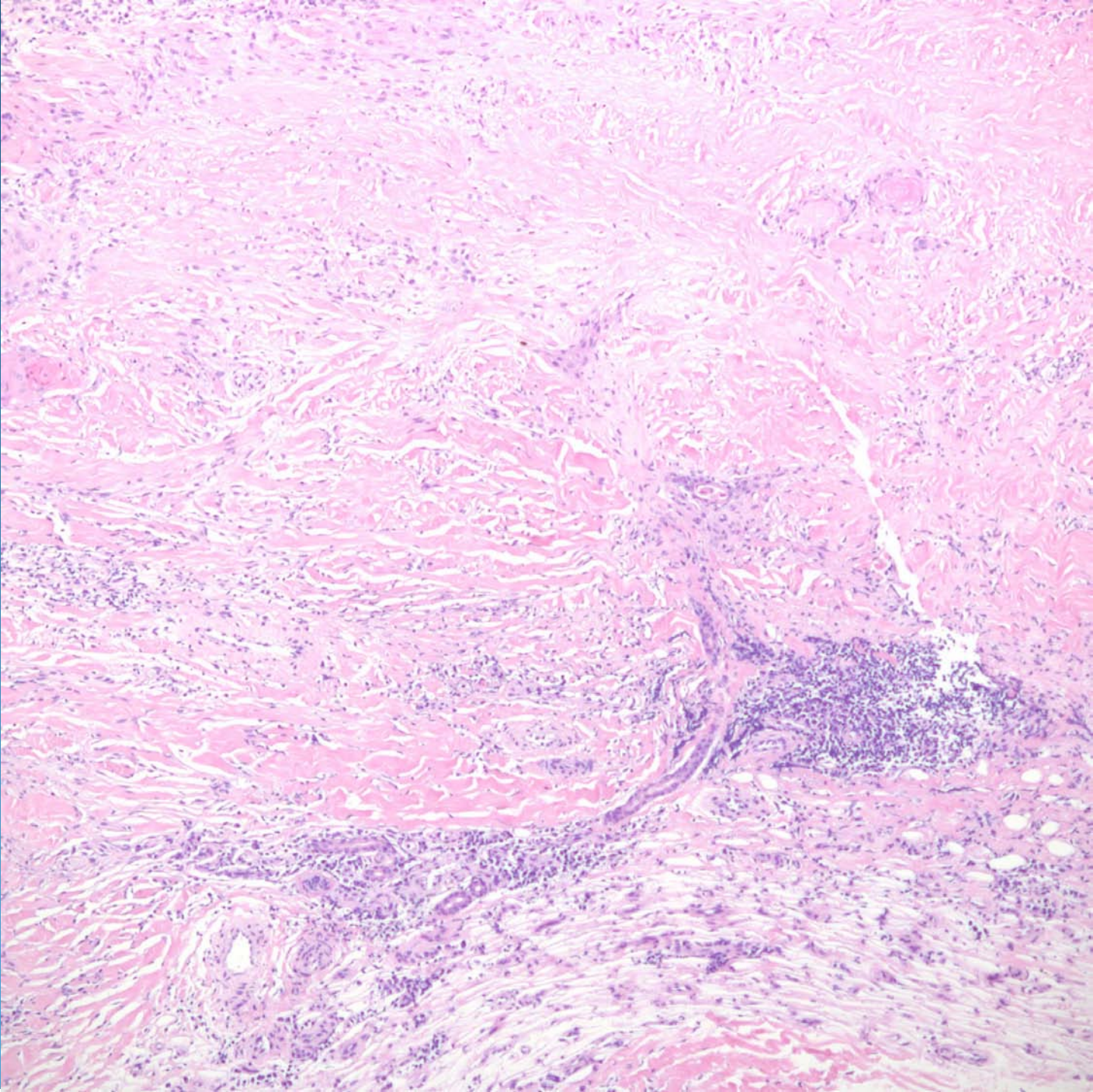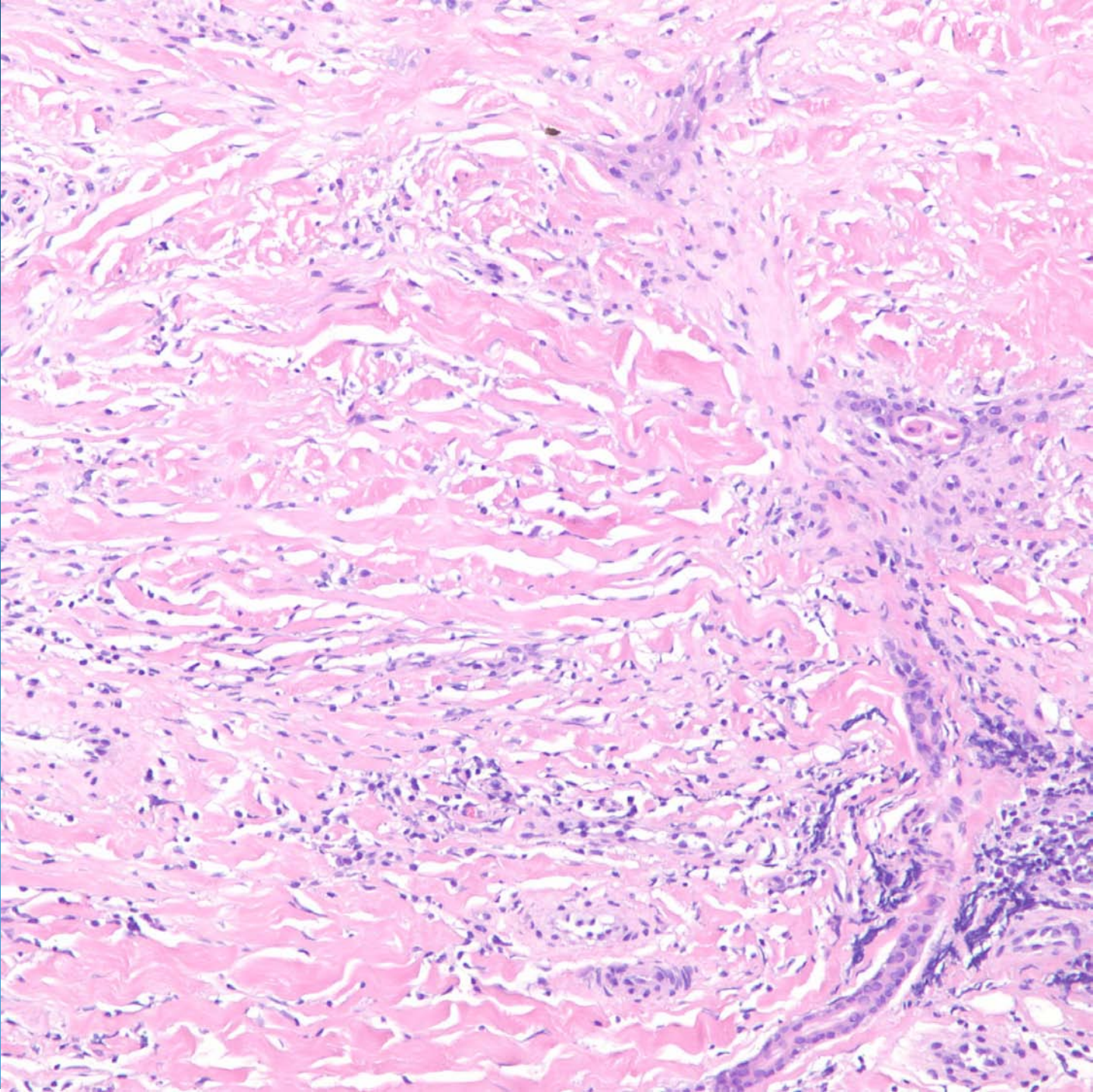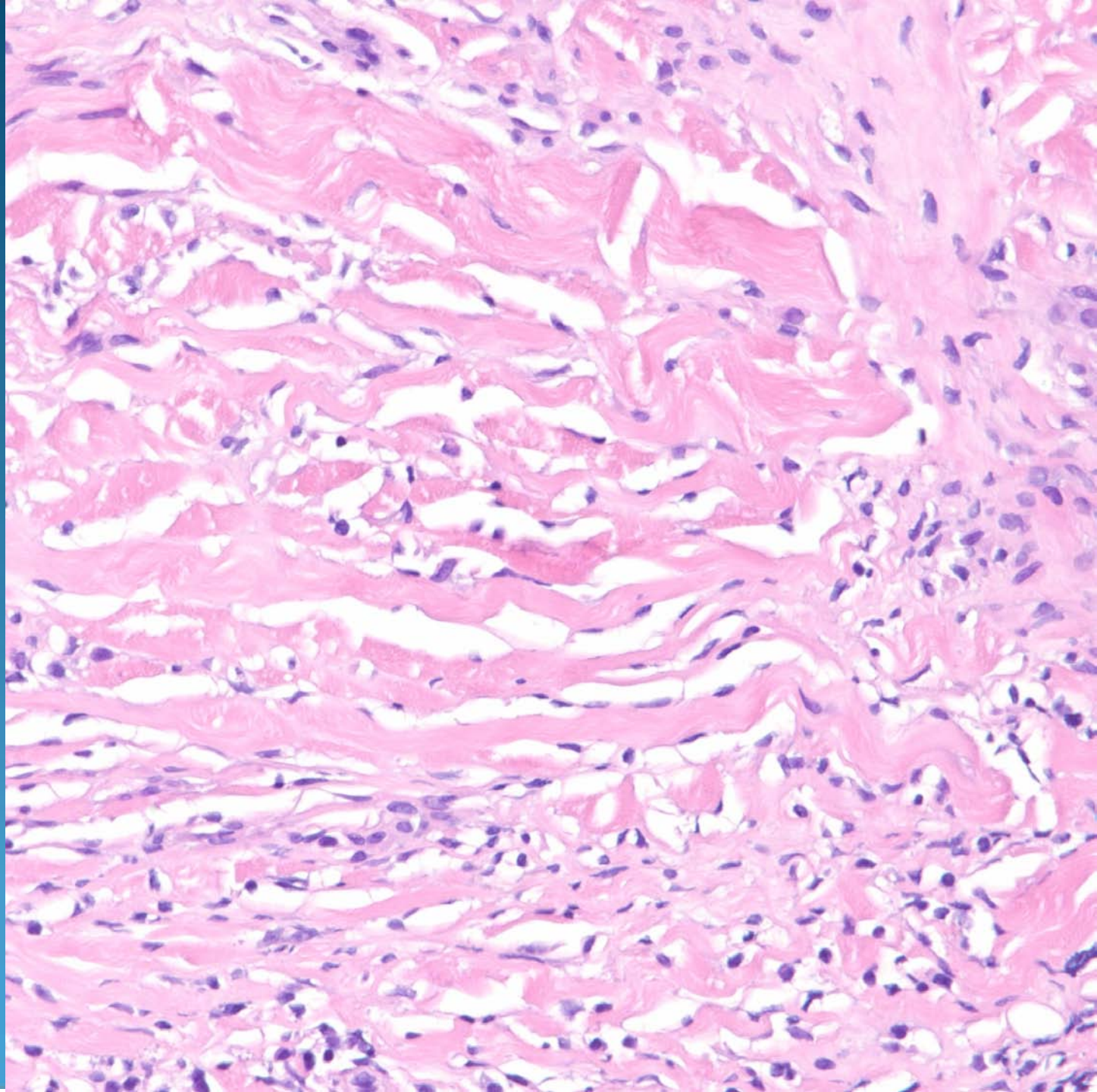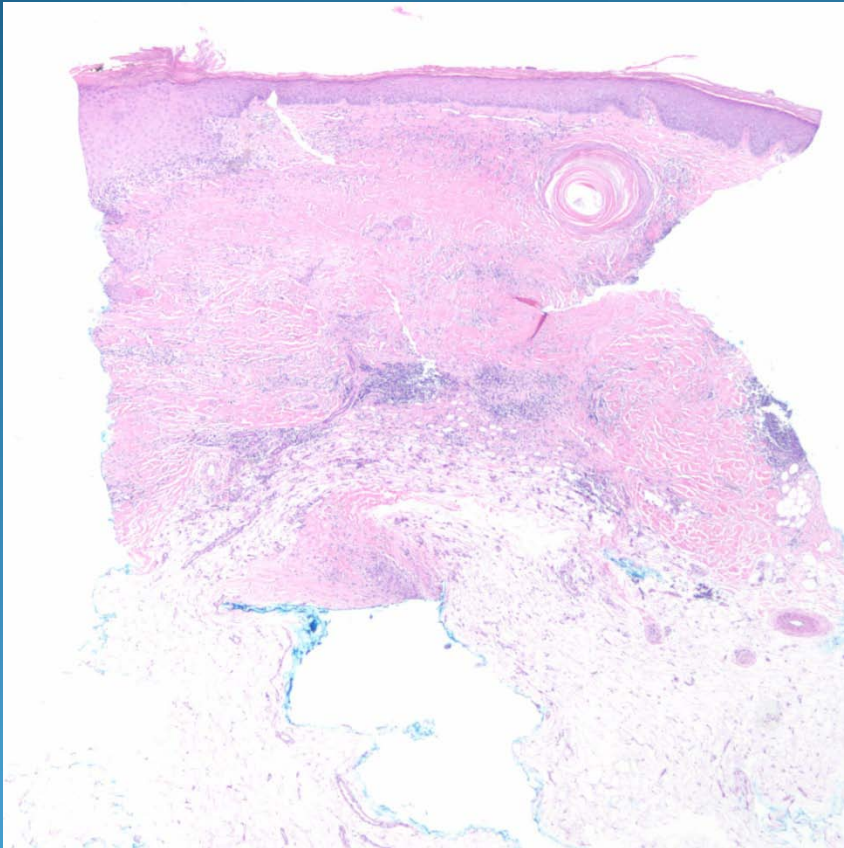


Necrobiosis lipoidica

Pearls



- Palisading necrobiosis in stair-case like extension to deep reticular dermis
- Mixed chronic inflammatory infiltrate with plasma cells
- DDX: Granuloma annulare