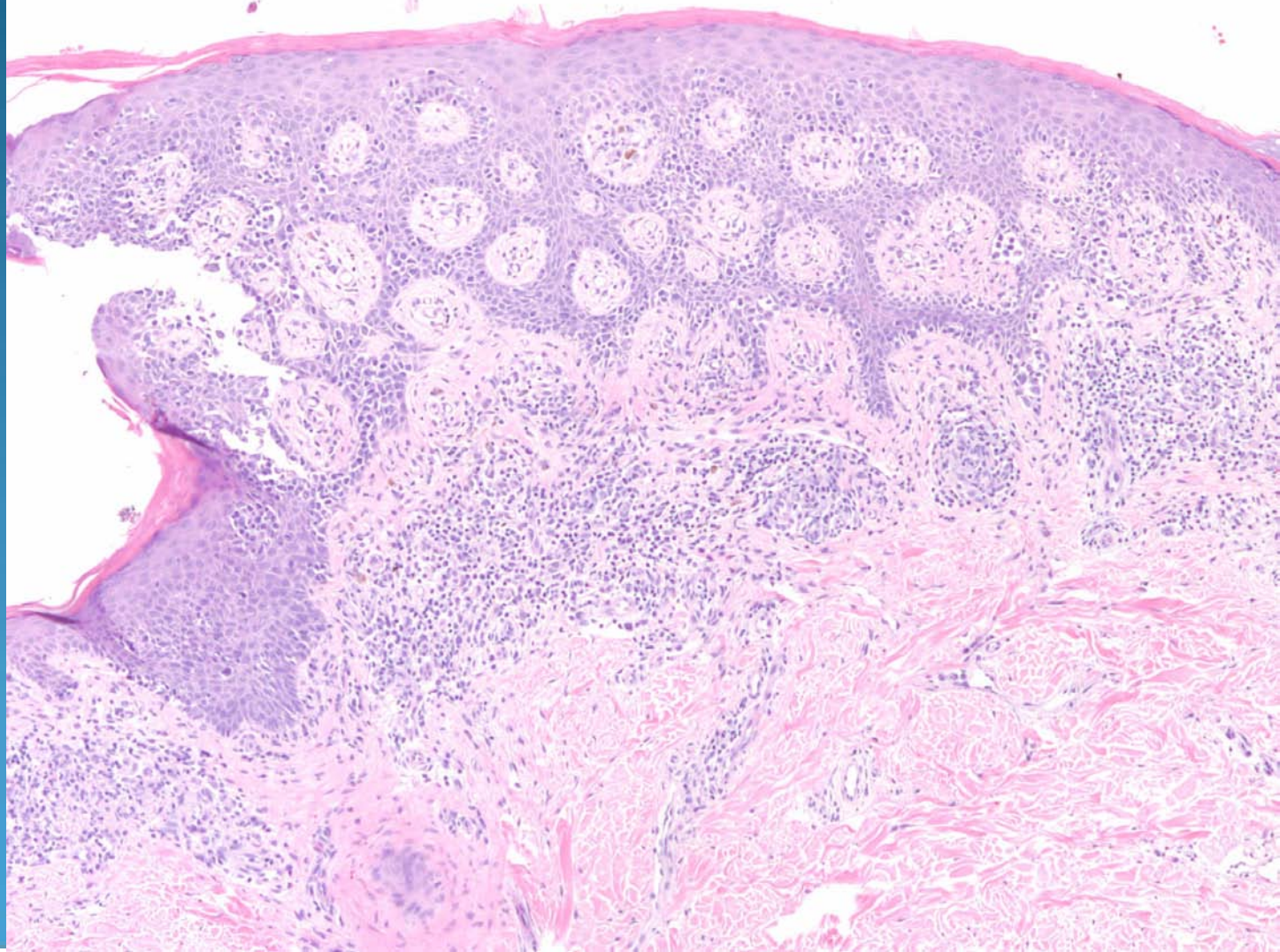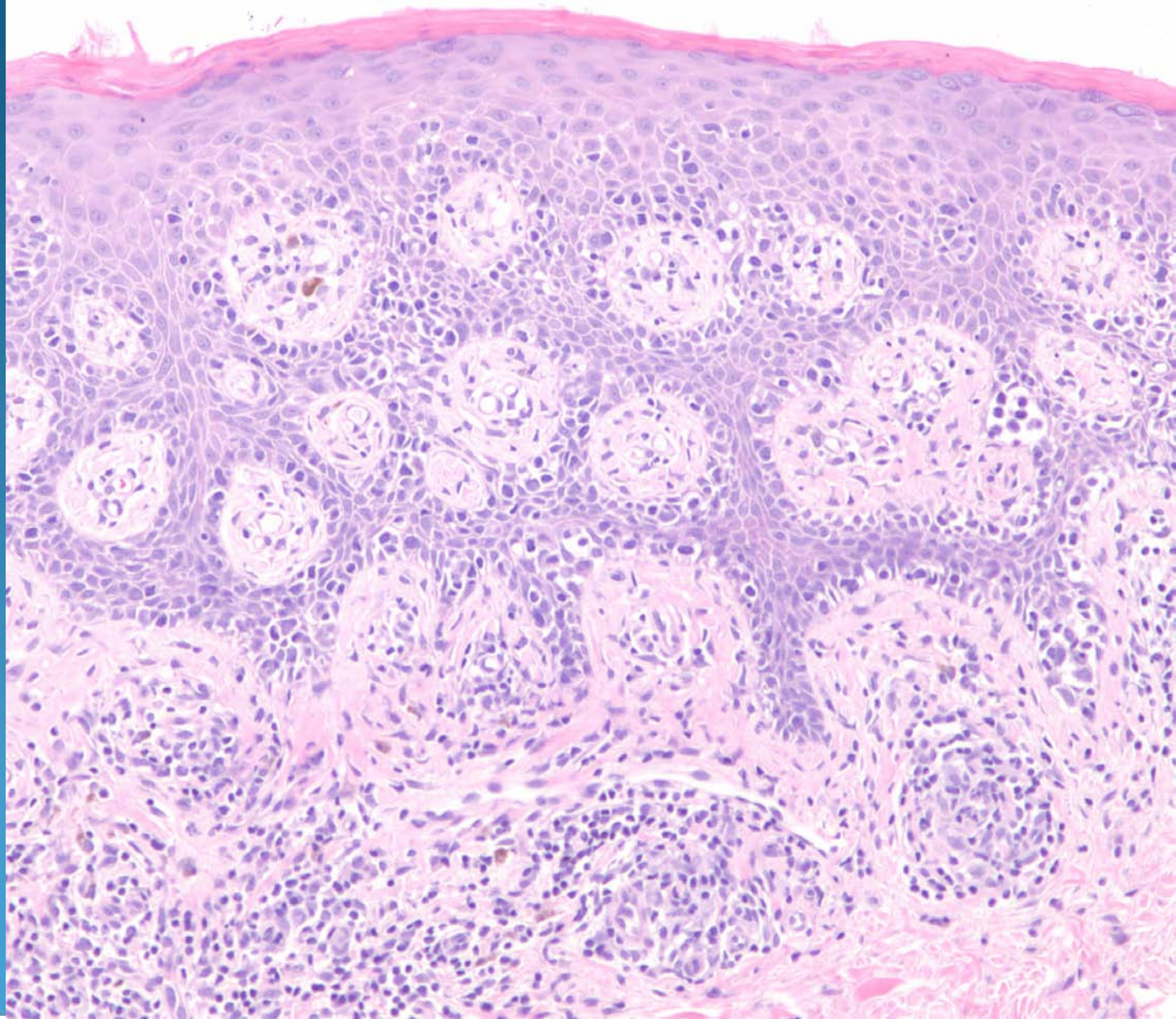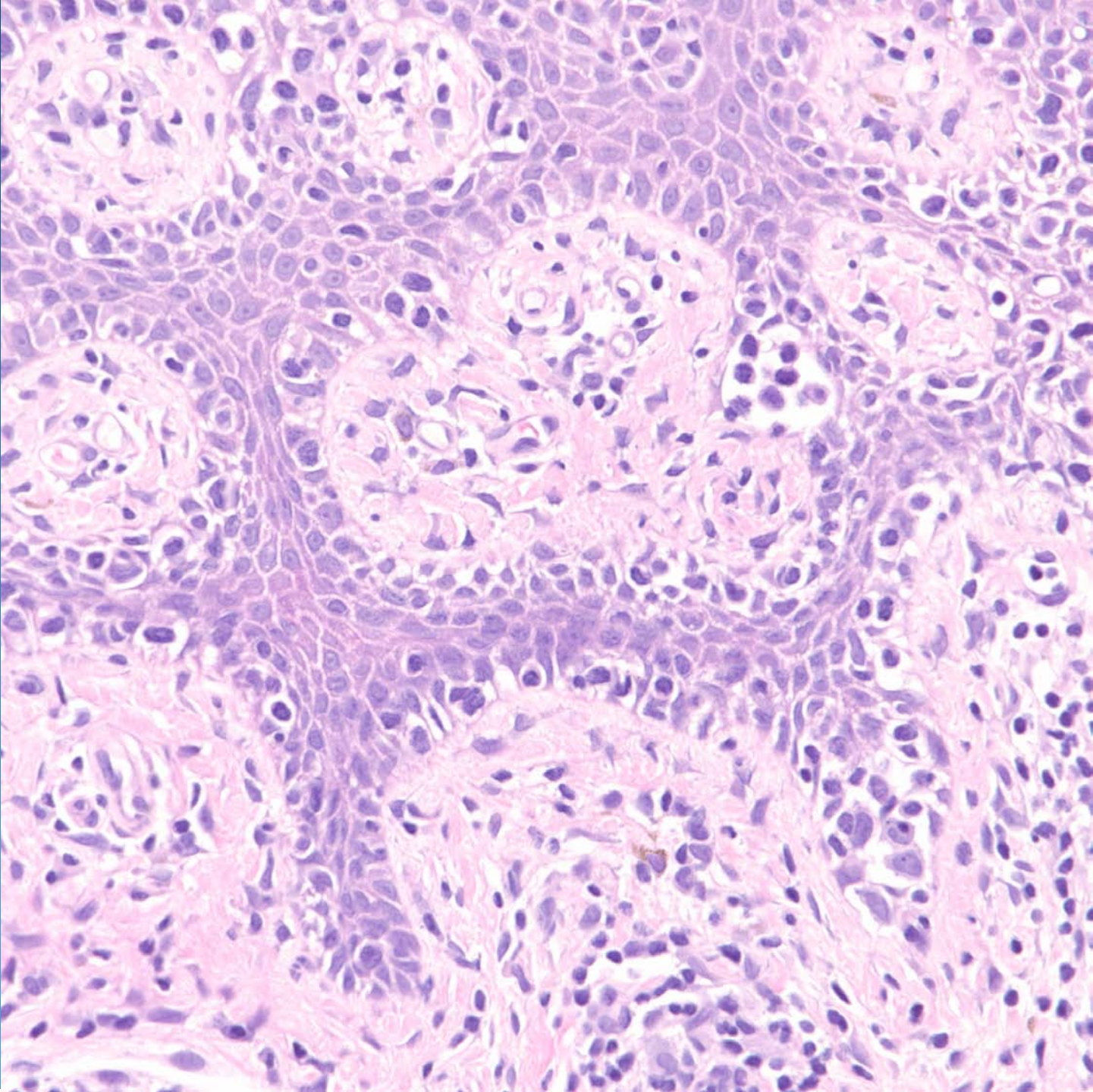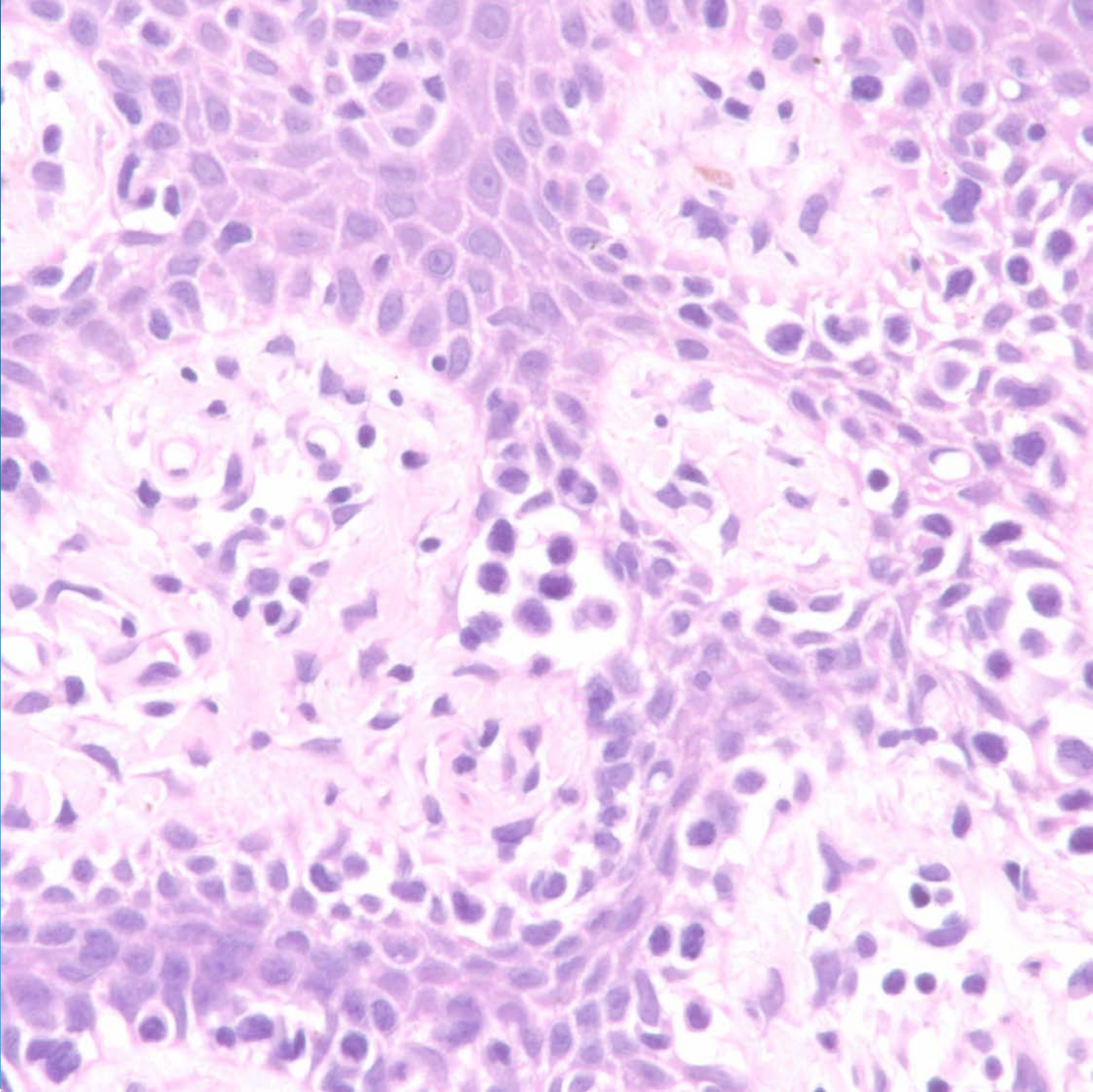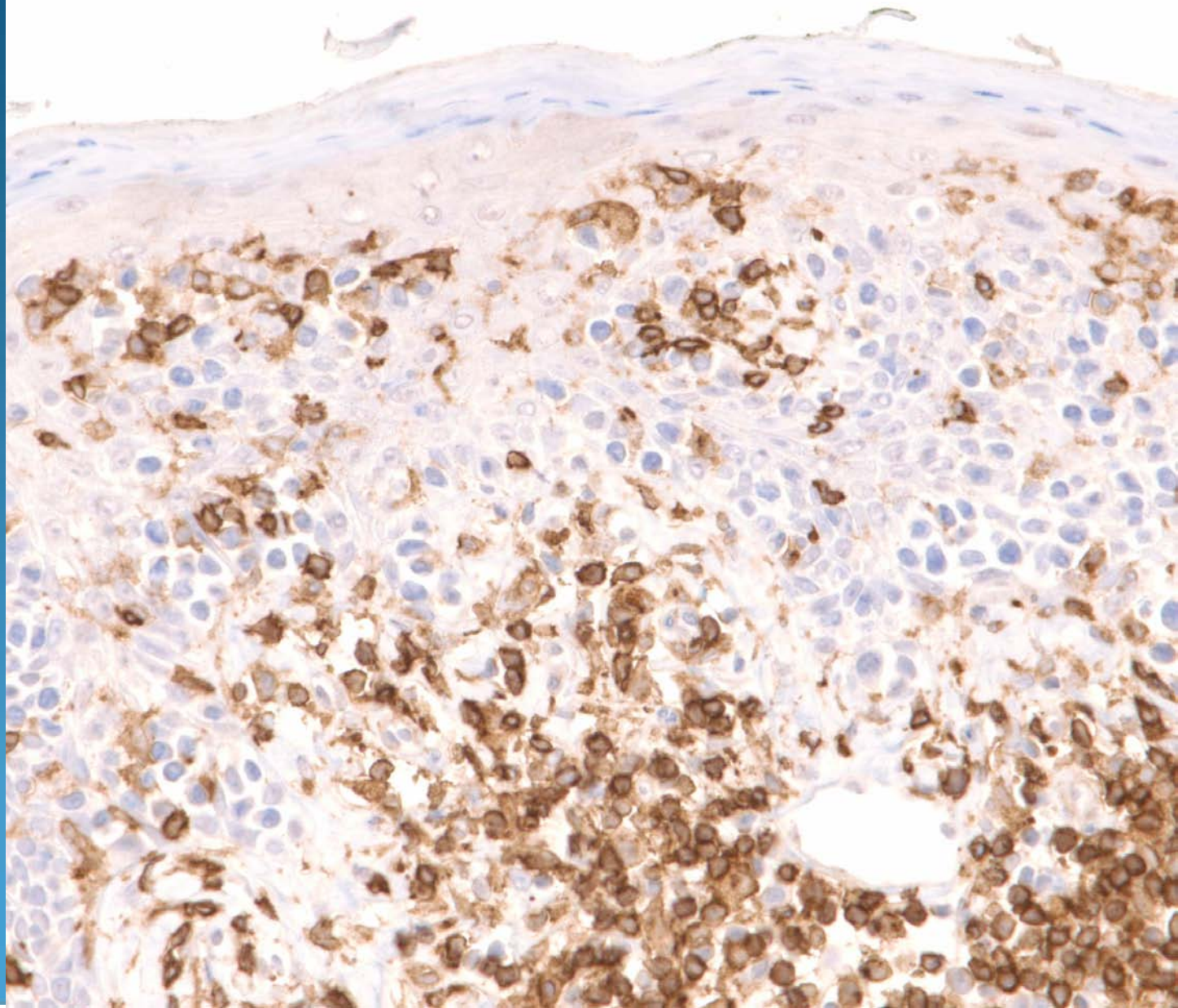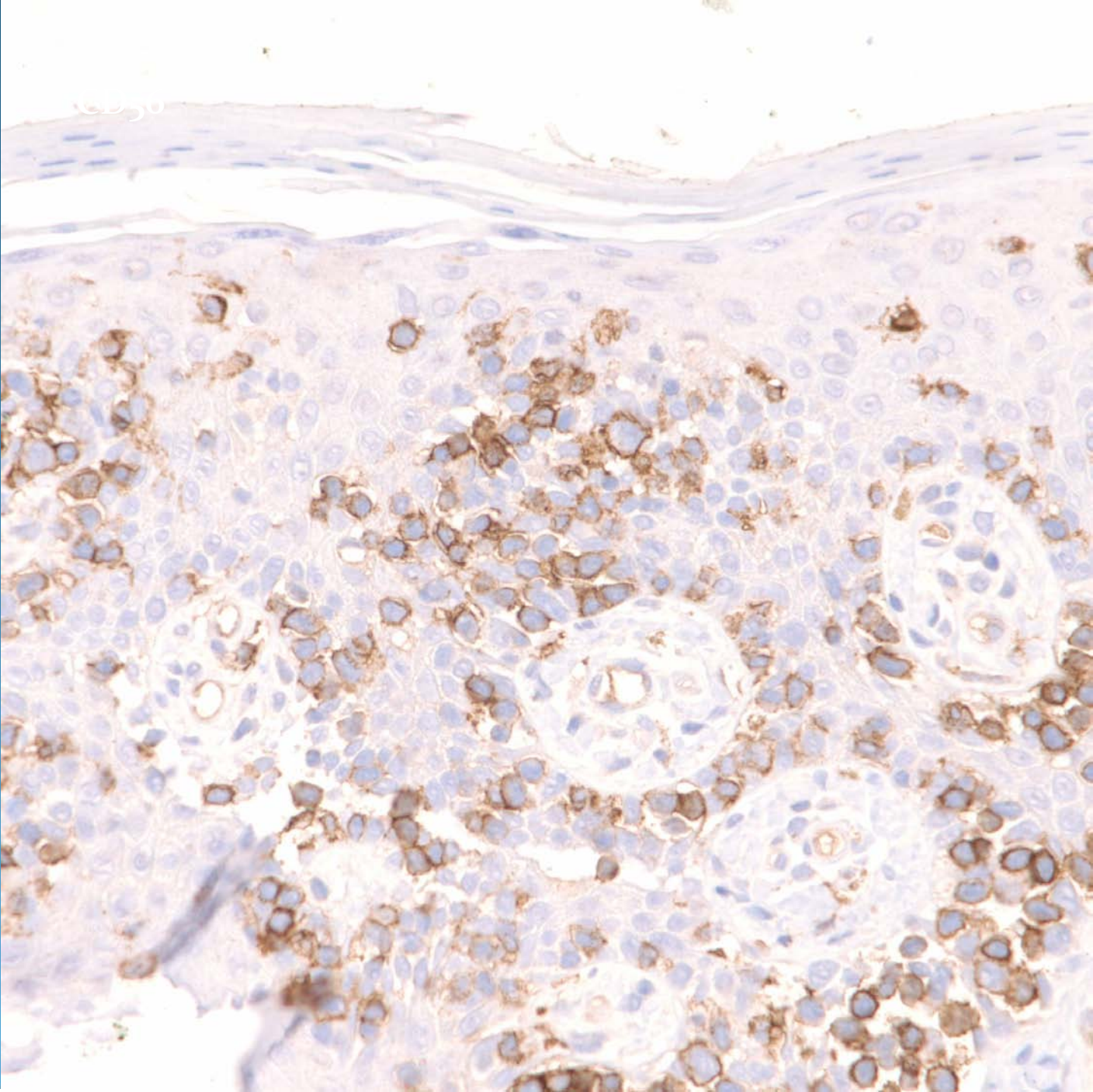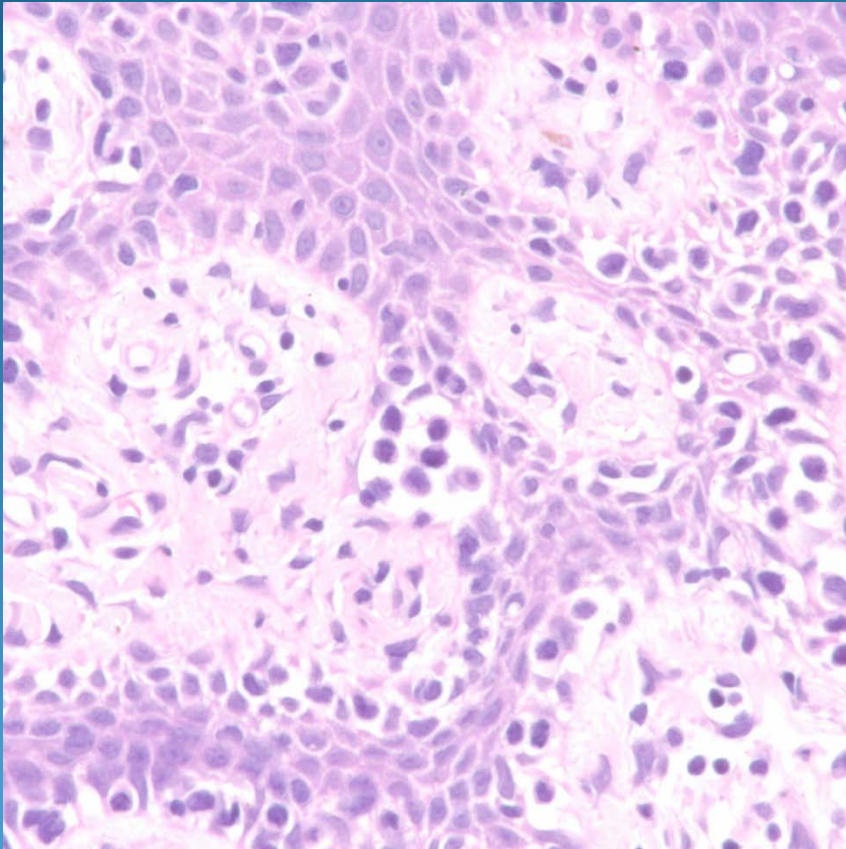


# Mycosis Fungoides with CD56 co-expression

# Pearls



- Basal keratinocytic intercalation with atypical lymphocytes
- Pautrier microabscesses
- Confirm with IHC
  - CD4+
  - CD5 and CD7 -
- CD56+ may portend more aggressive course