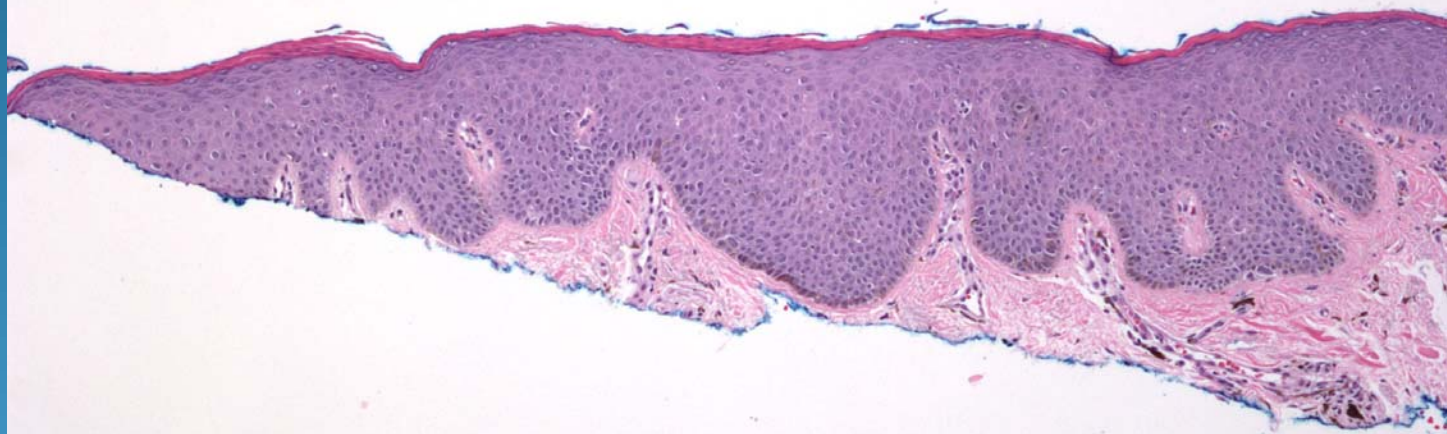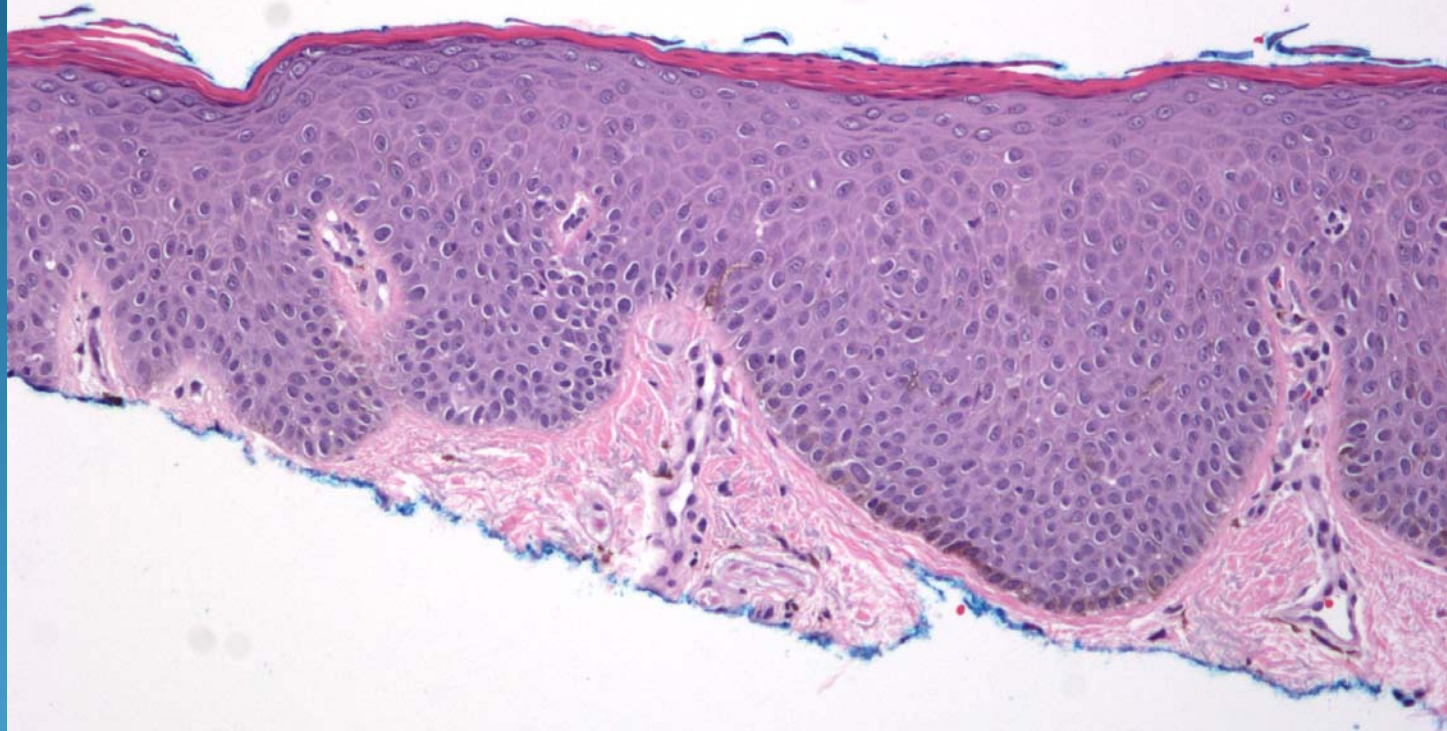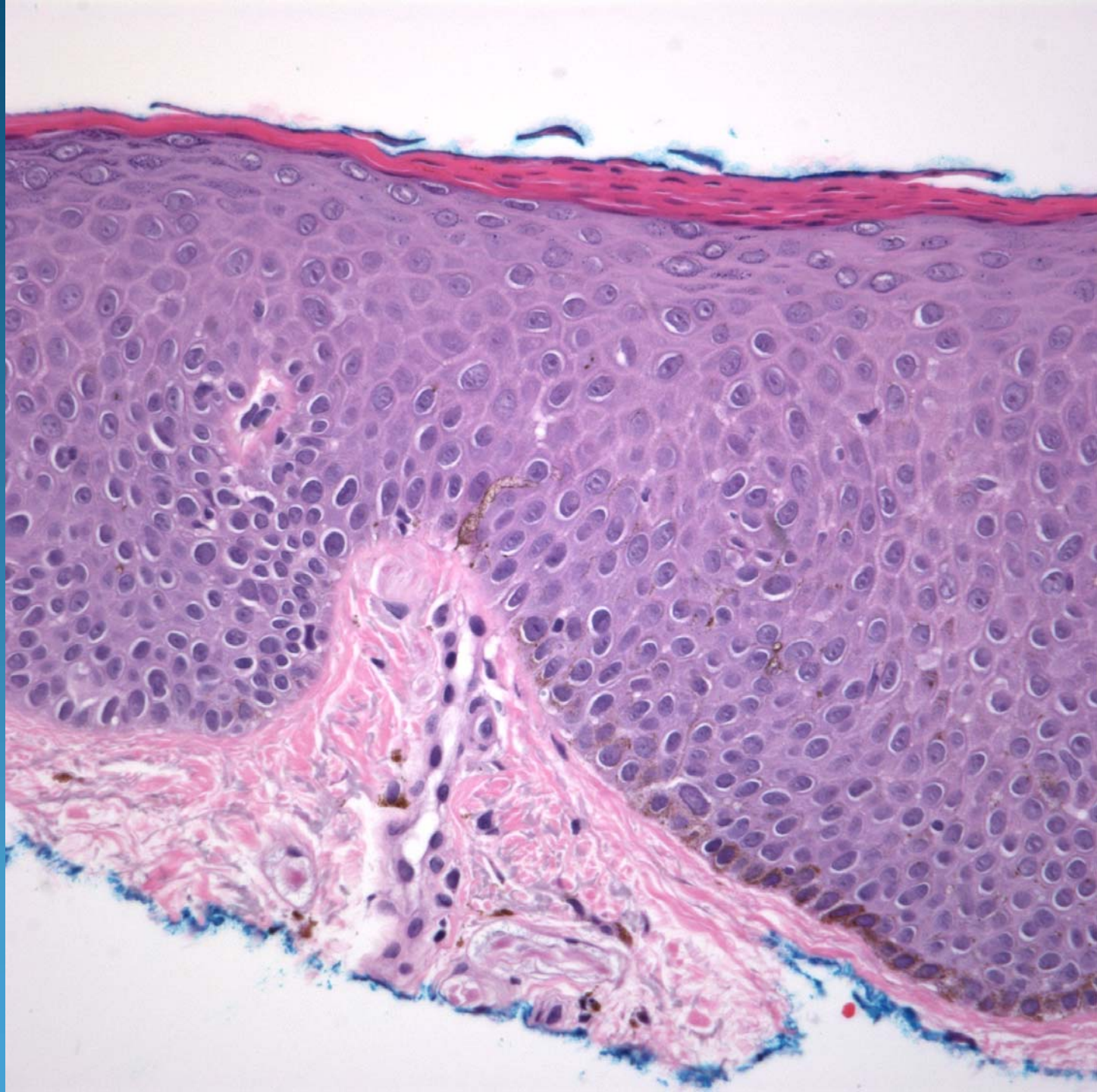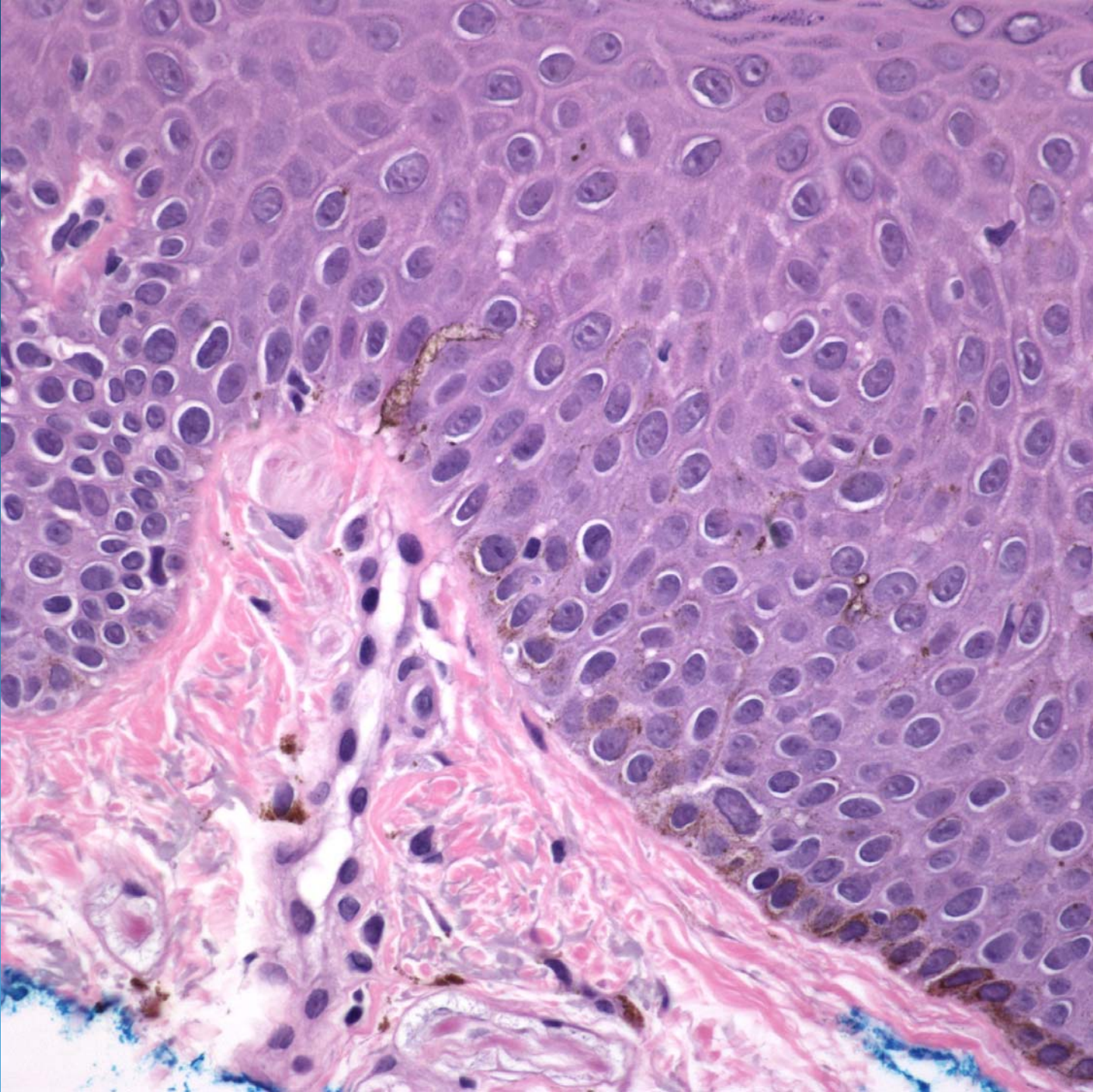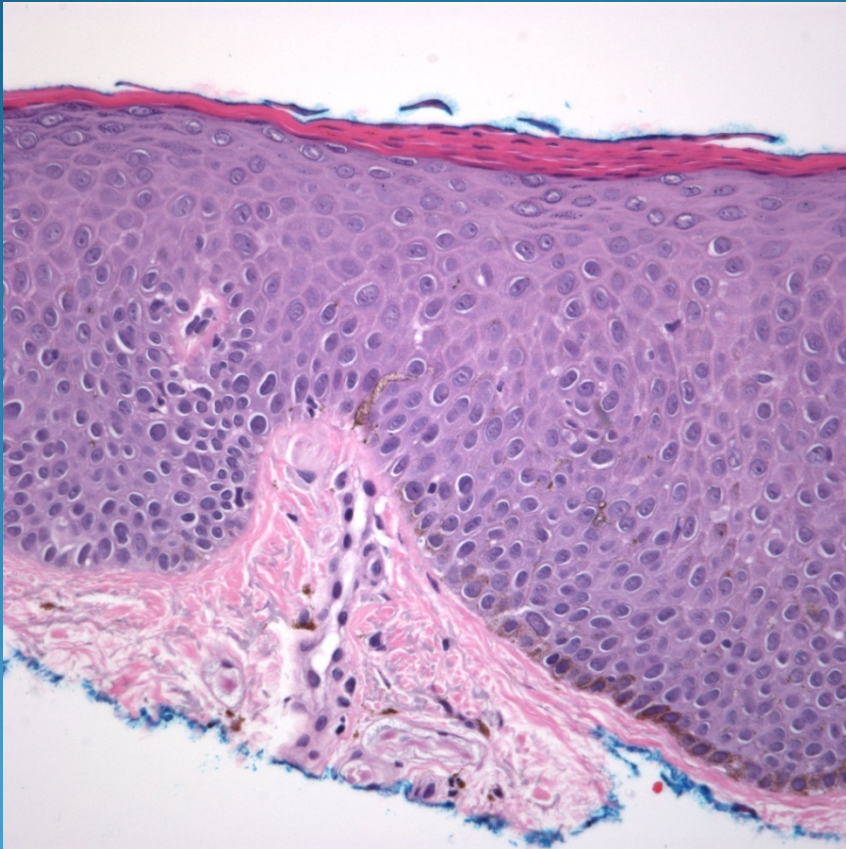


Mucosal Lentigo (Labial Melanotic Macule)

Pearls



- Melanin hyperpigmentation at the basal epithelial layer
- Unassociated with increase in melanocytes
- Compare adjacent non-pigmented mucosa for confirmation