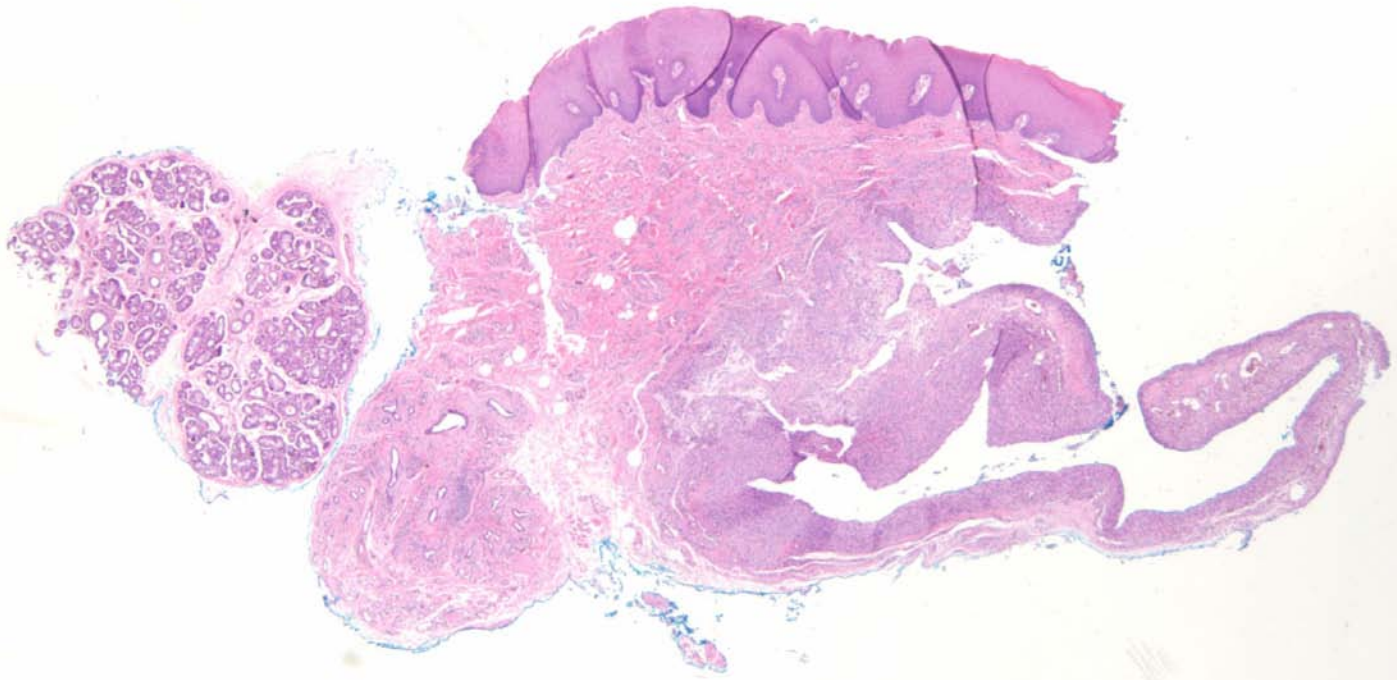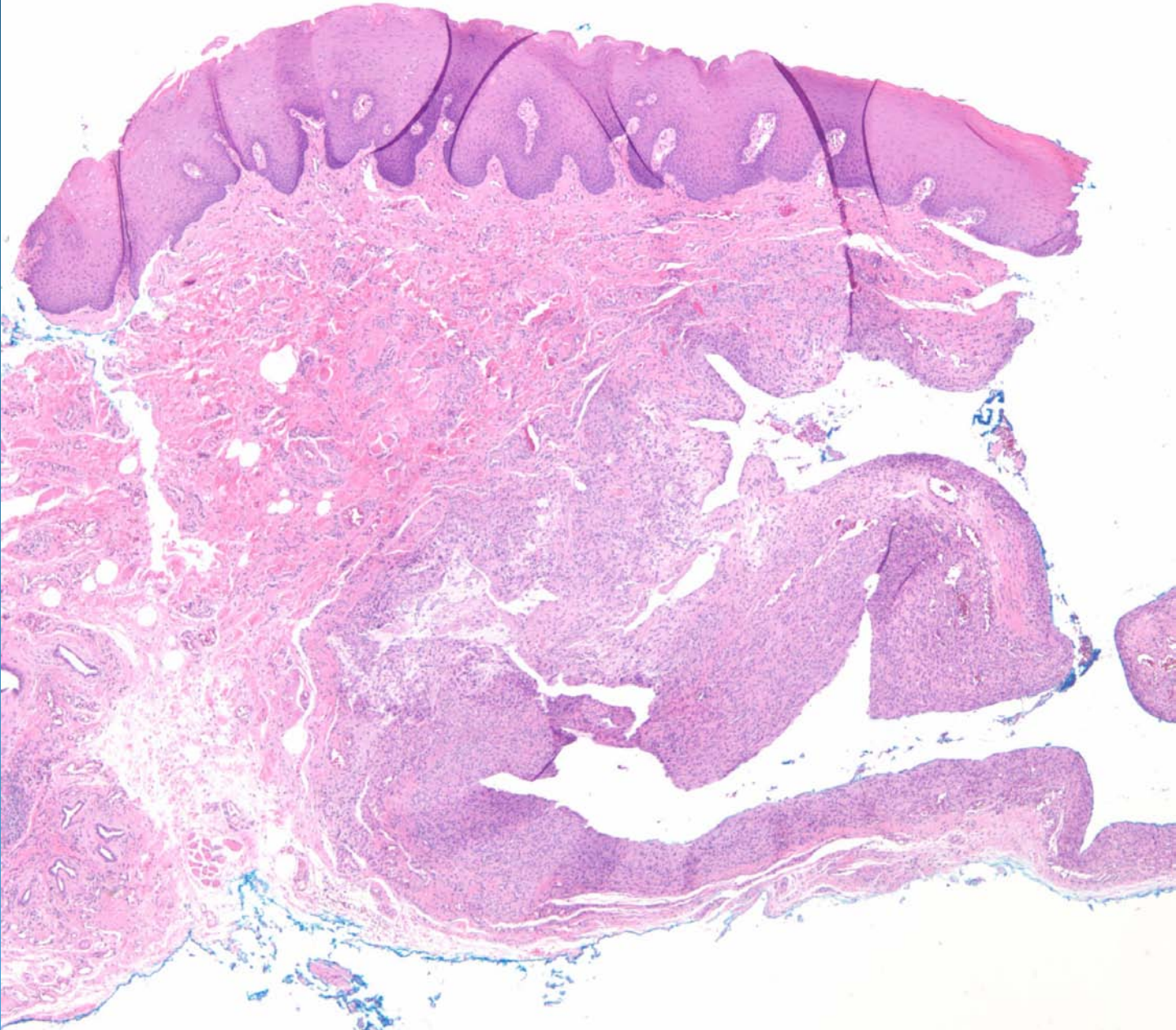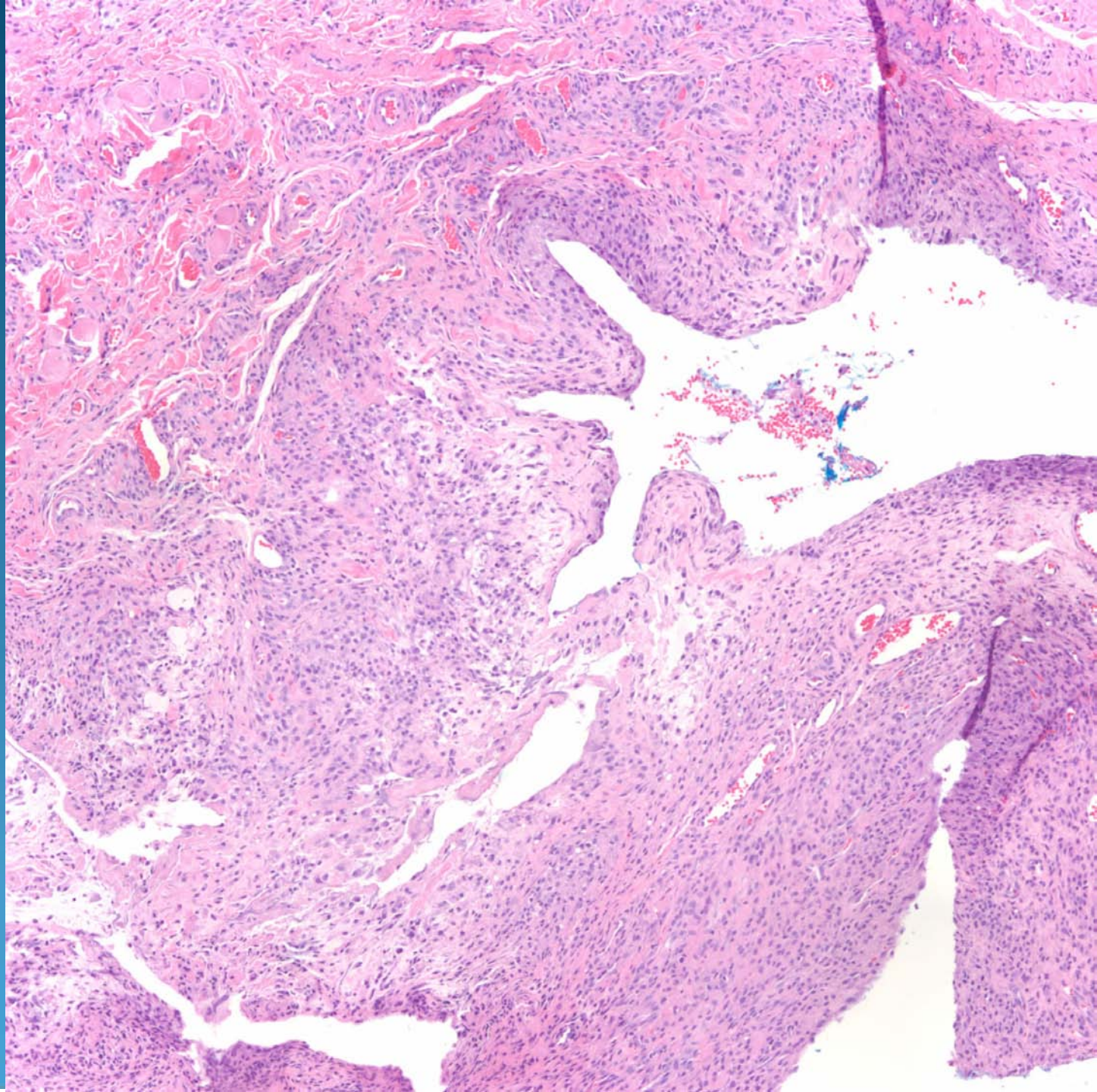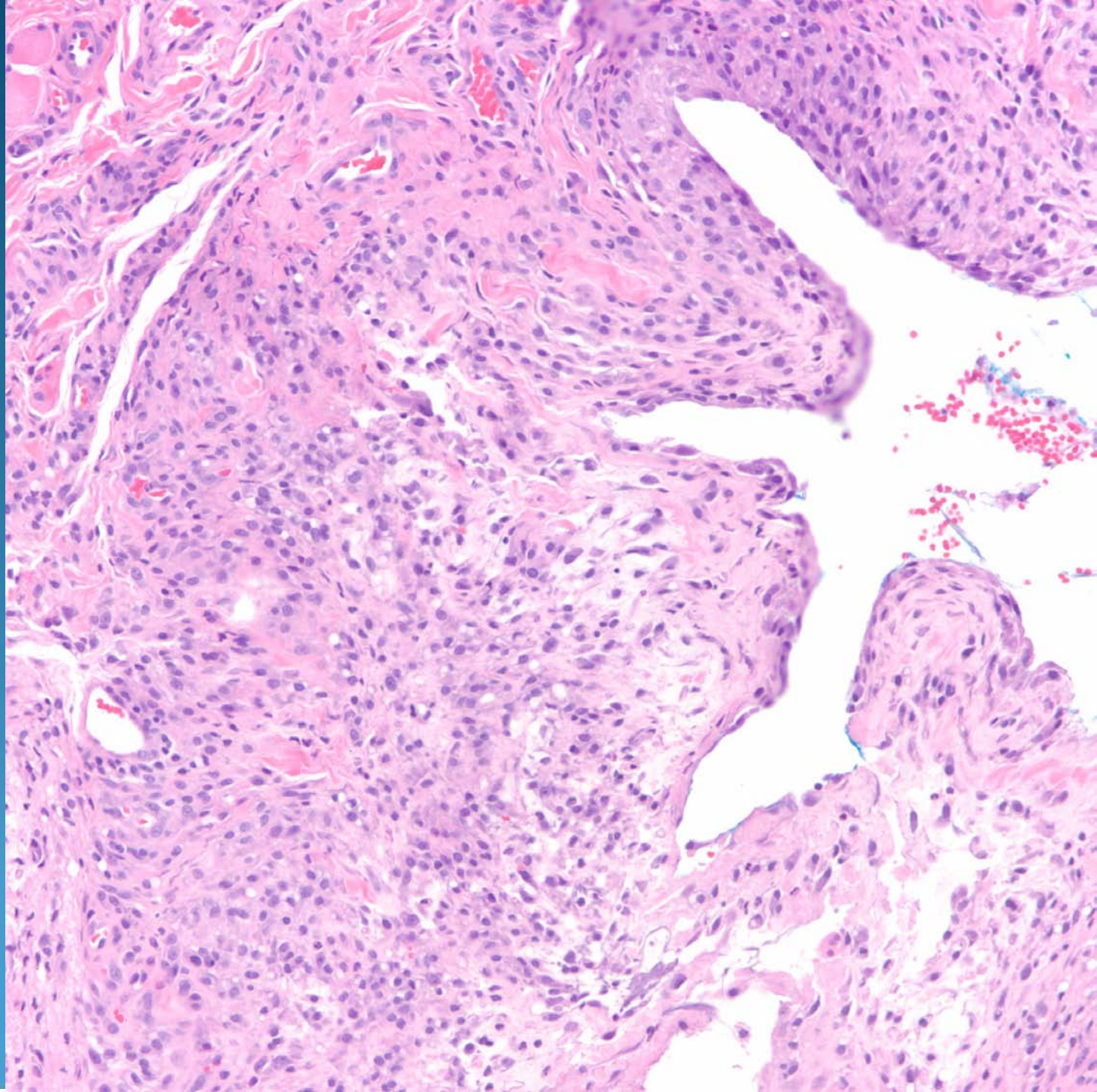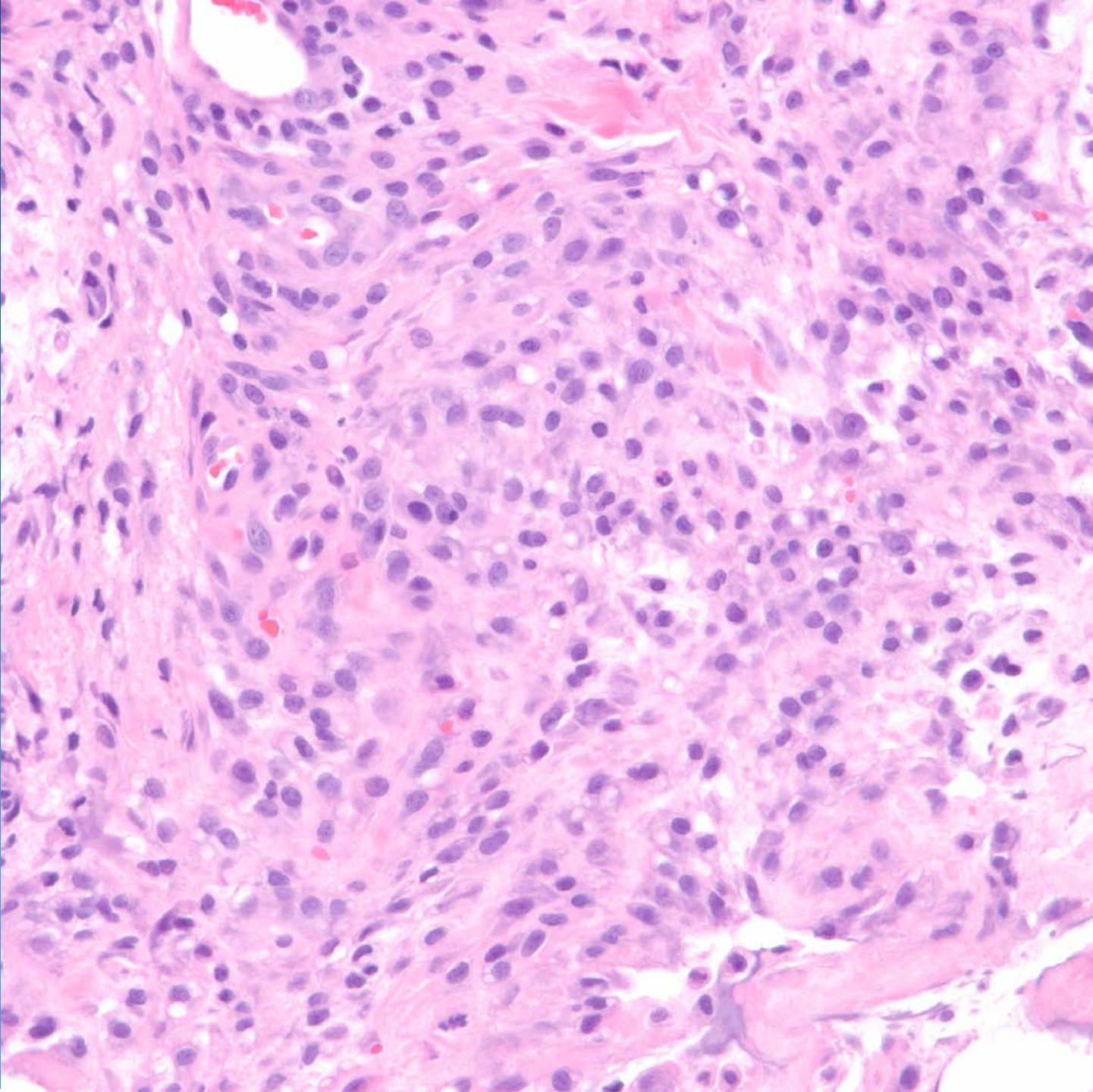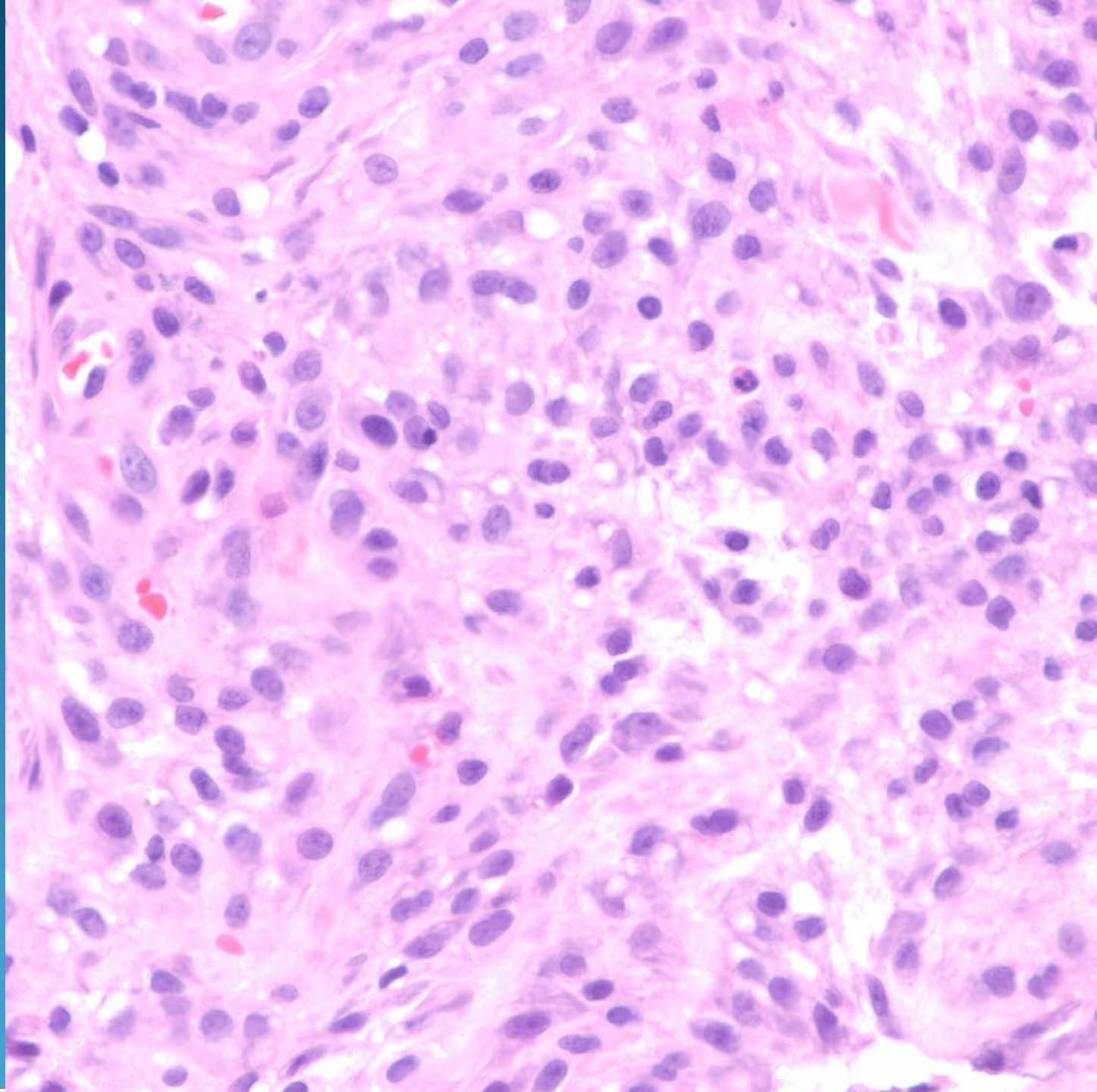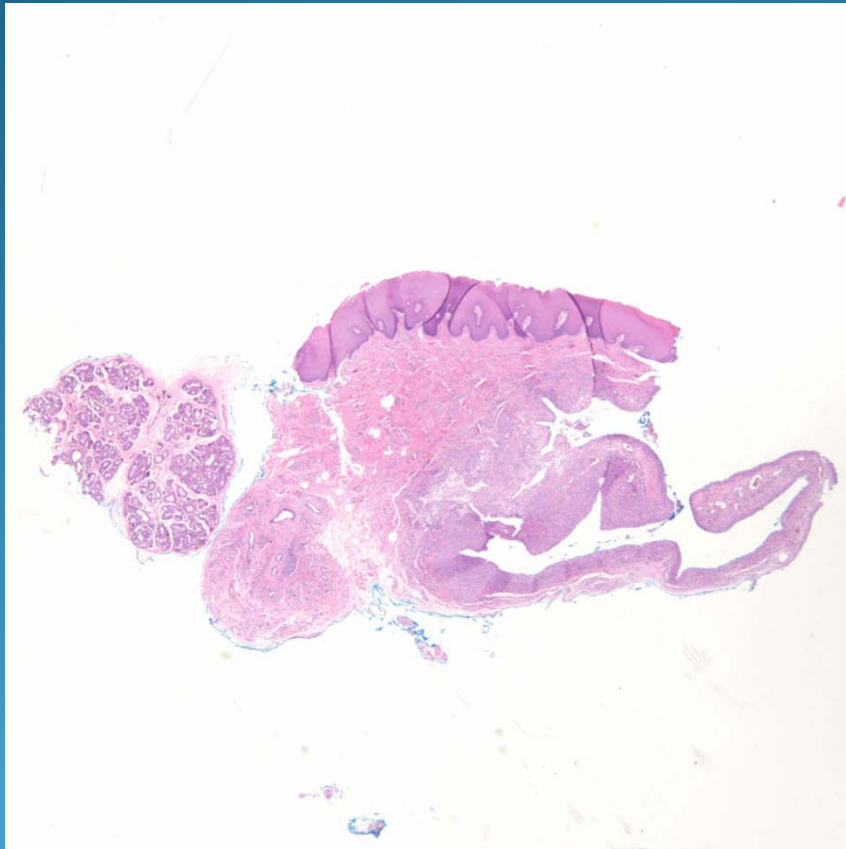


Mucocele

Pearls



- Look for oral mucosa and minor salivary gland tissue
- Pseudocyst with no true epithelial lining
- Cystic space with granulation tissue and numerous muciphages