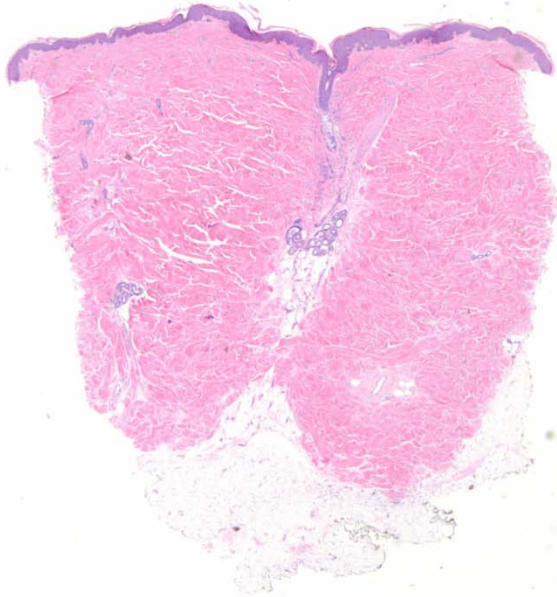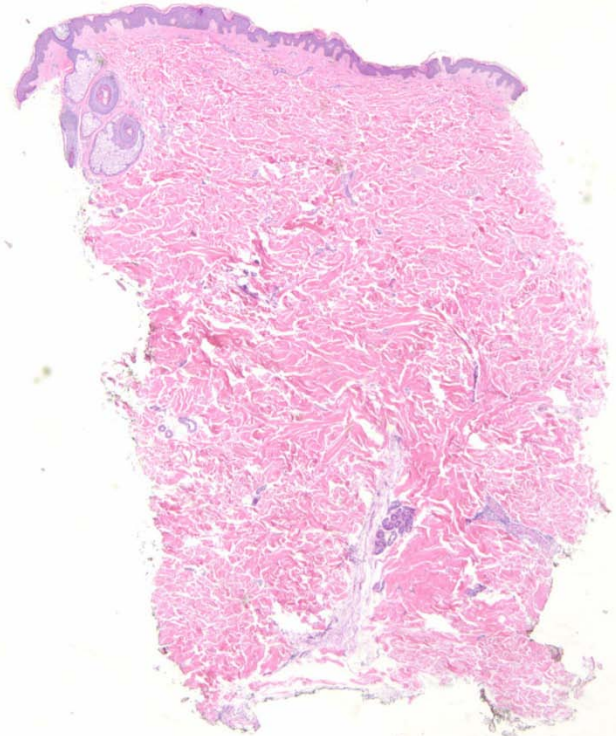
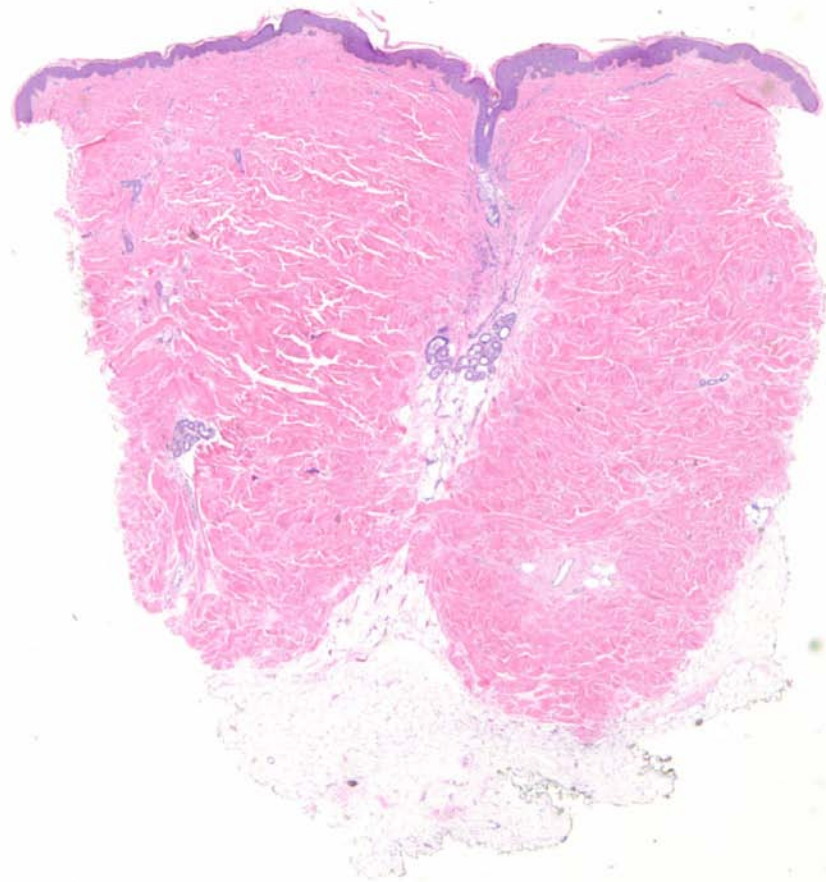


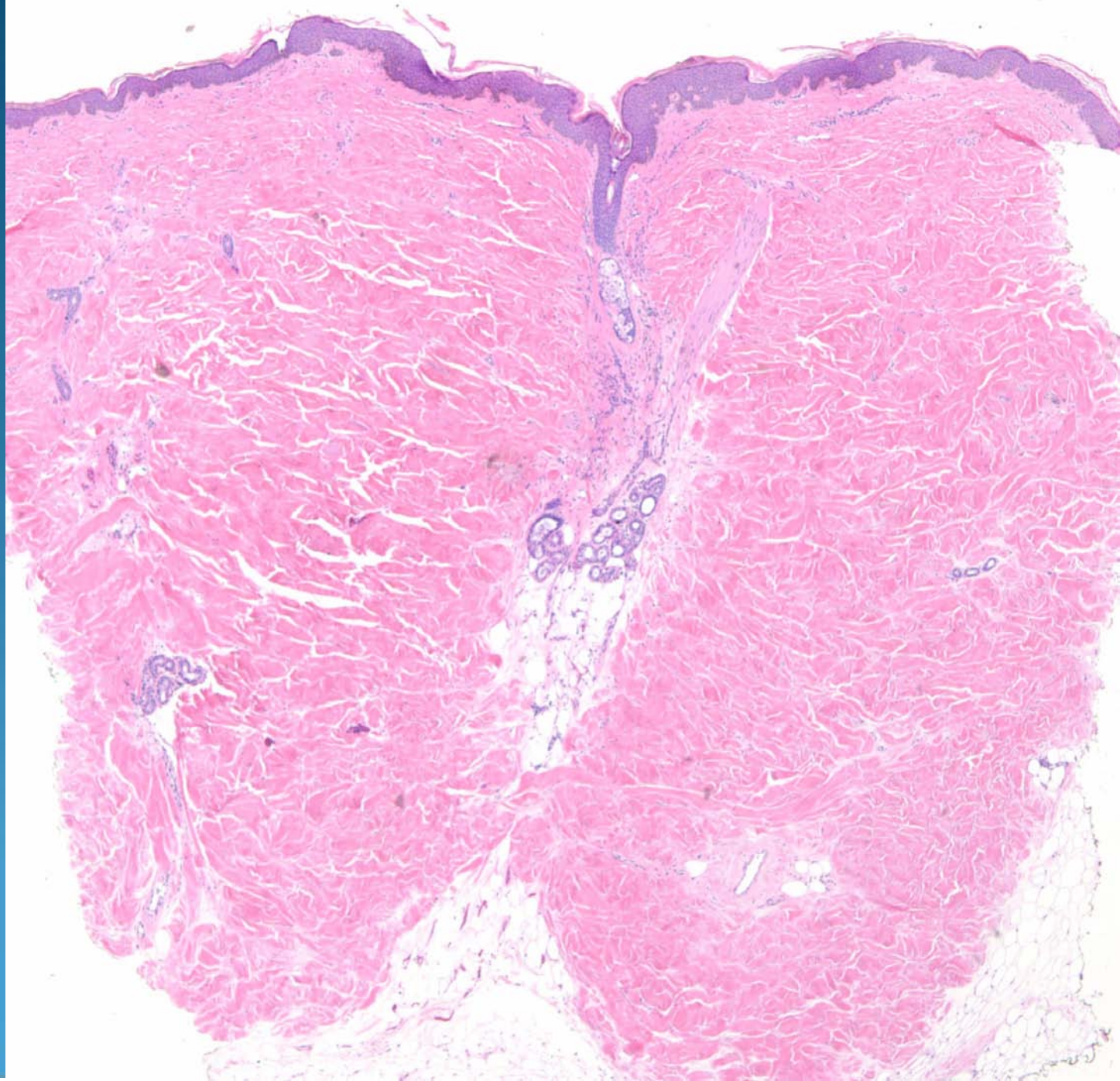
Lesional Skin

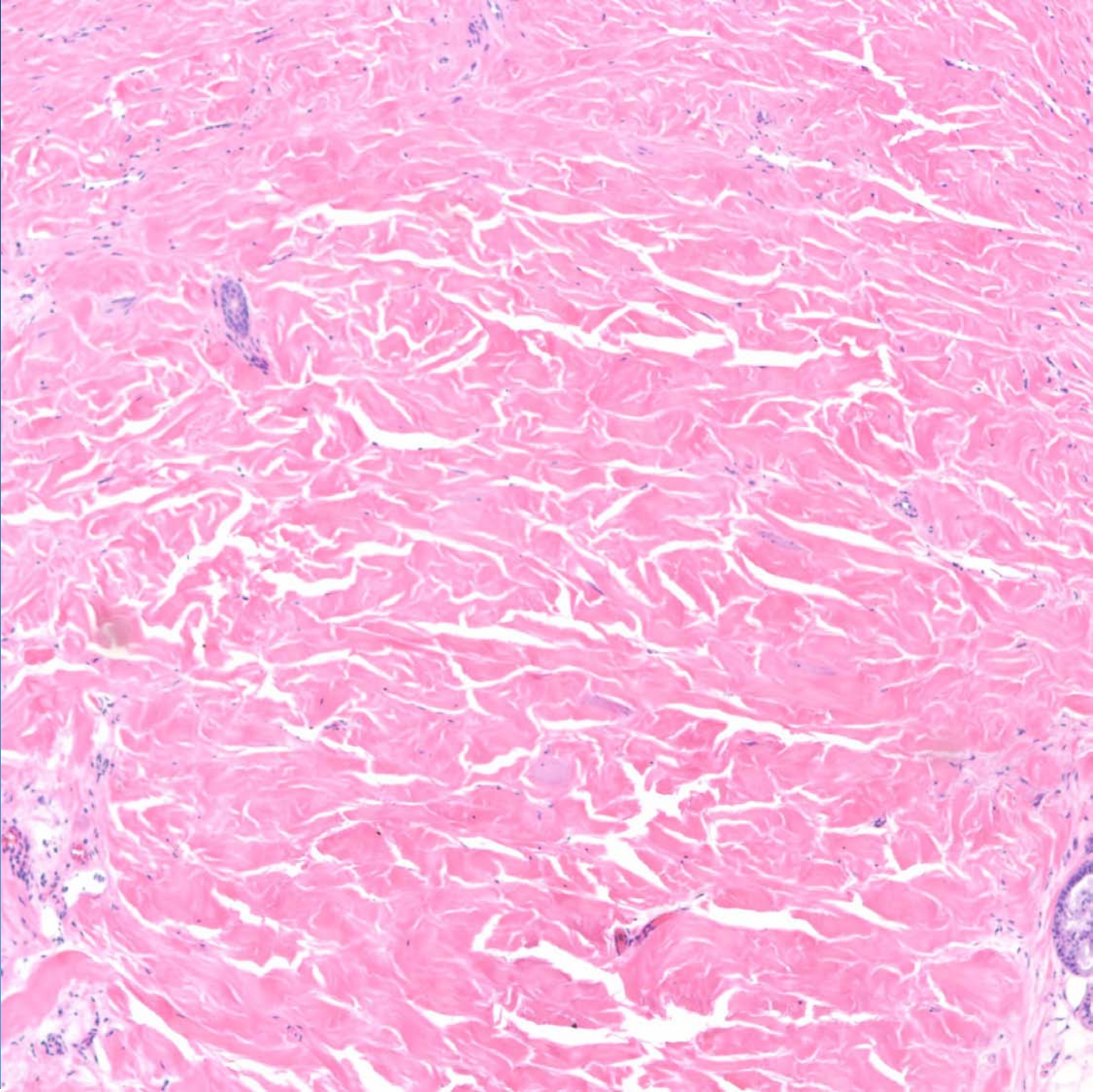


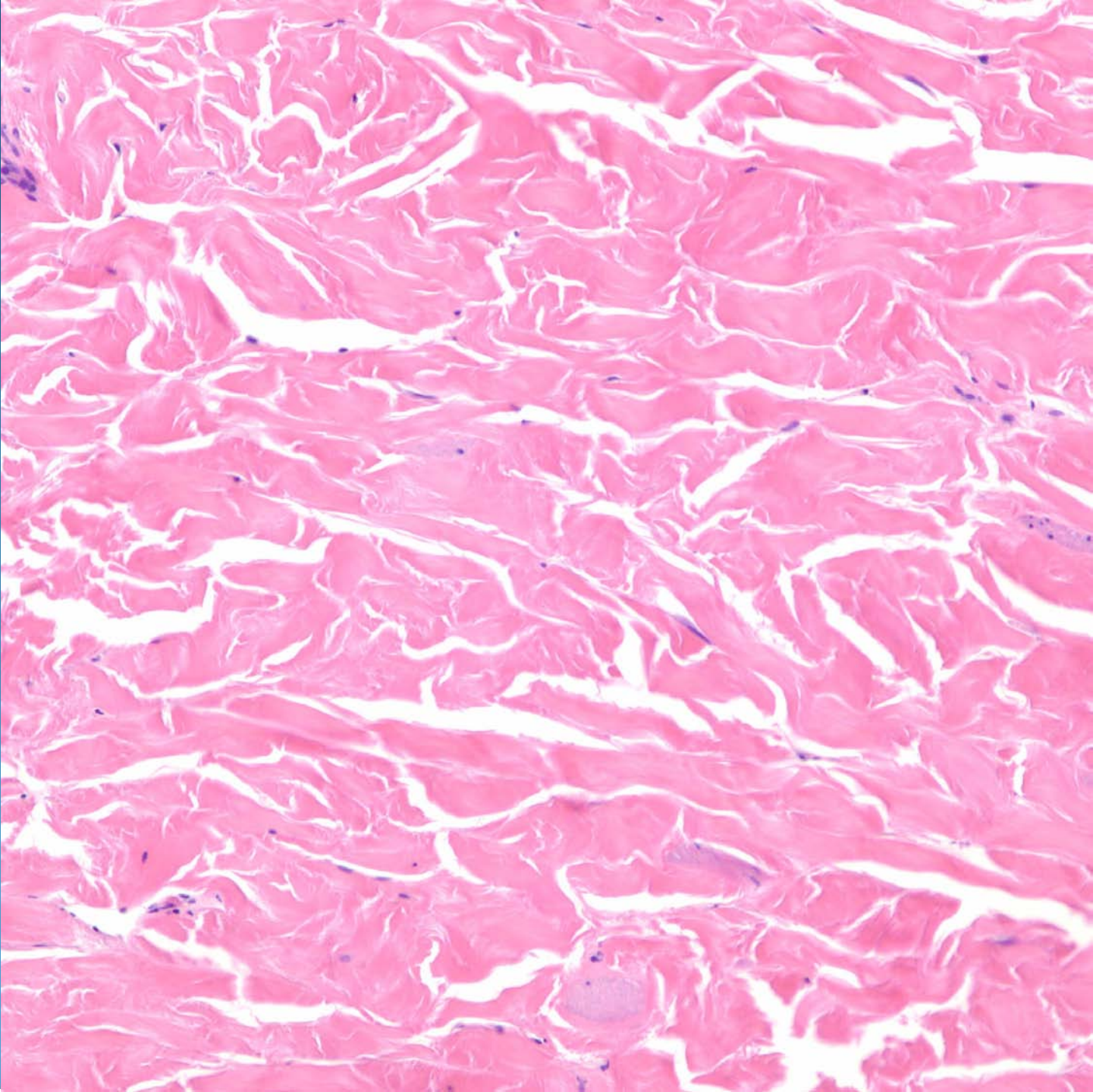
Perilesional Skin





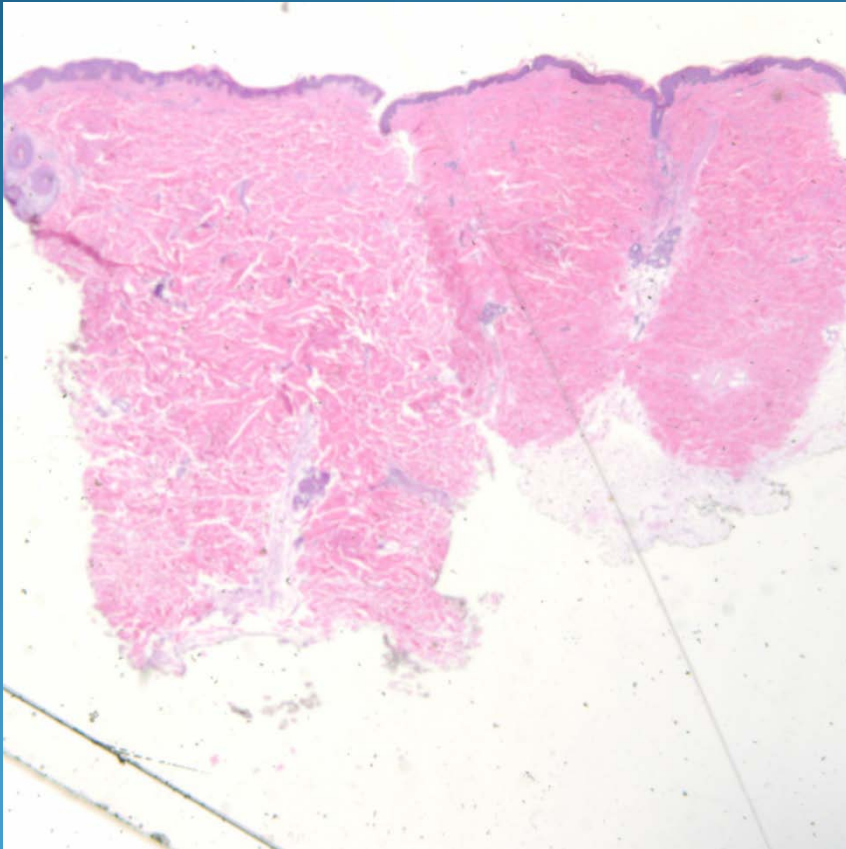






Morphea

Pearls



- Morphea may sometimes have minimal changes
- Excellent way to establish the diagnosis is to take a biopsy of adjacent non-lesional skin and compare the dermal thickness with lesional skin, which should be markedly decreased