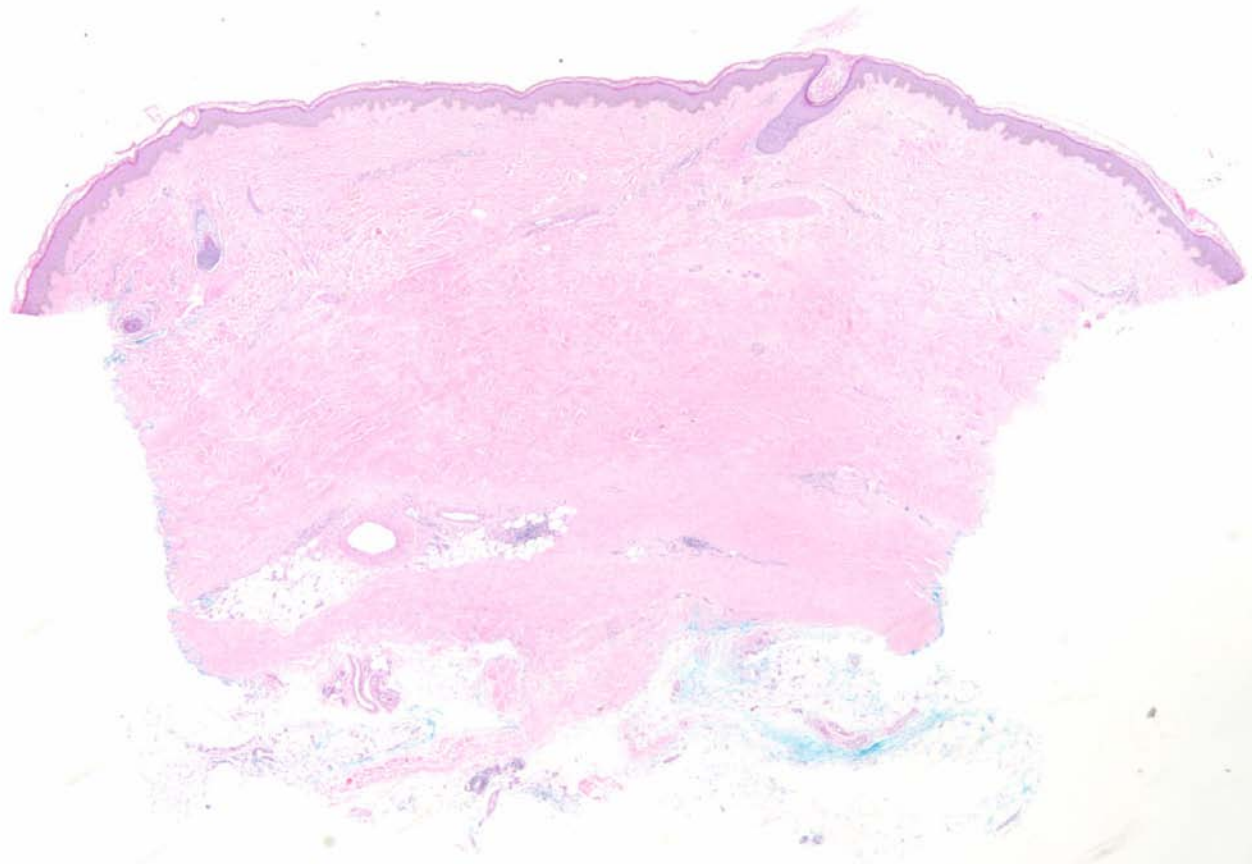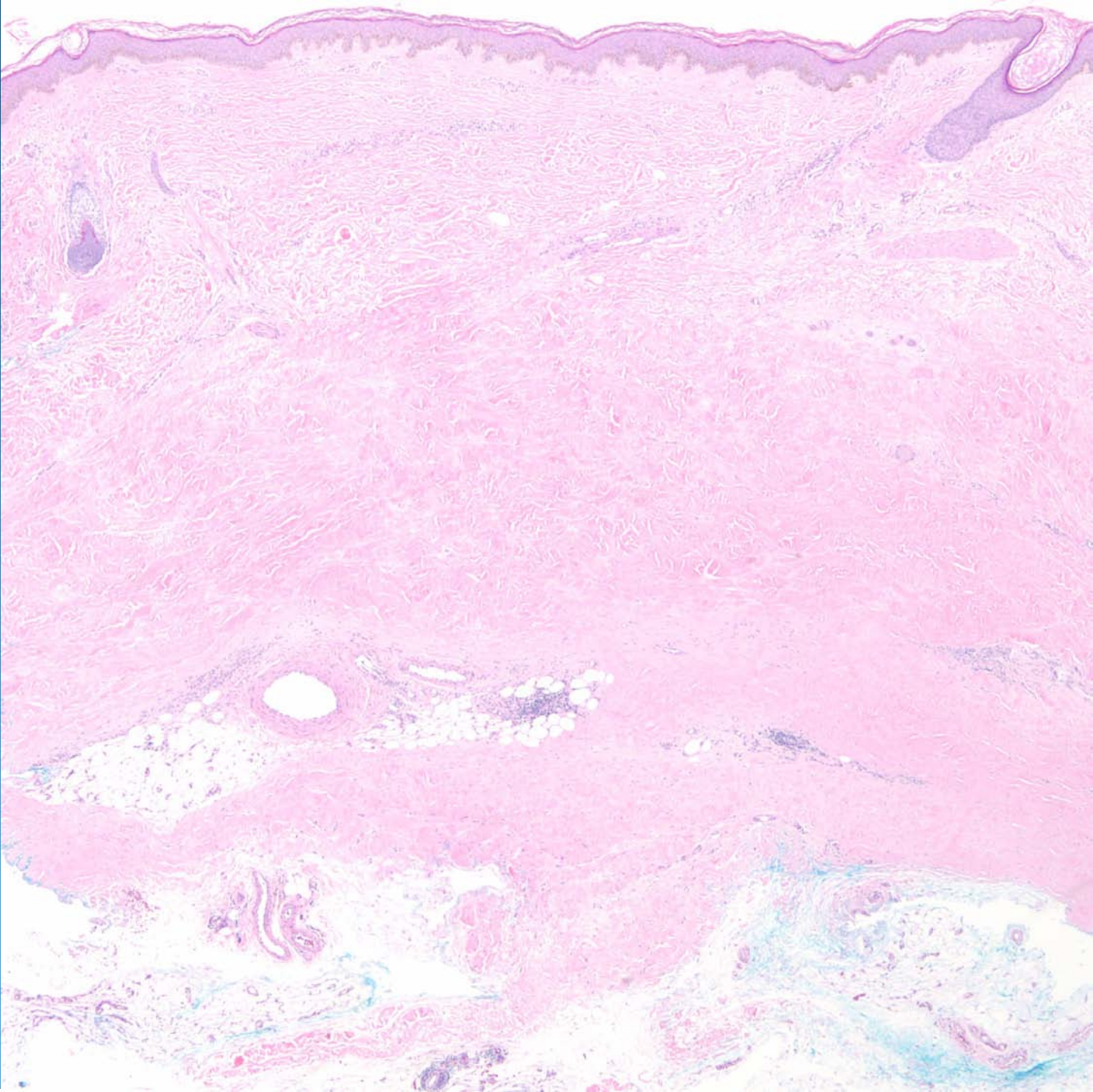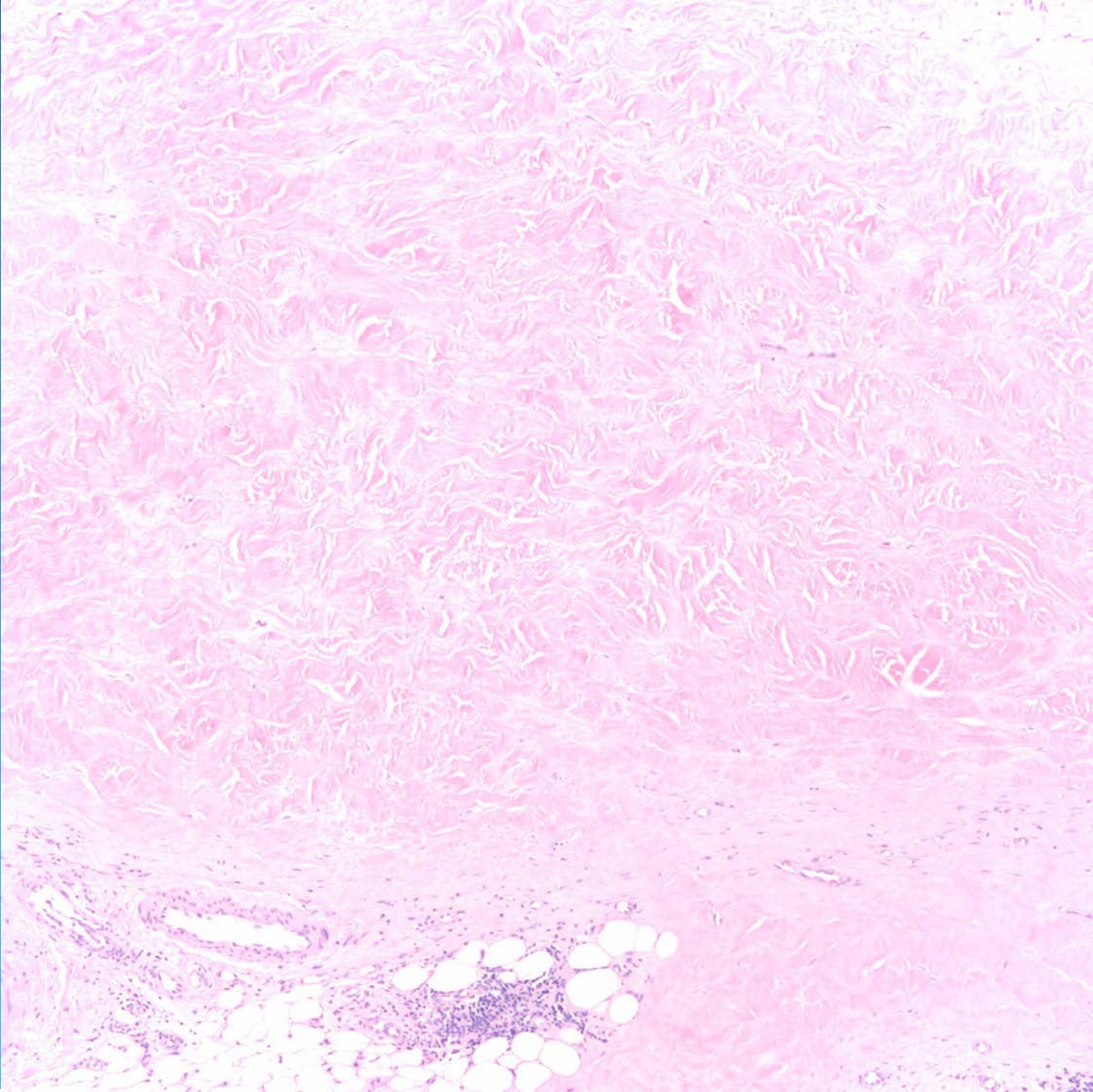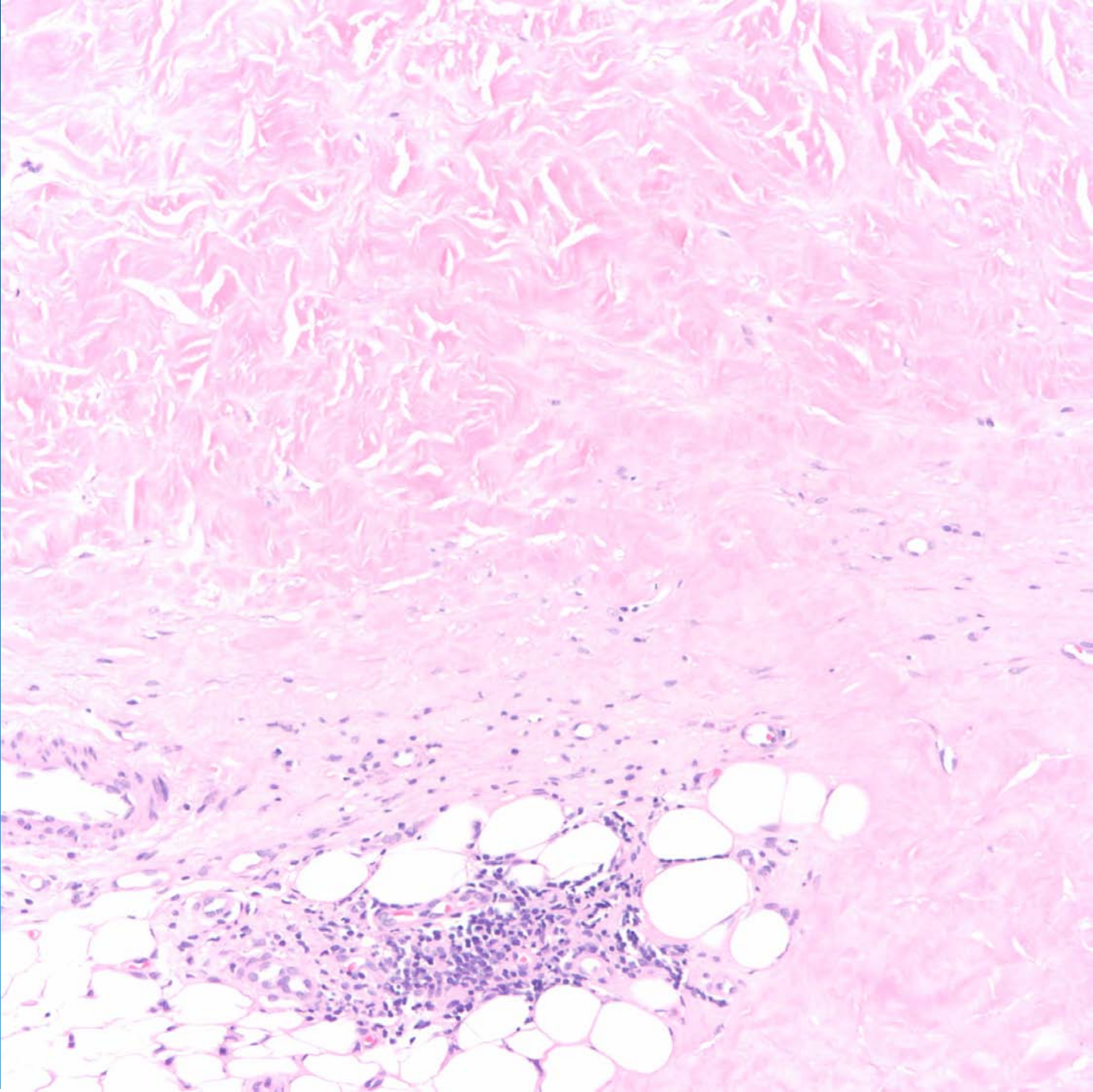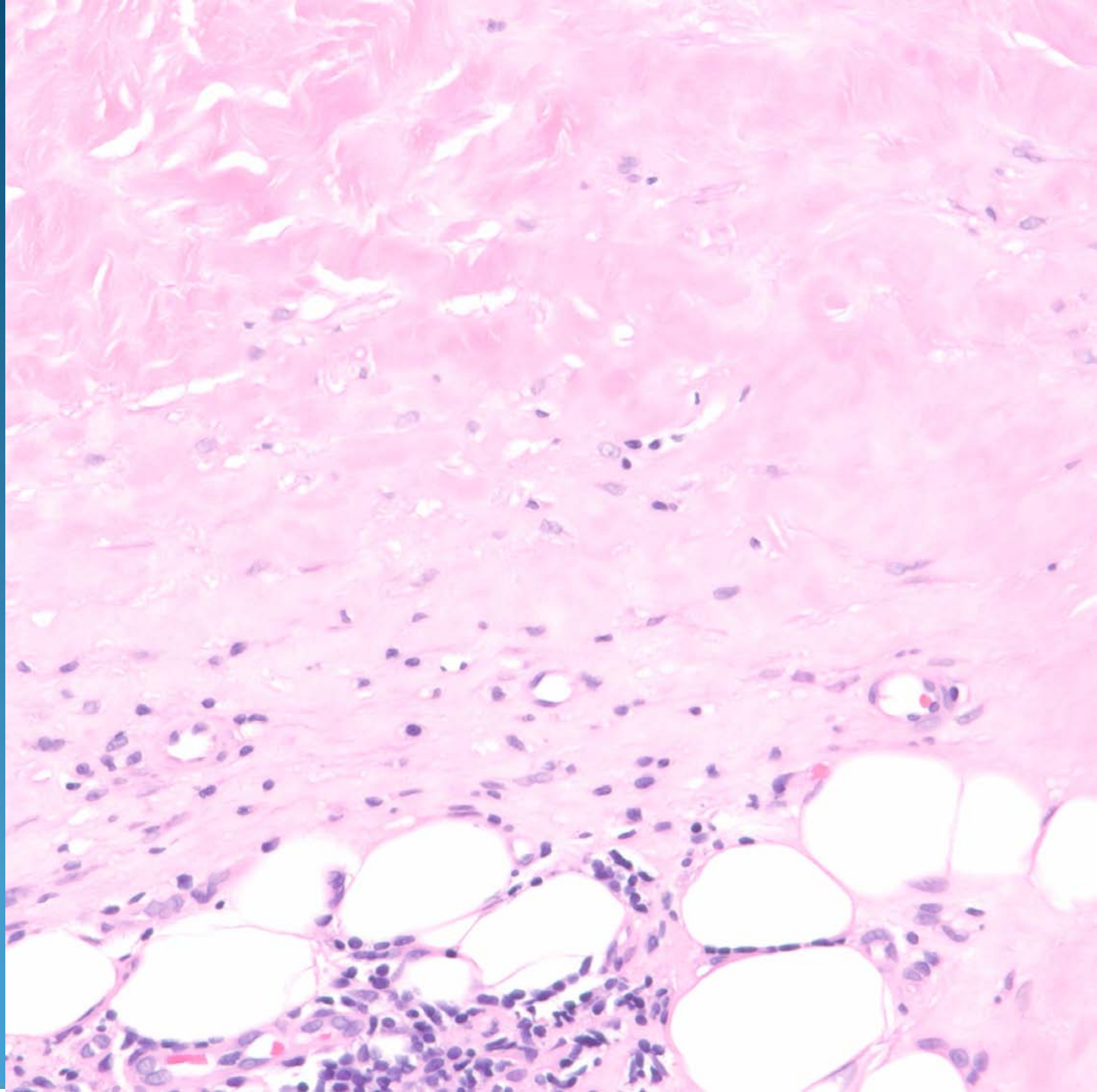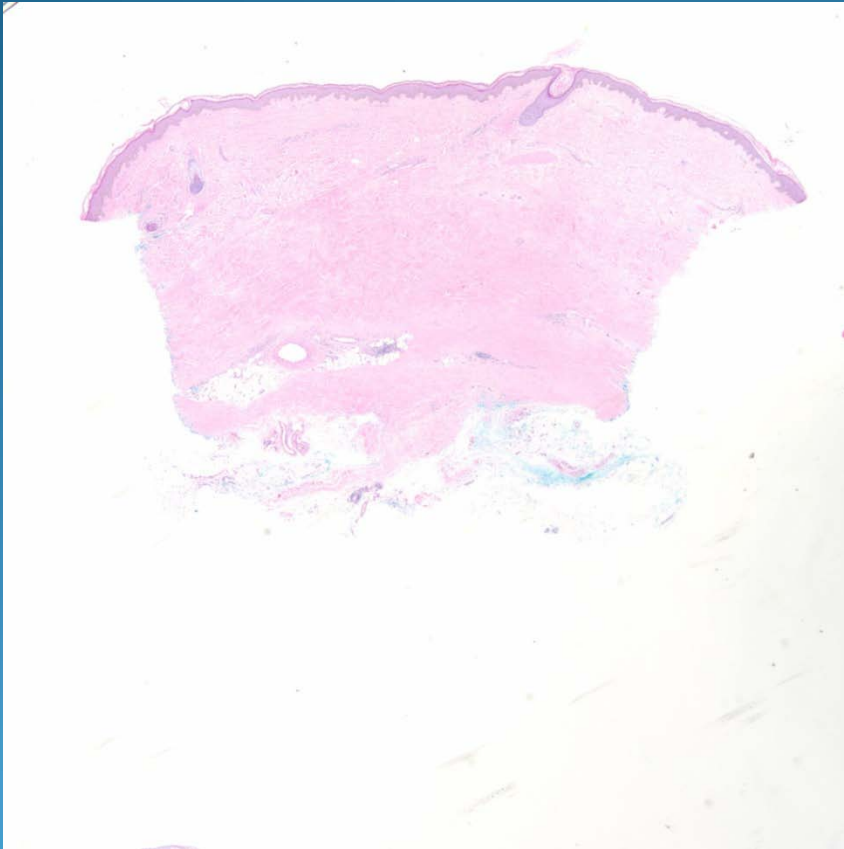


Morphea

Pearls



- Square biopsy sign with extensive dermal sclerosis
- May have superficial and deep perivascular dermatitis with plasma cells
- May extend into subcutaneous adipose tissue (morphea profunda)