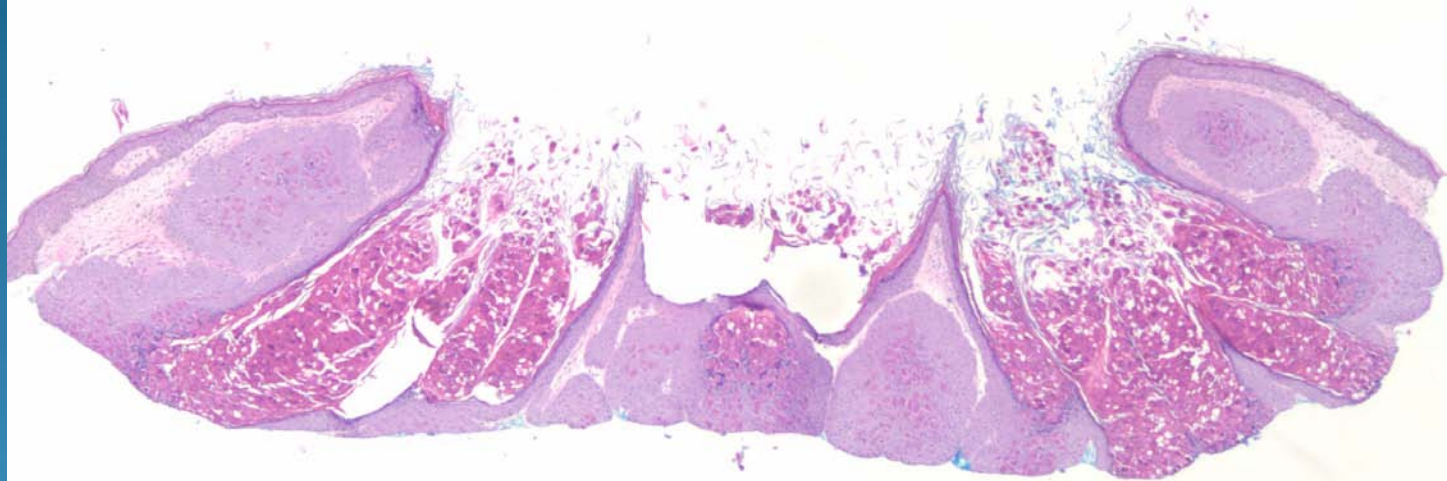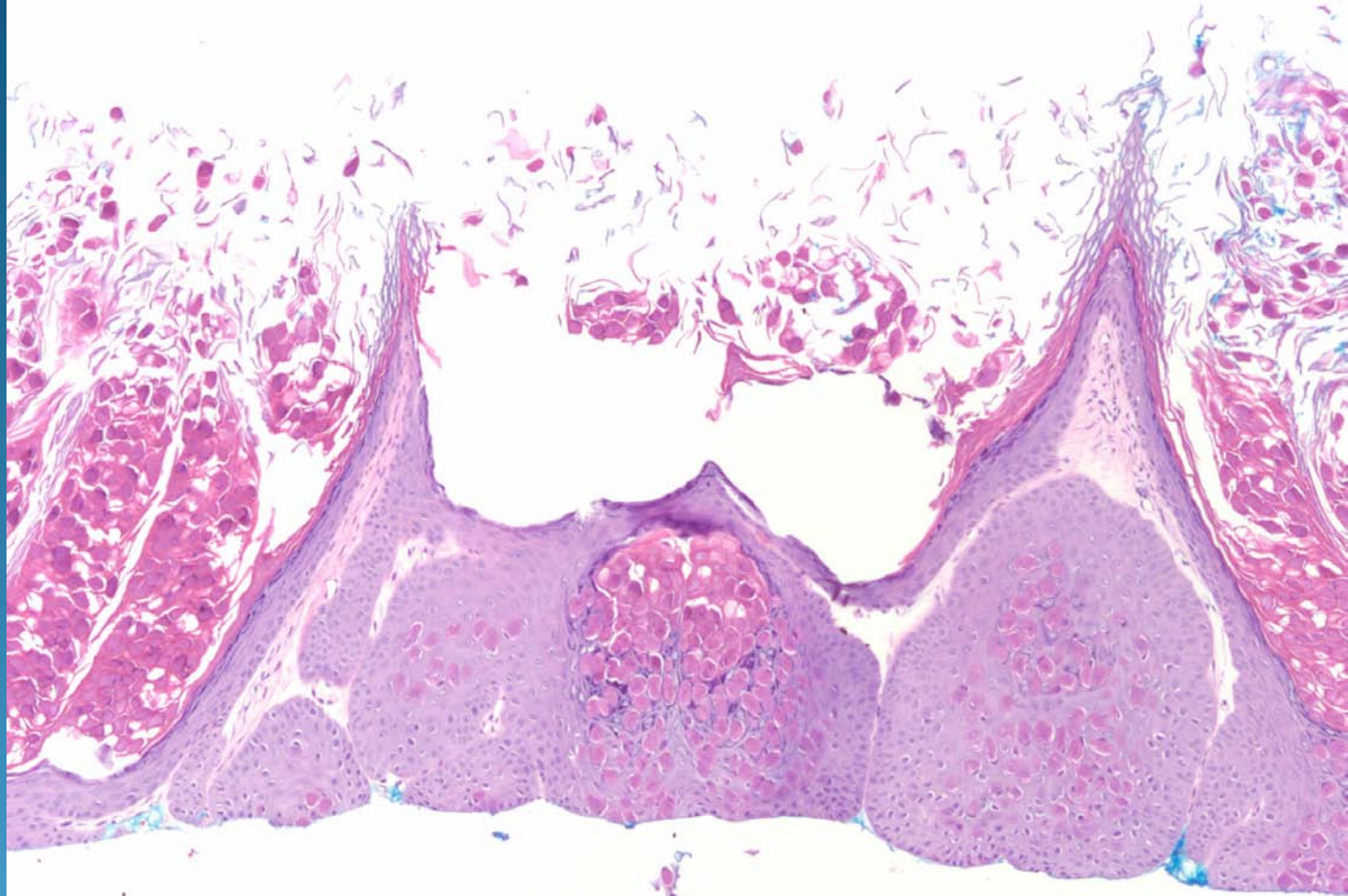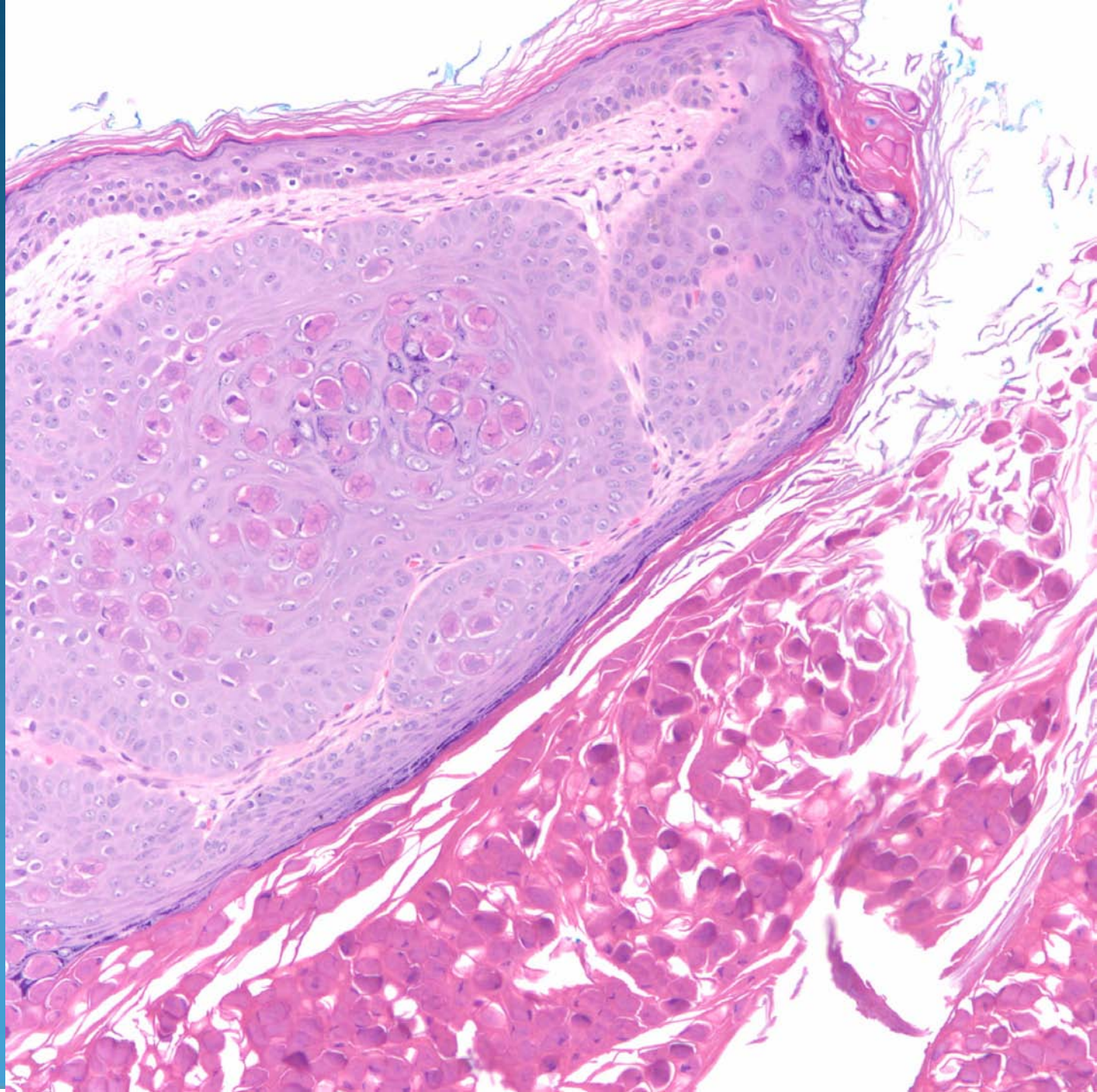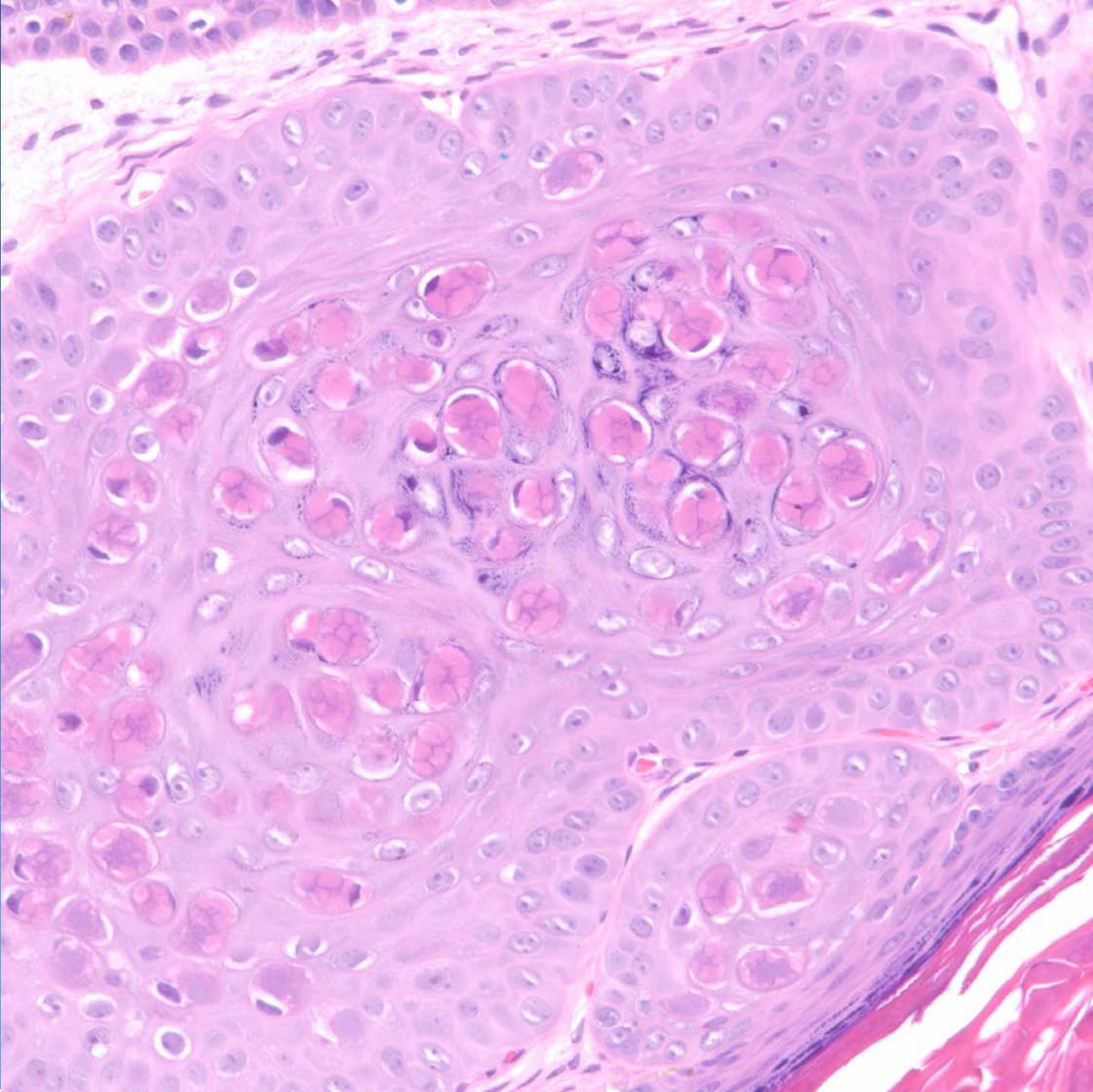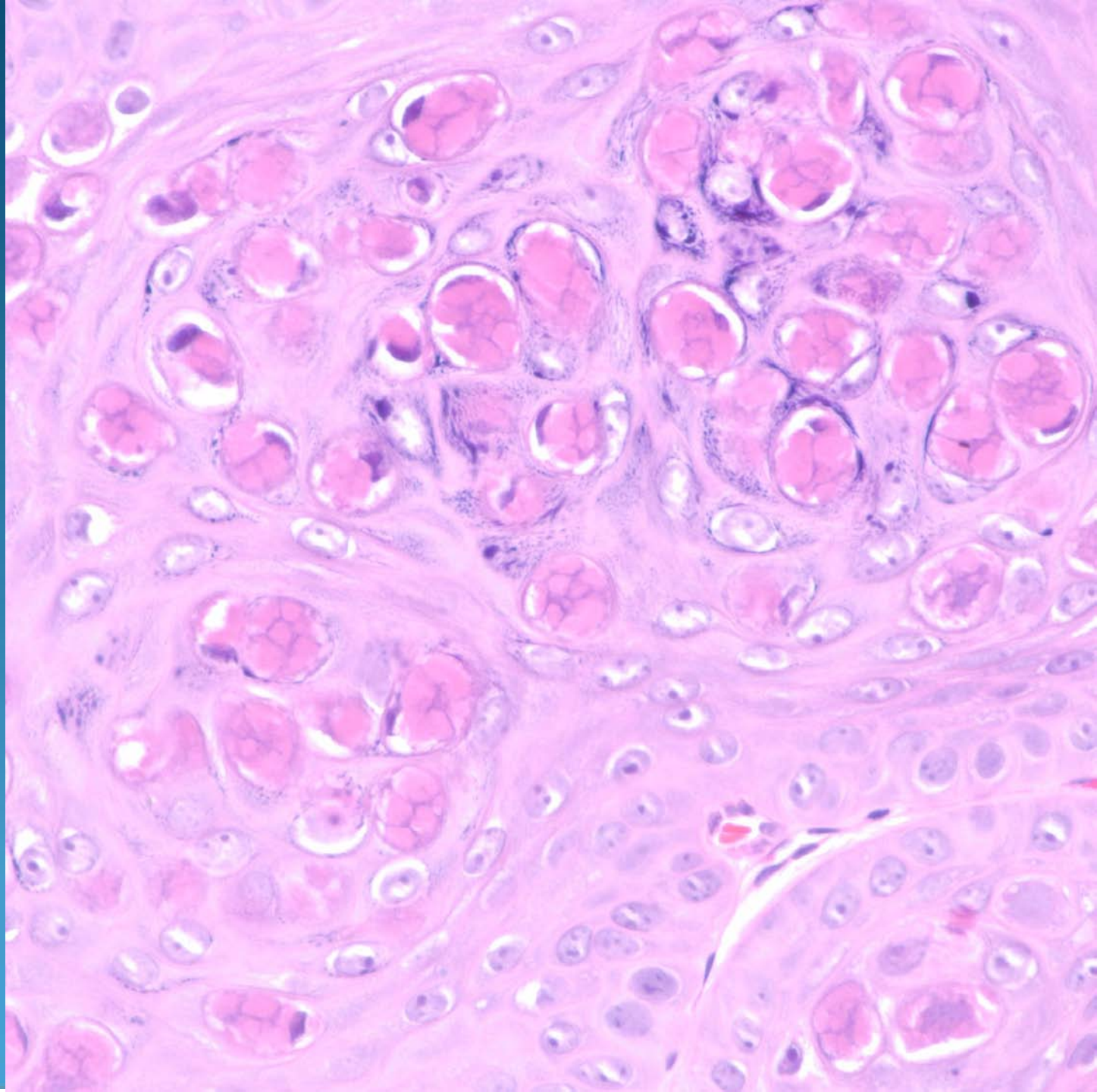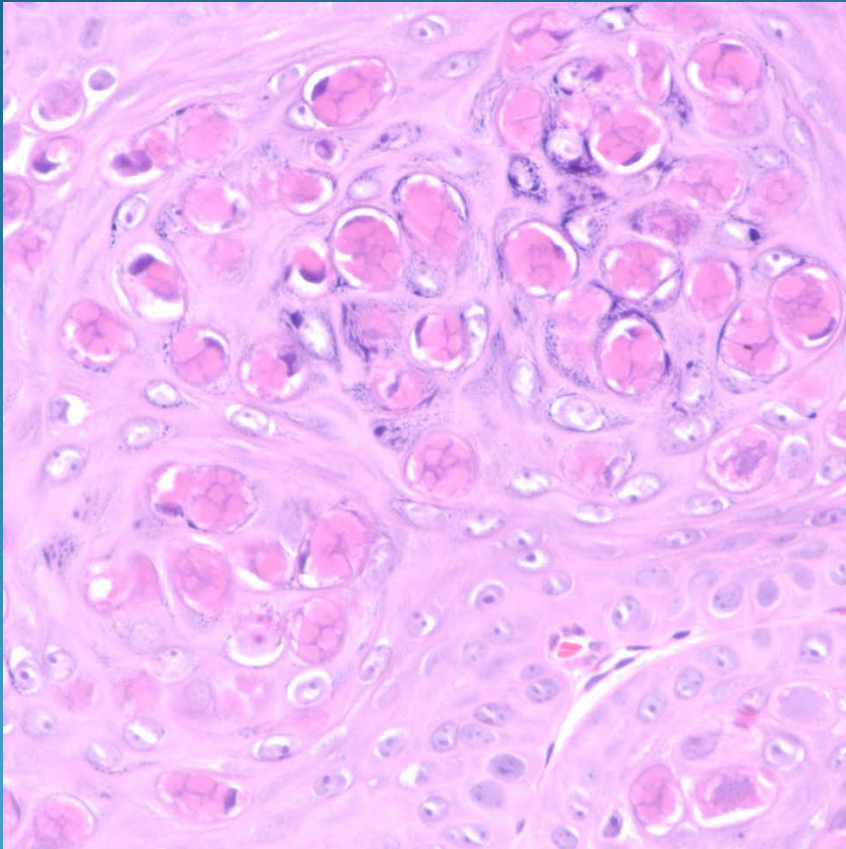


Molluscum Contagiosum

Pearls



- Verruciform or elevated epidermal changes
- Look for characteristic eosinophilic viral inclusion bodies
- Beware! Some cases may show a ruptured folliculitis or granulomas, obscuring the viral cytopathic changes