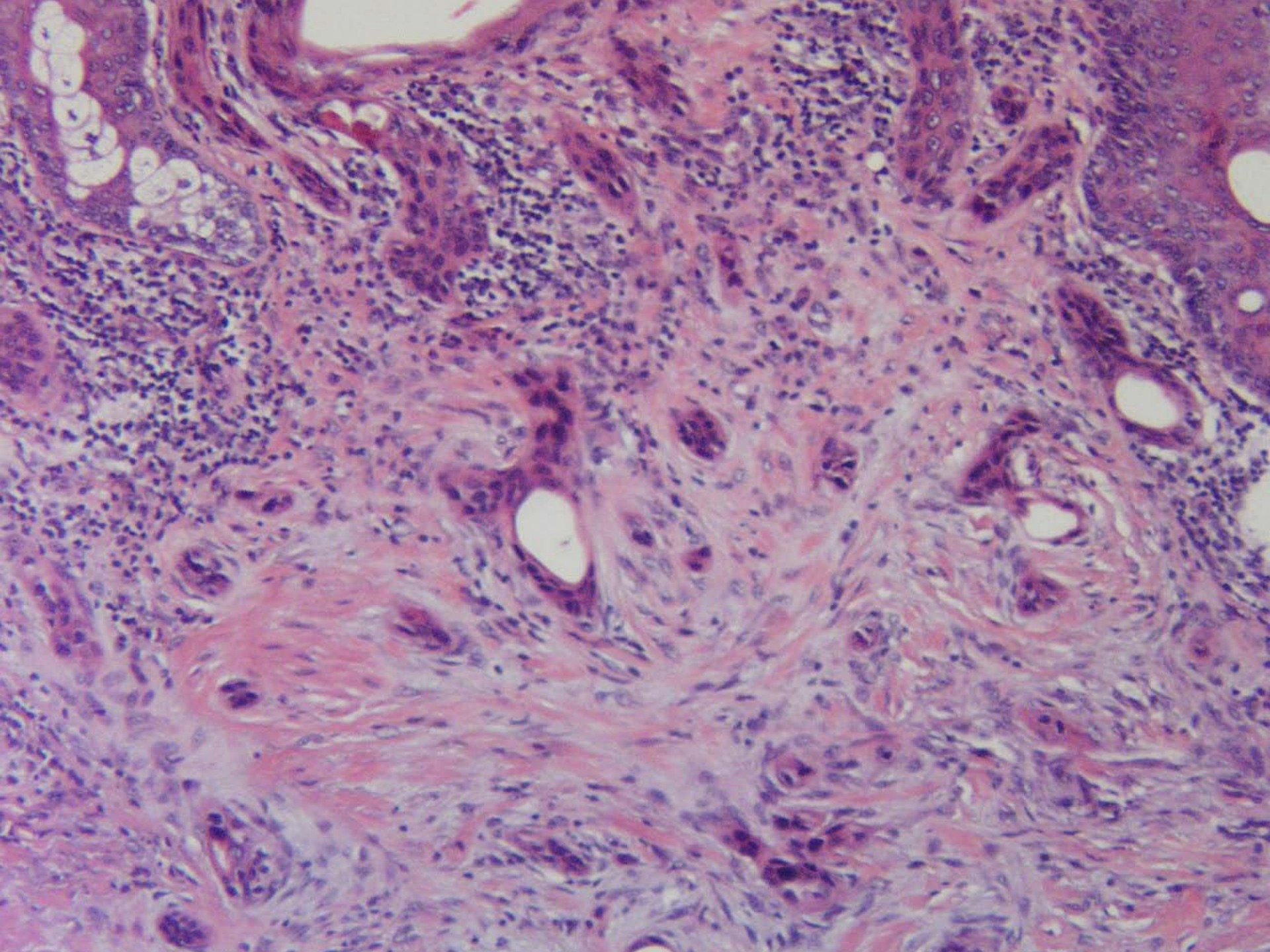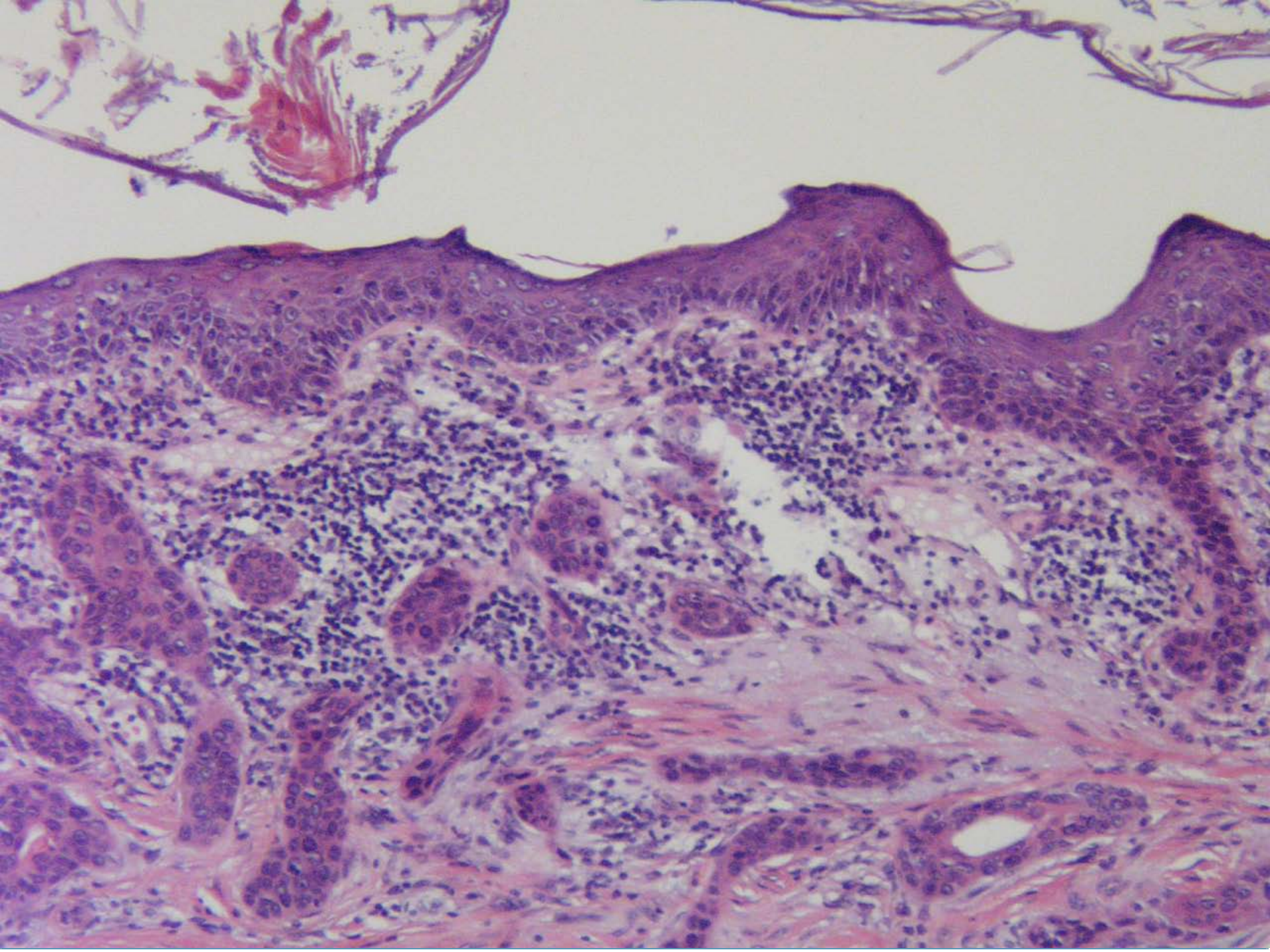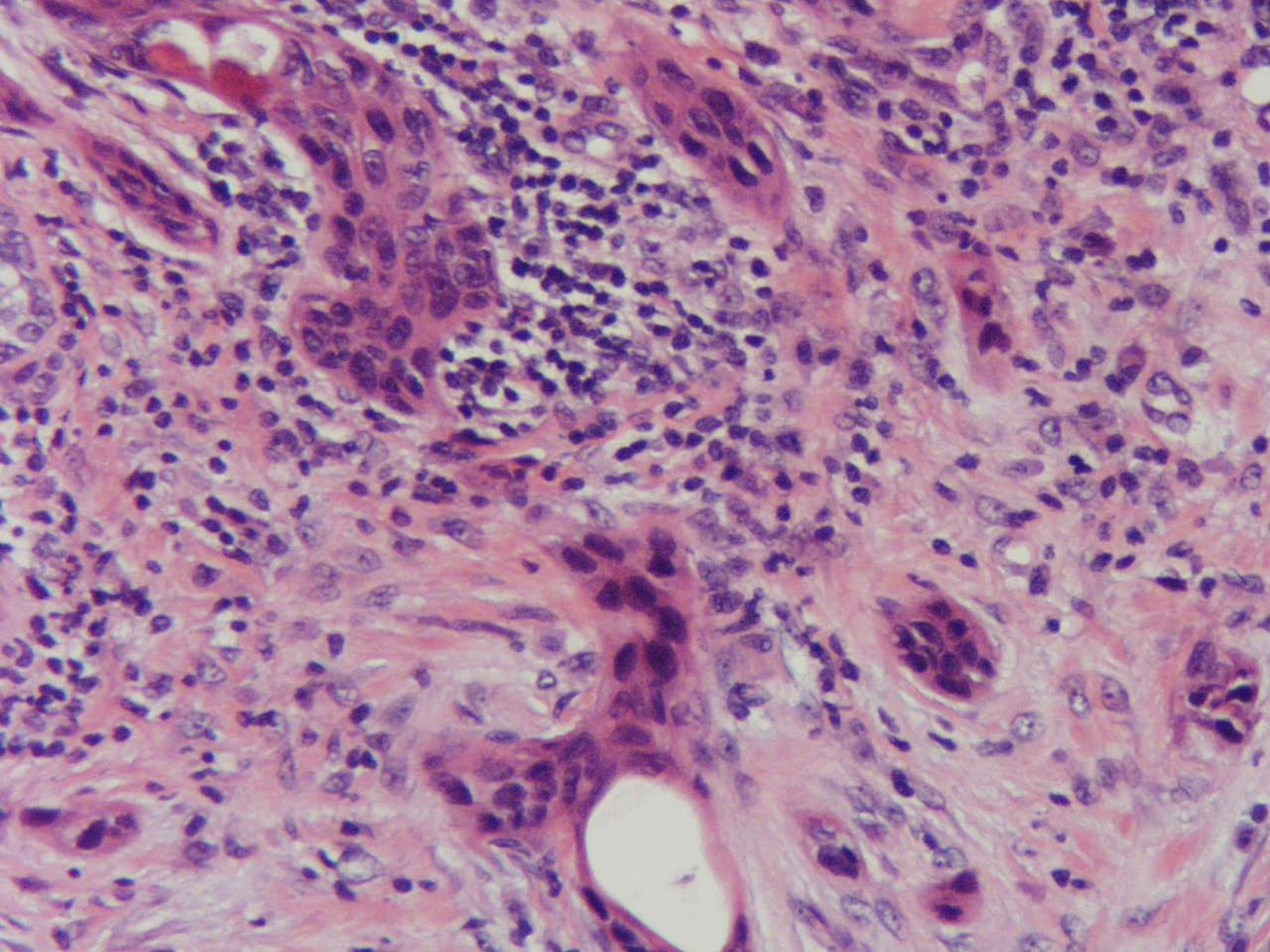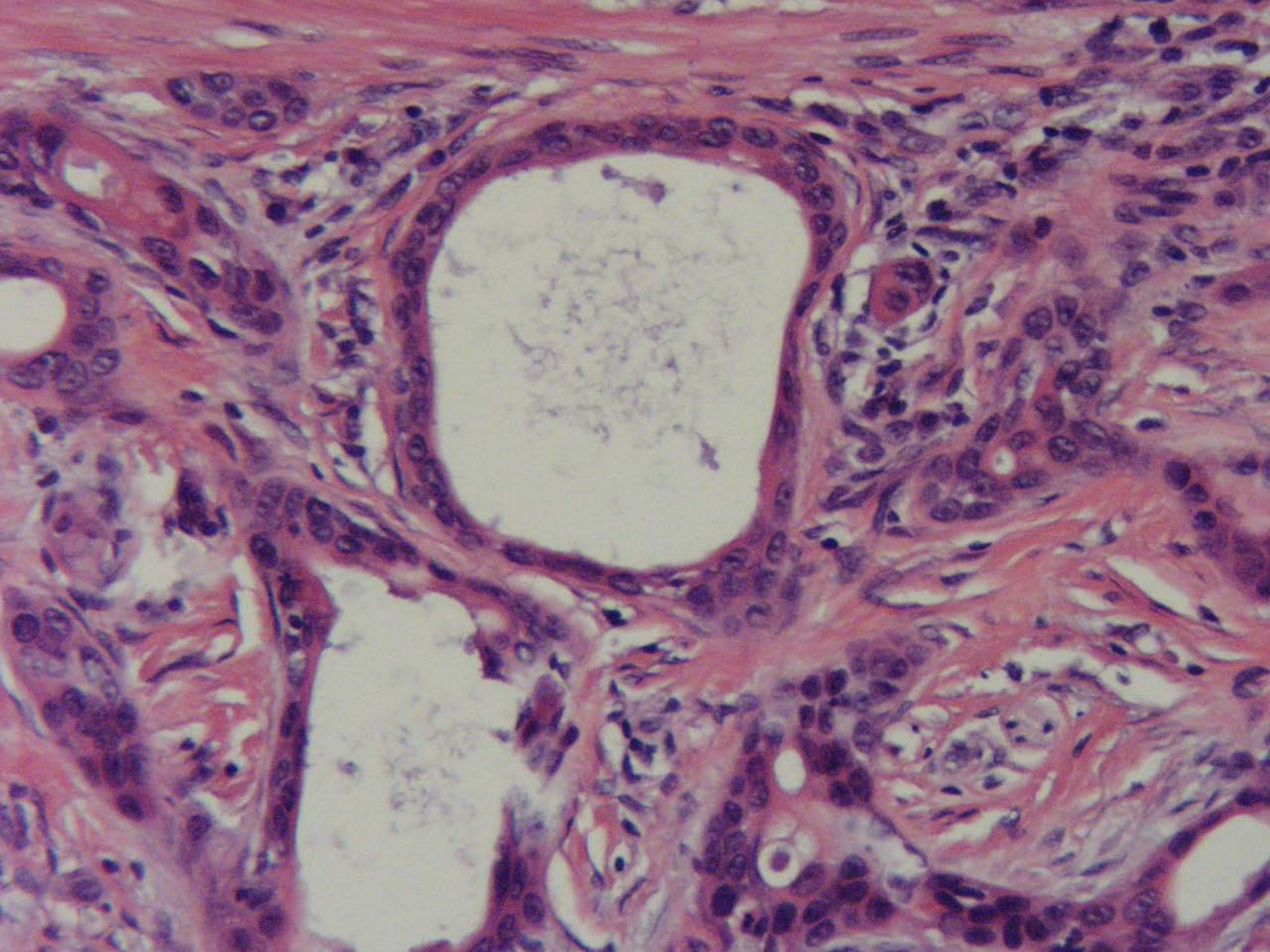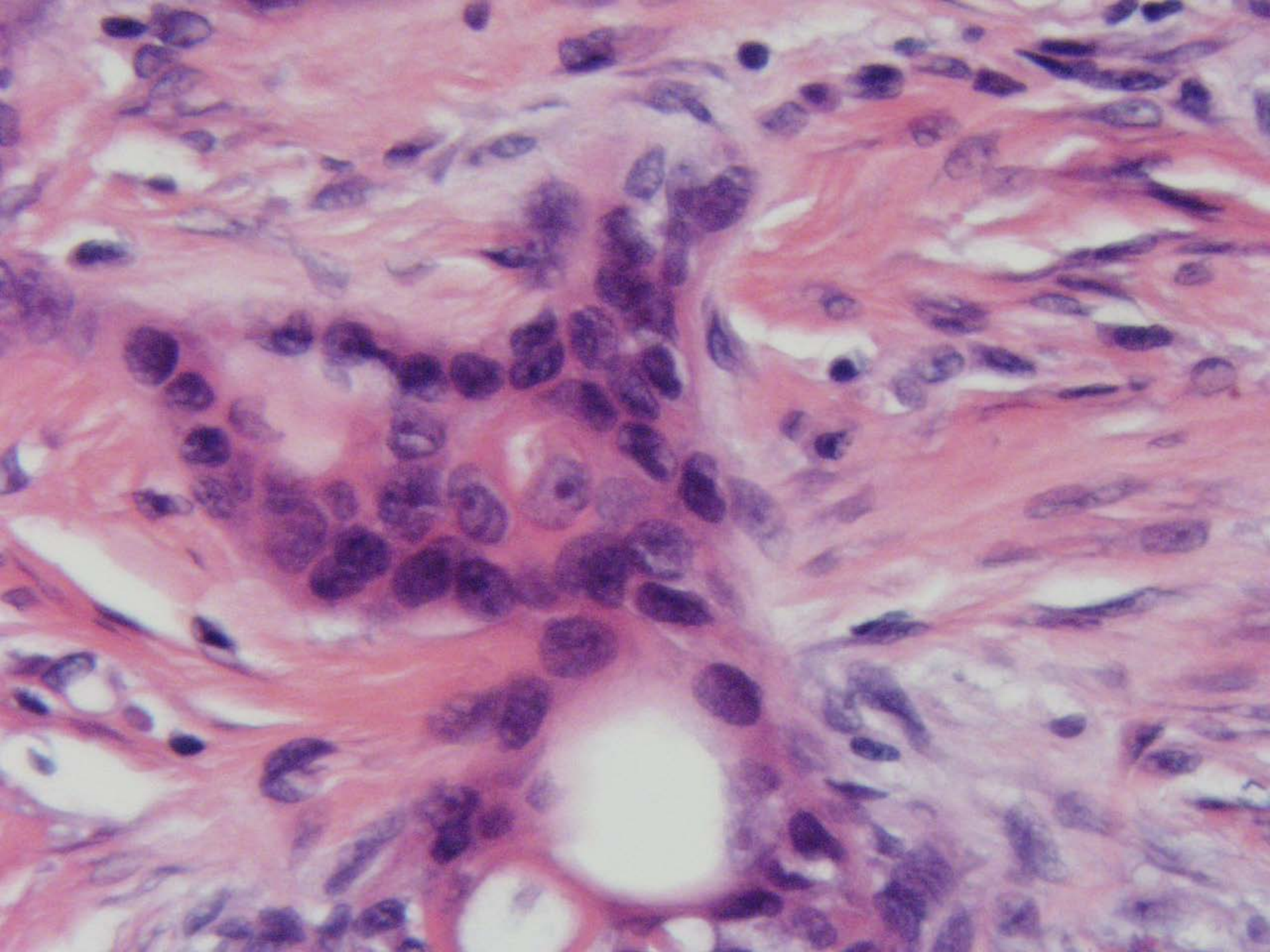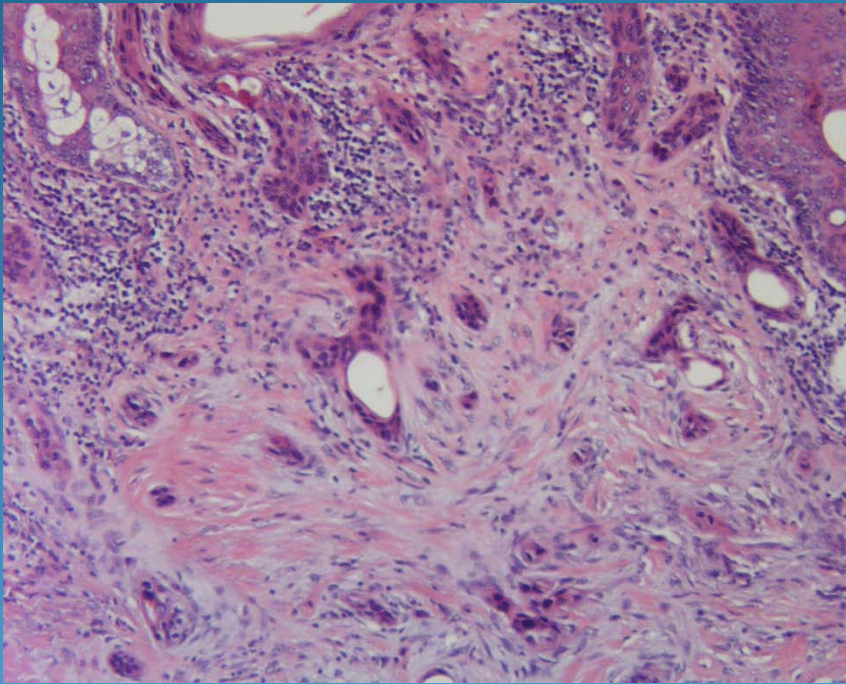


Microcystic Adnexal Carcinoma/ Sclerosing Sweat Duct Carcinoma

Pearls



- Syringoma-like horn cysts extending deep into dermis
- Minimal atypia
- Not basaloid, resembles metastatic adenocarcinoma