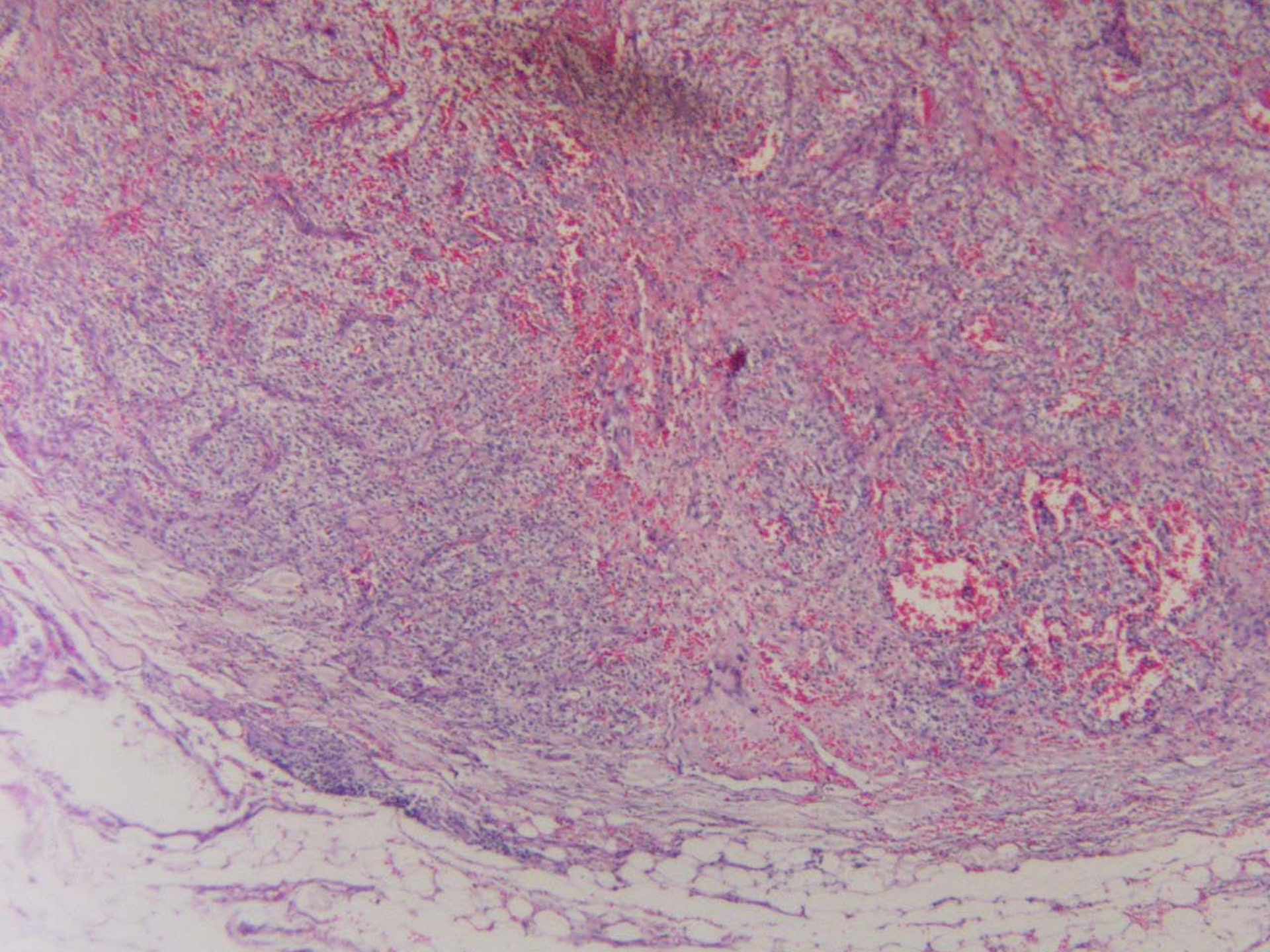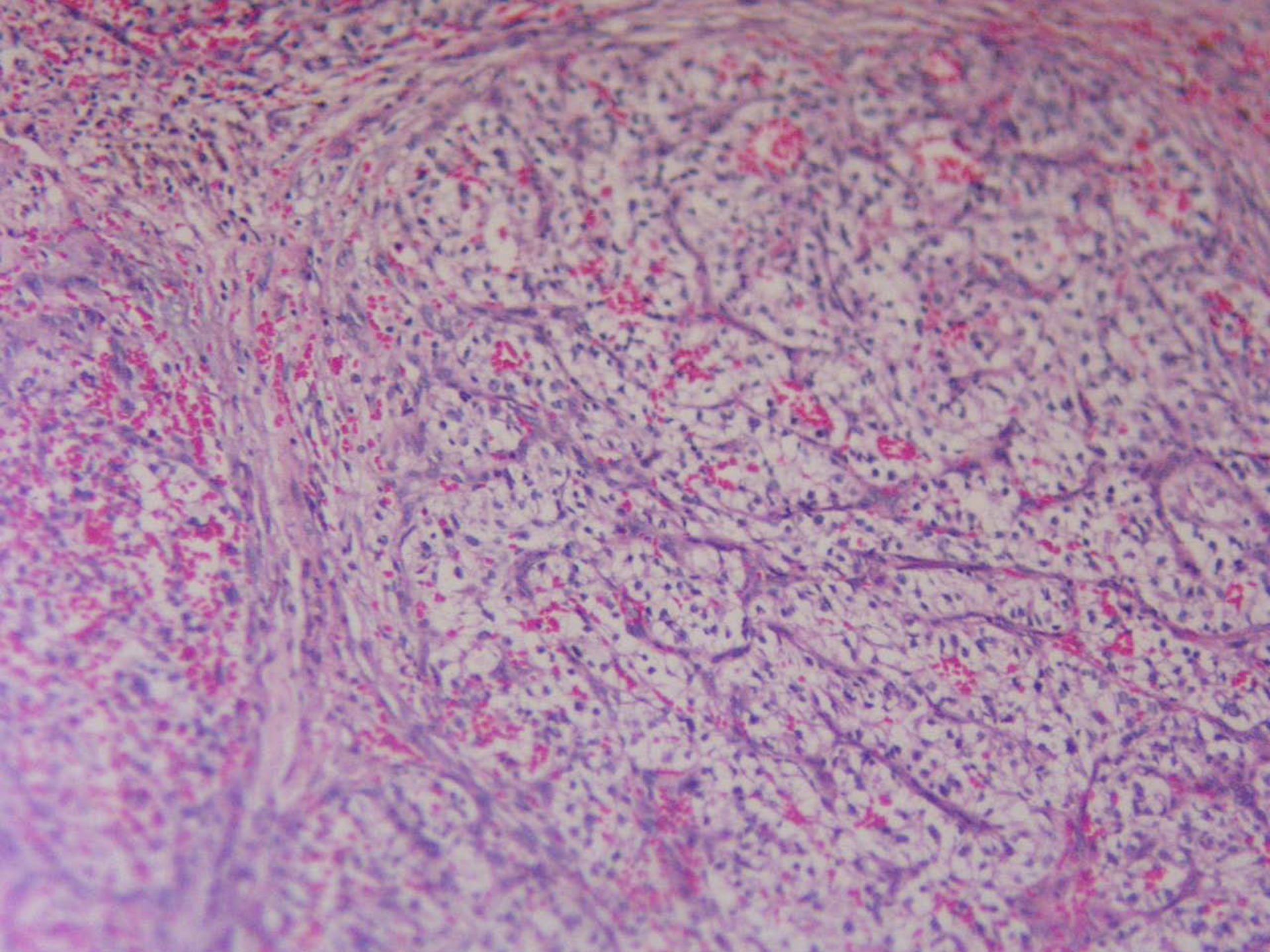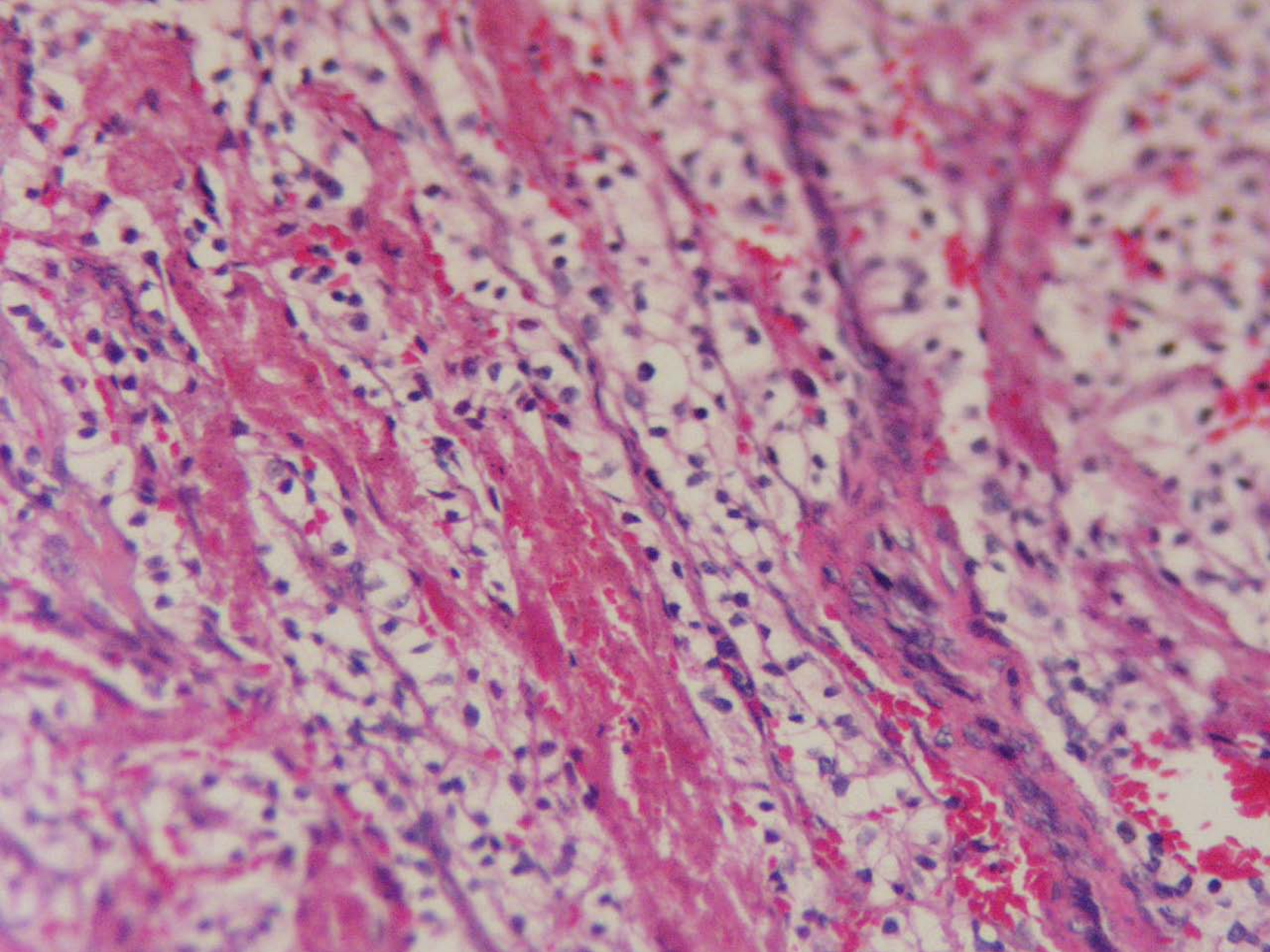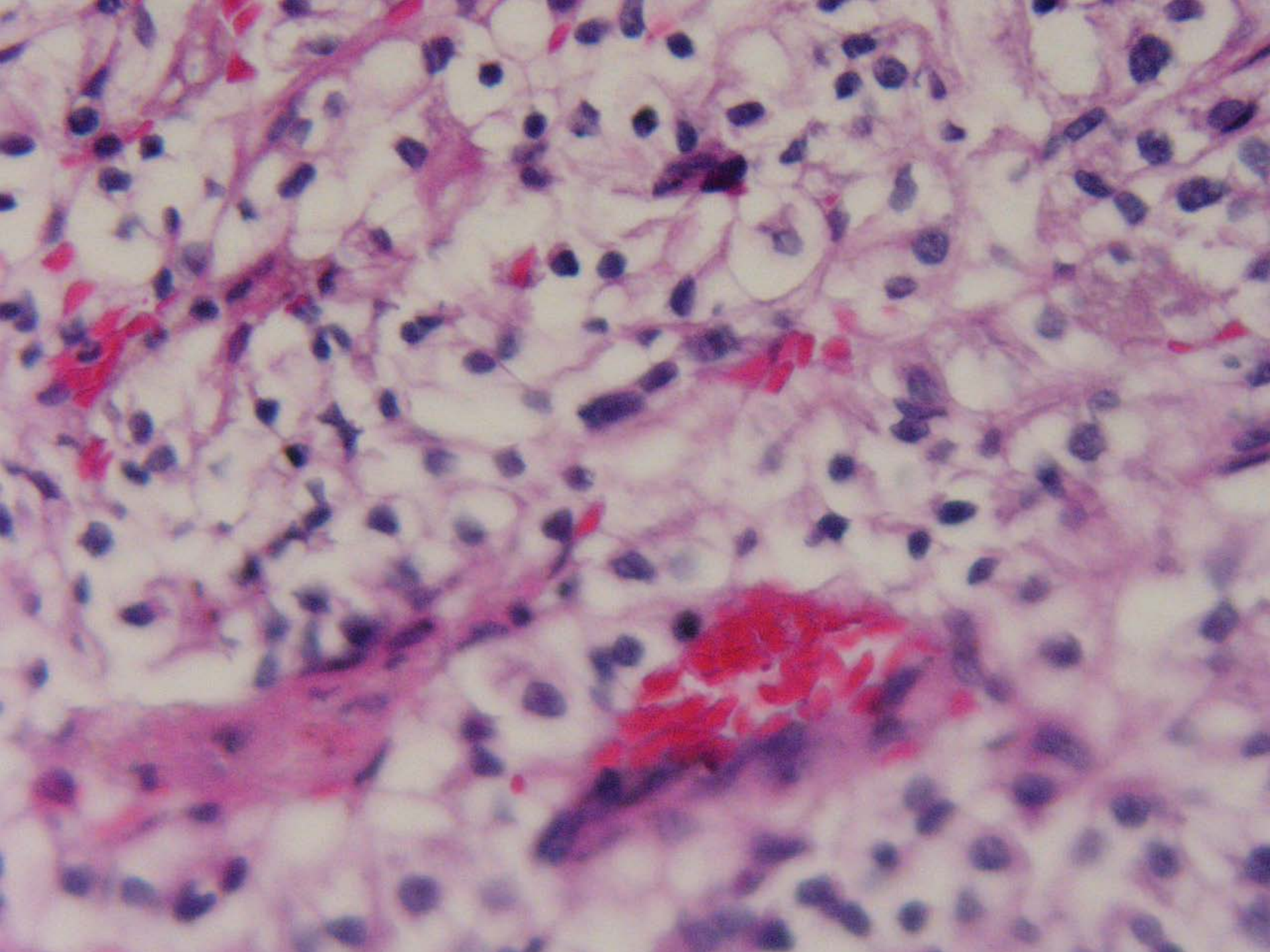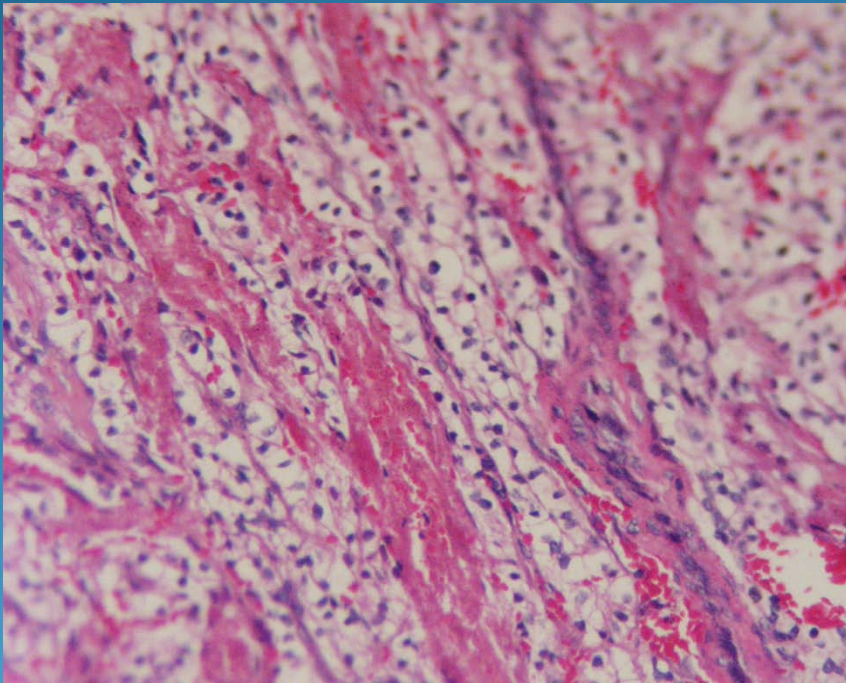


Metastatic Renal Cell Carcinoma

Pearls



- Looks like nodular hidradenoma with many blood vessels
- Nests of clear cells surrounding hemorrhage
- Usually mildly atypical, rare to find high grade nuclei