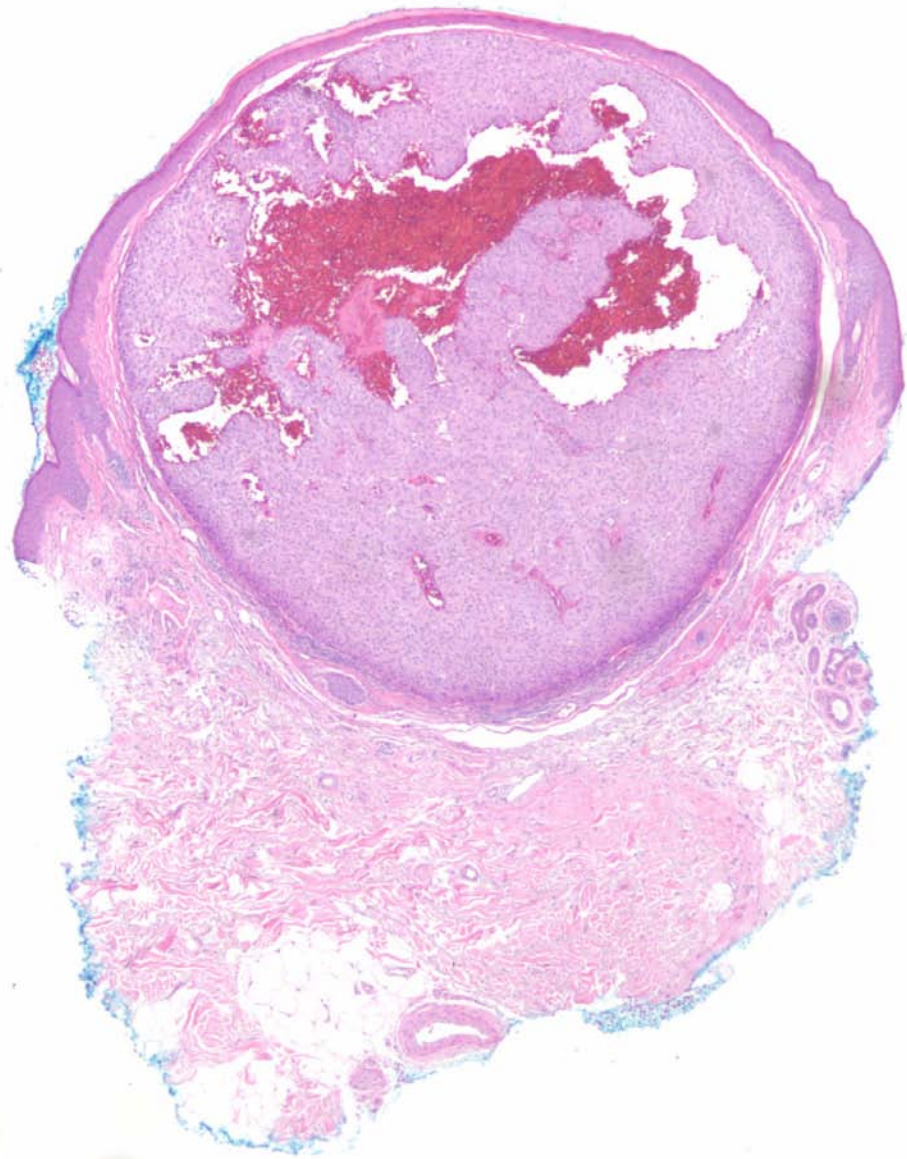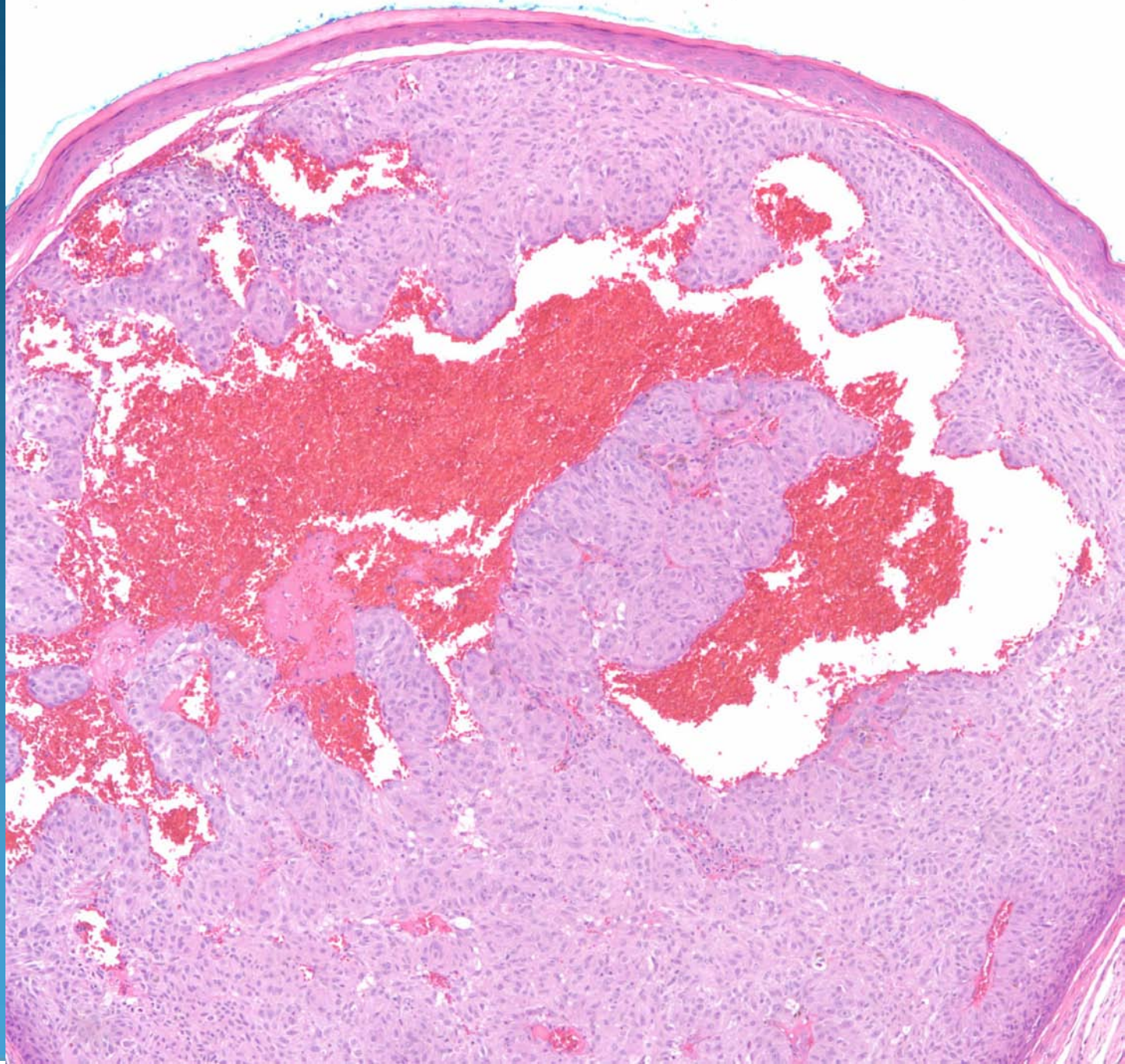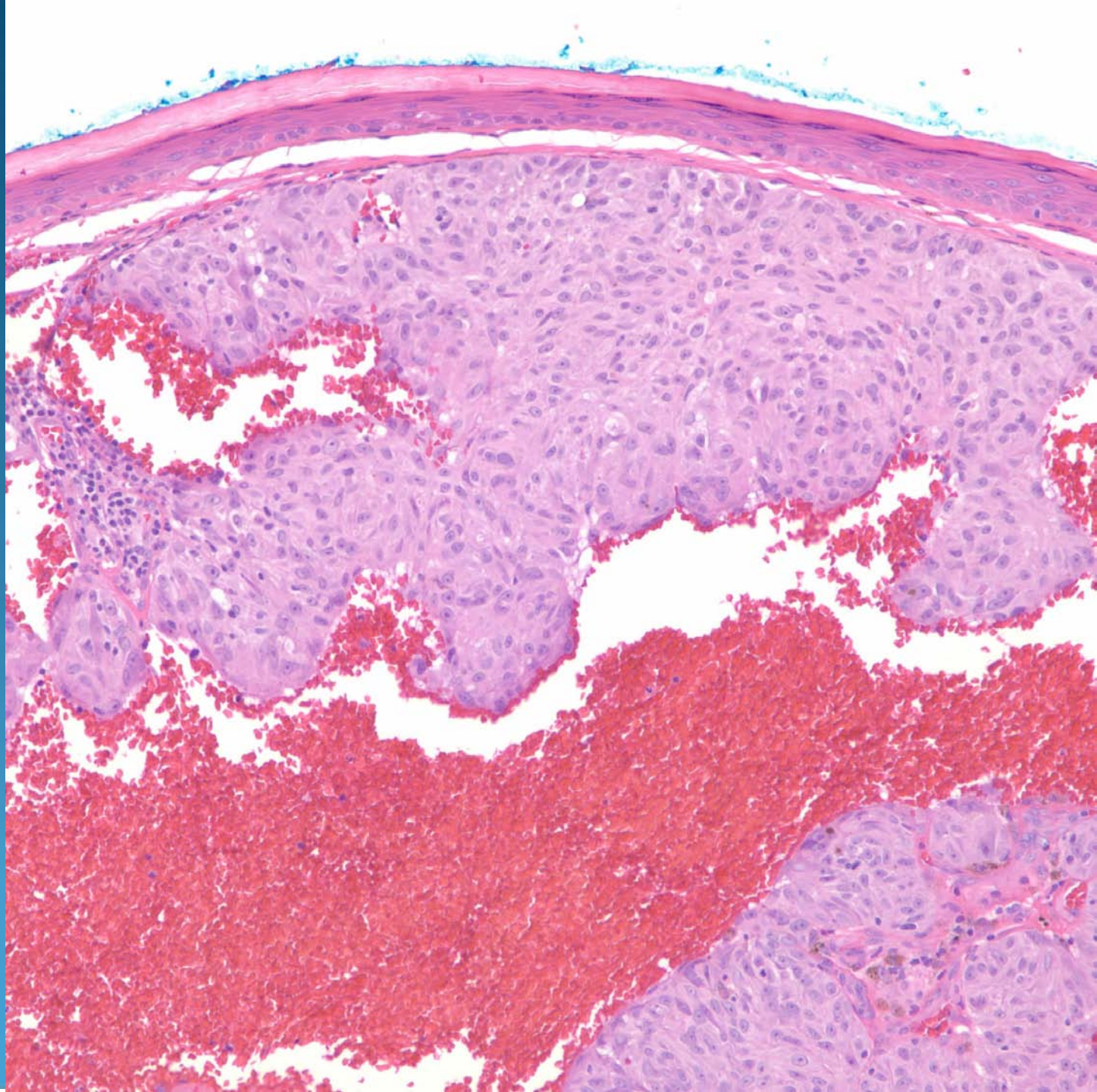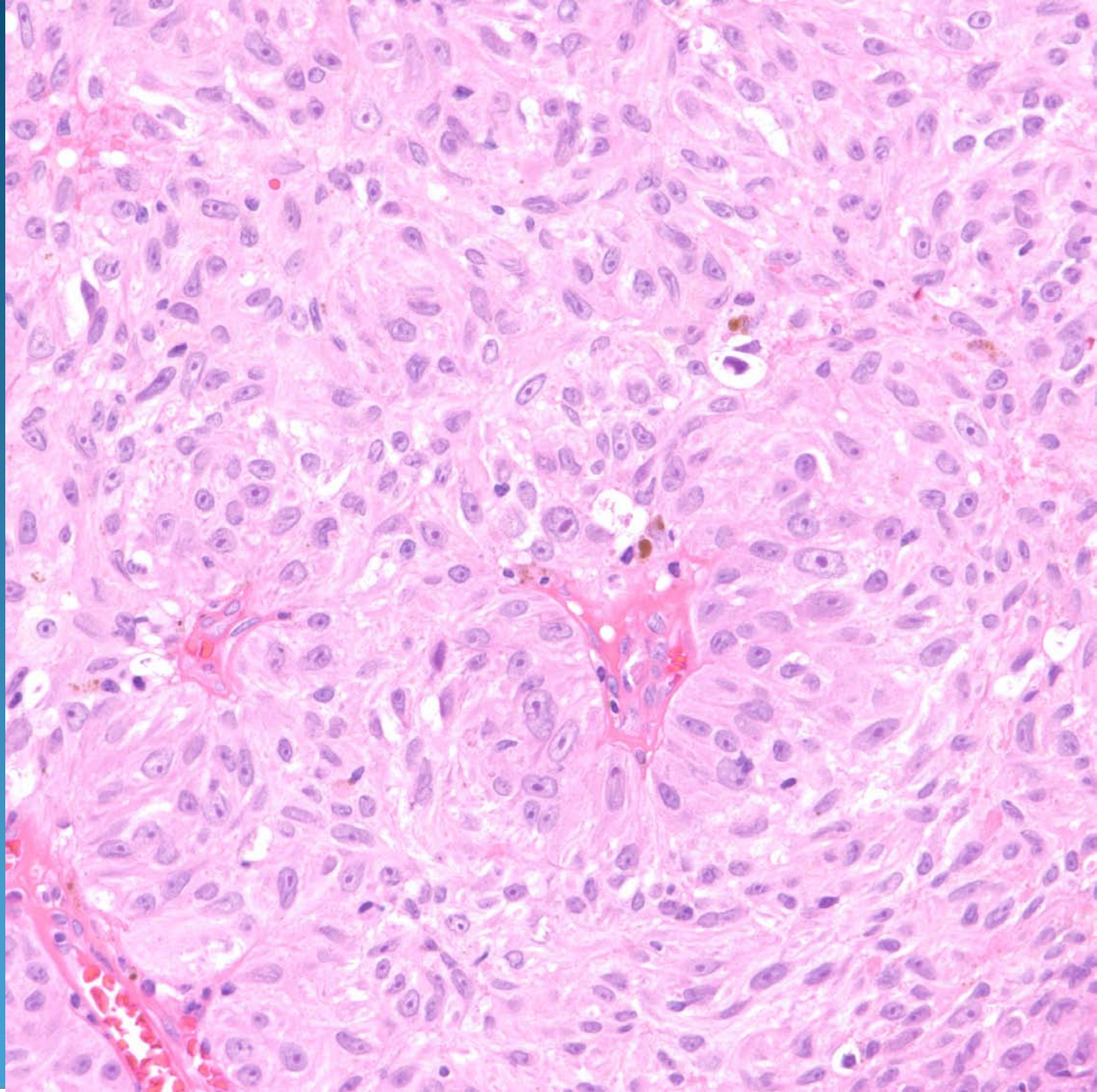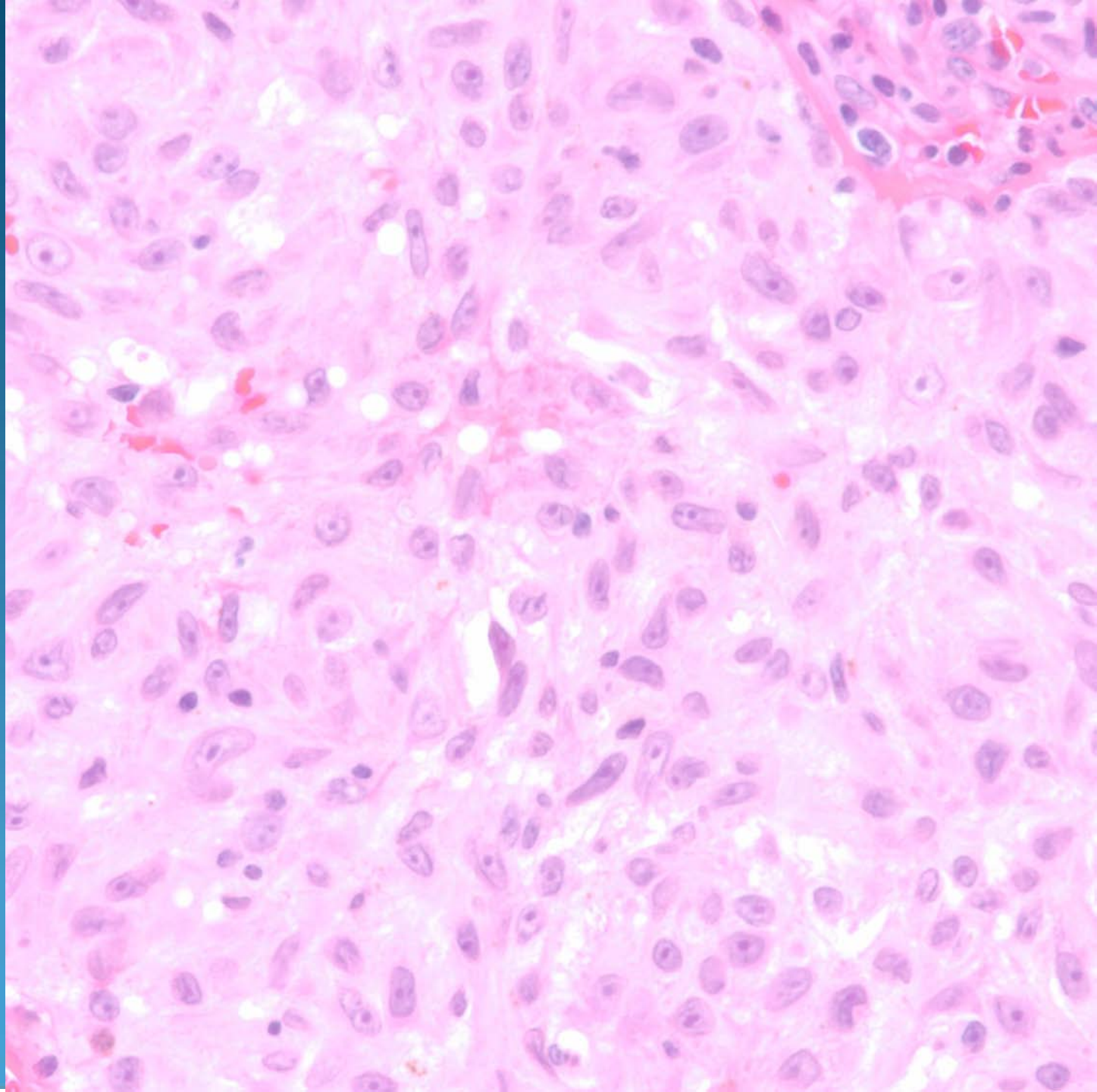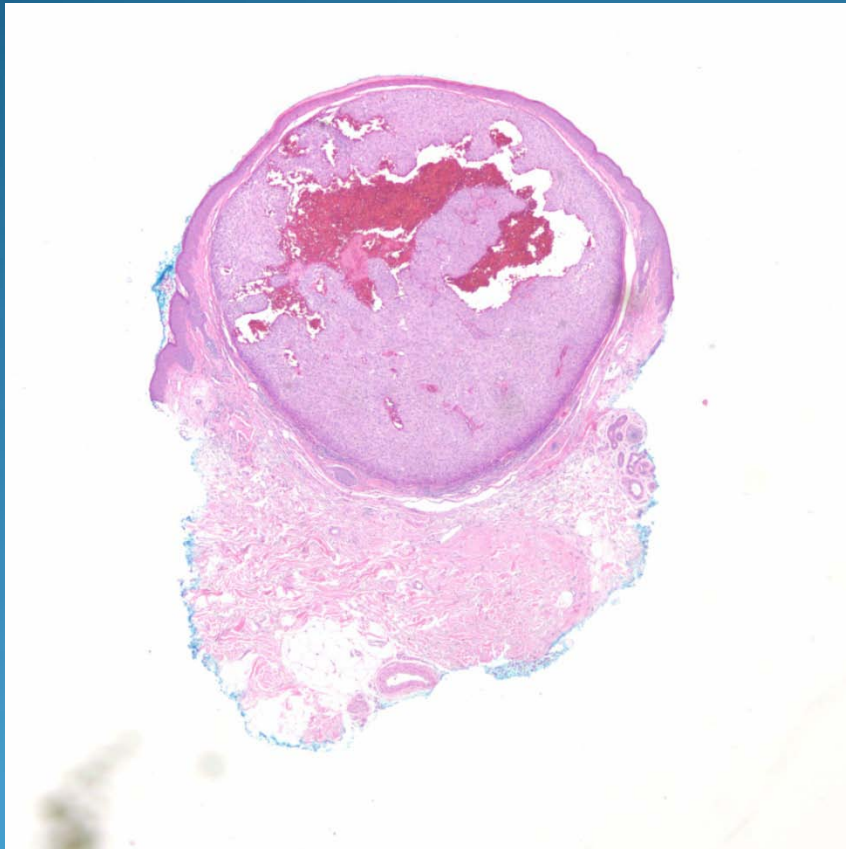


Metastatic Malignant Melanoma

Pearls



- Expansile nodule of malignant melanocytes
- Minimal to absent junctional activity
- Dermal component larger than junctional component
- May need IHC to confirm diagnosis