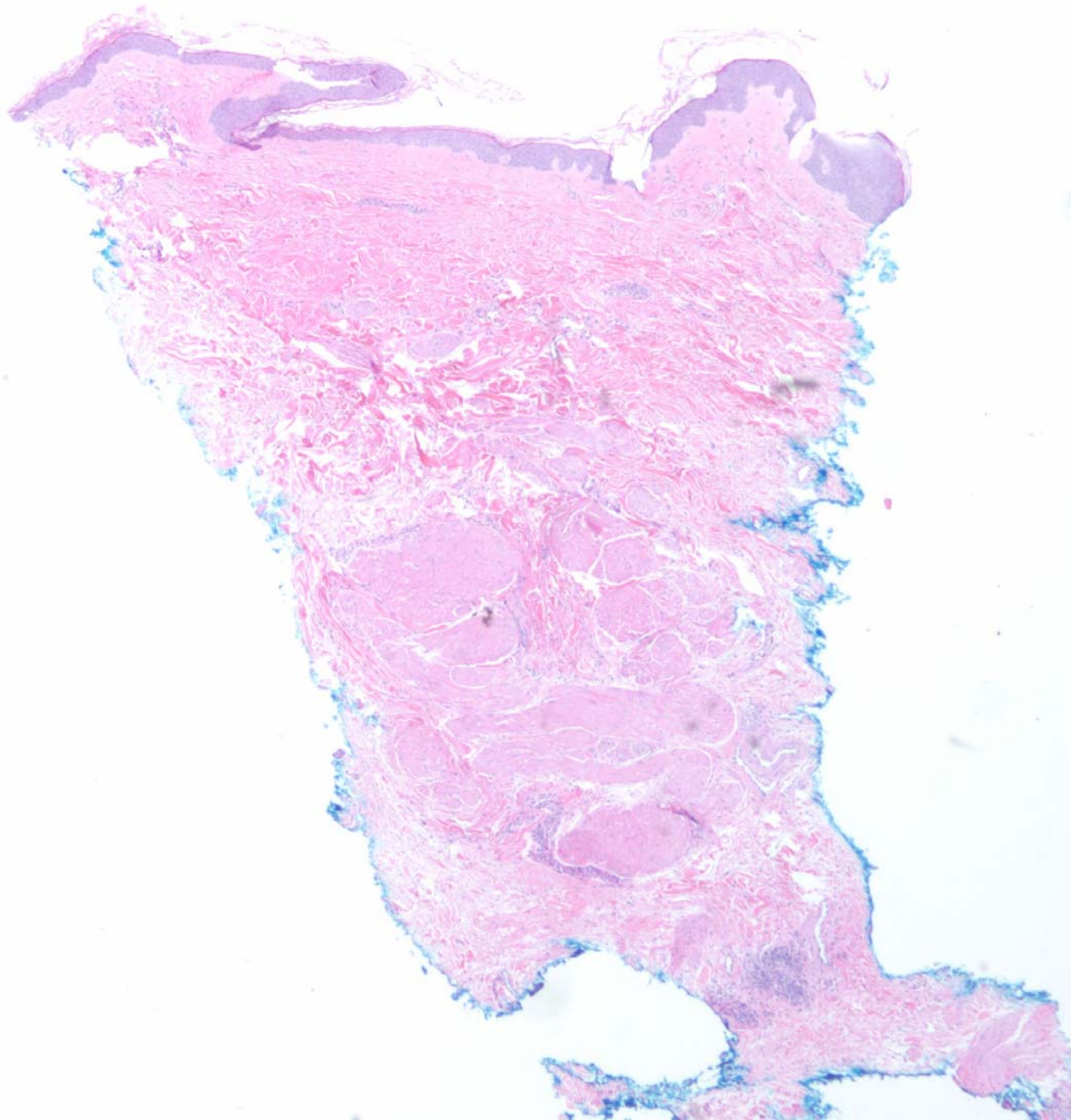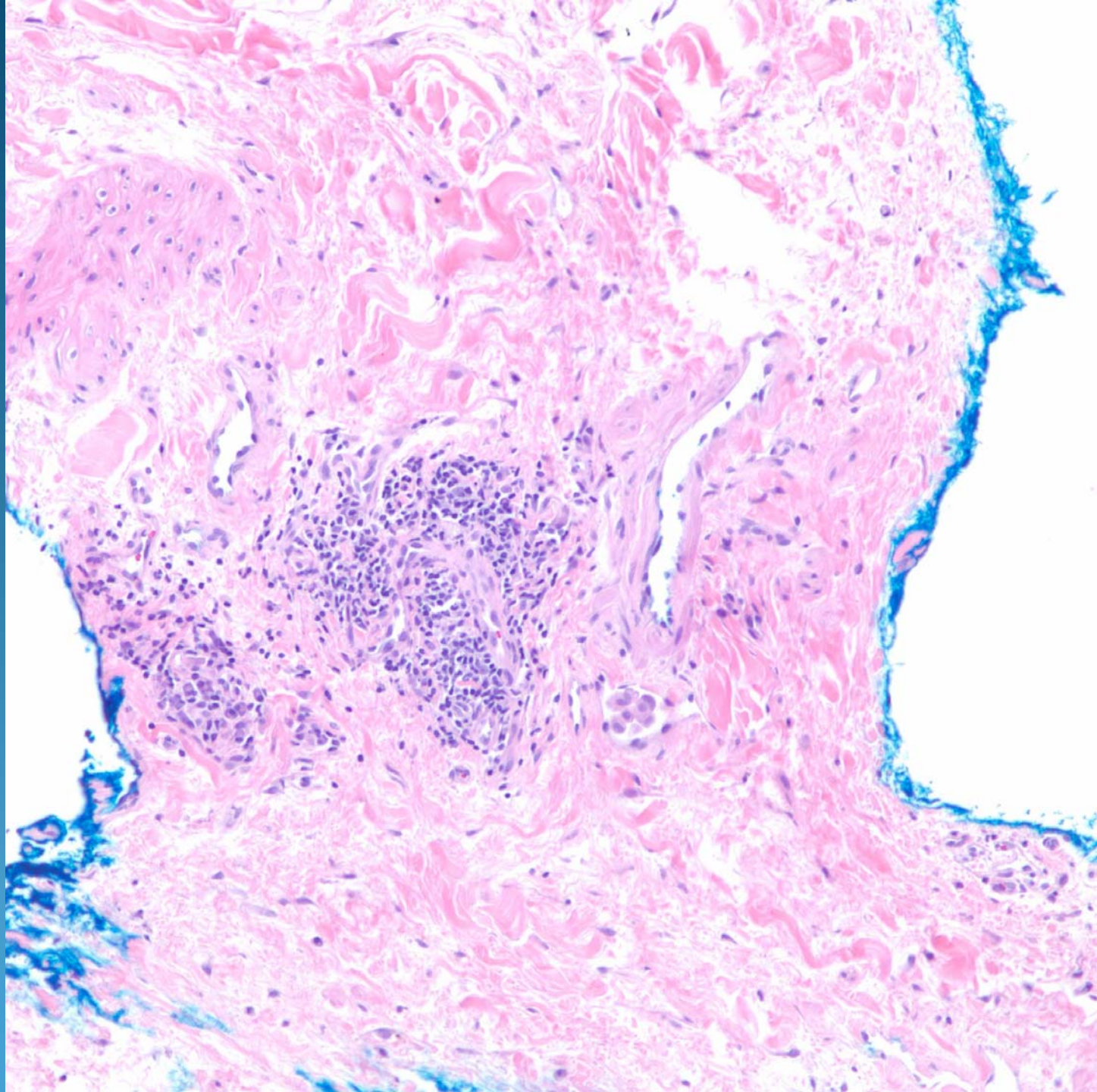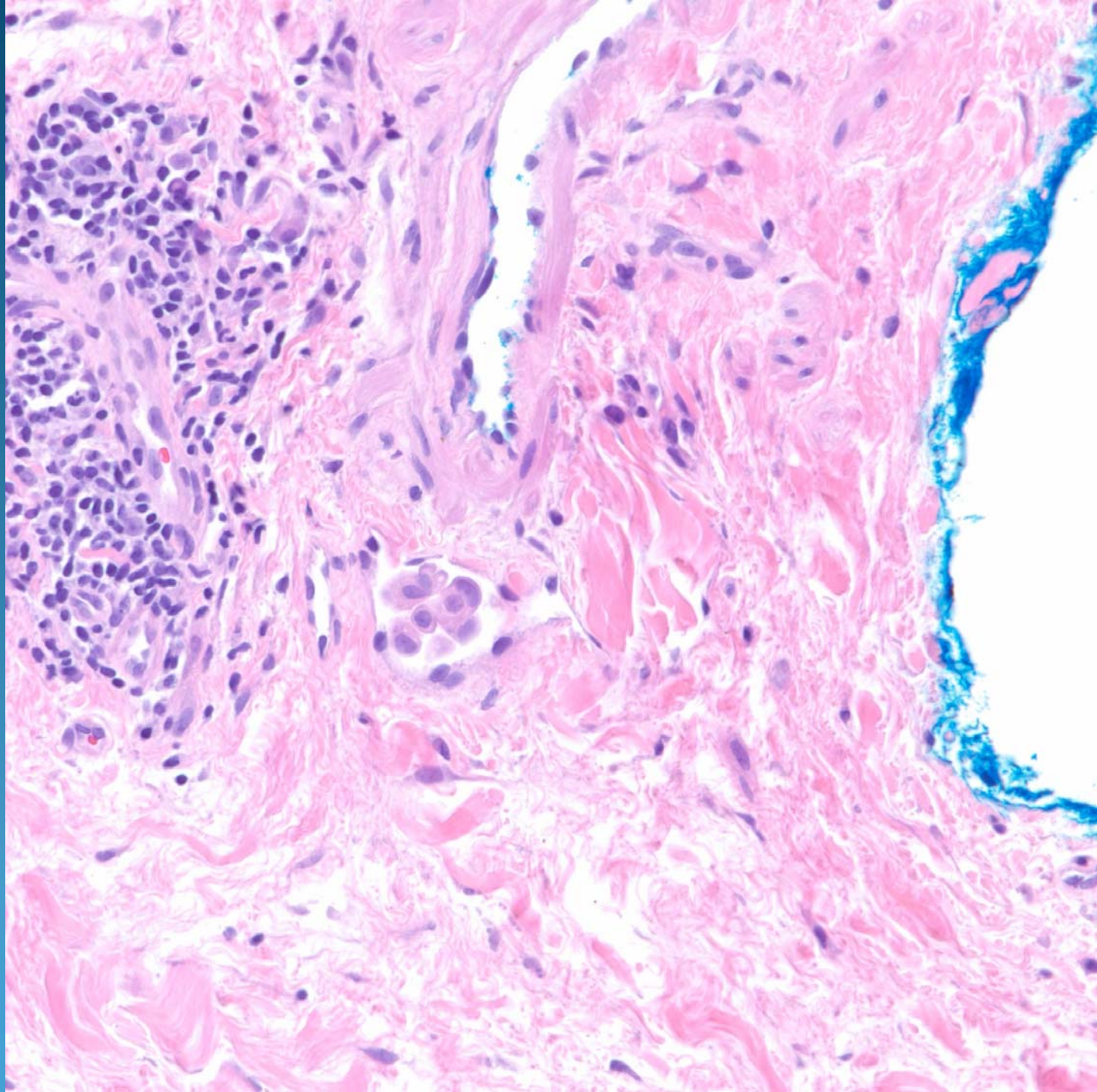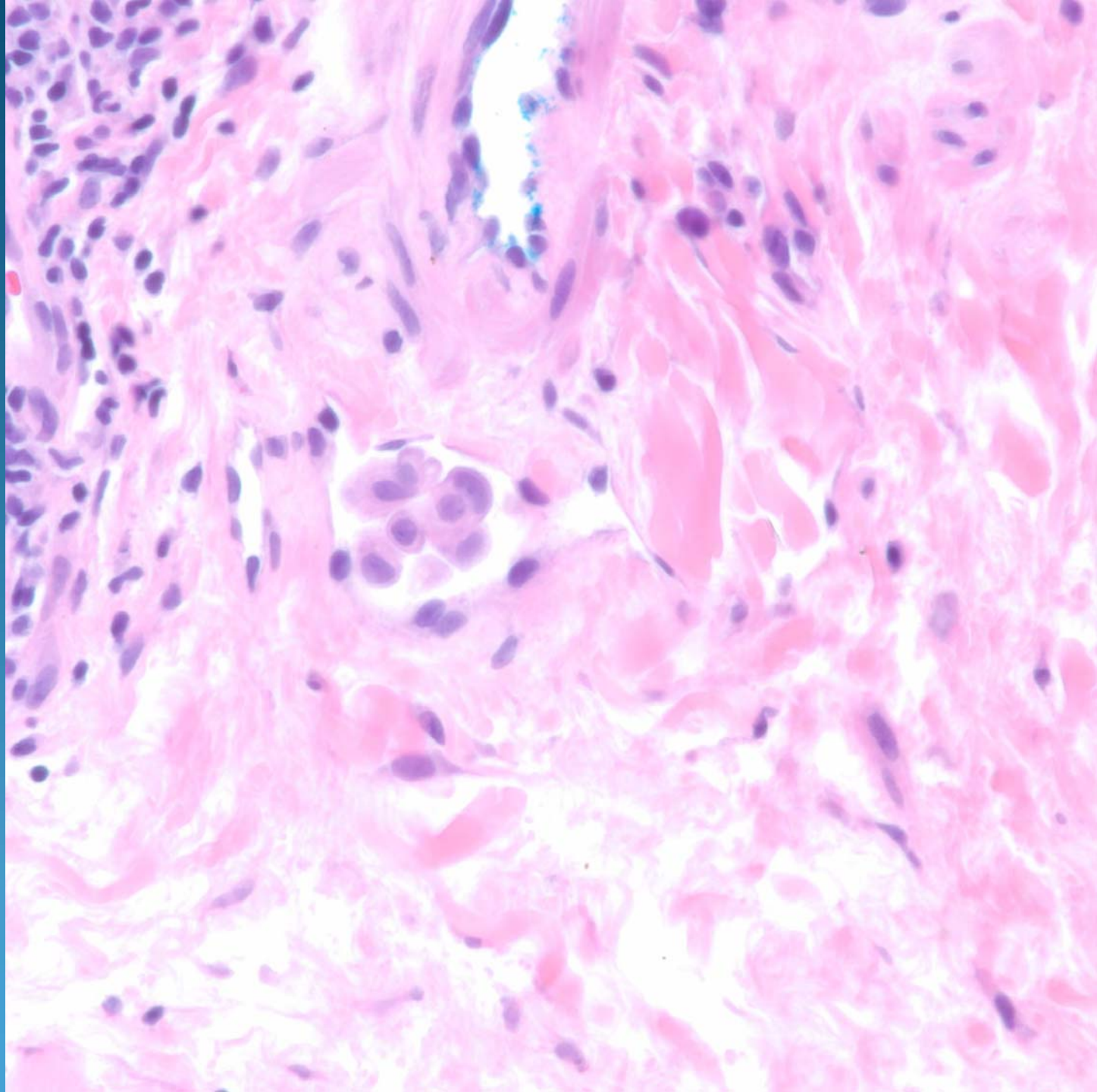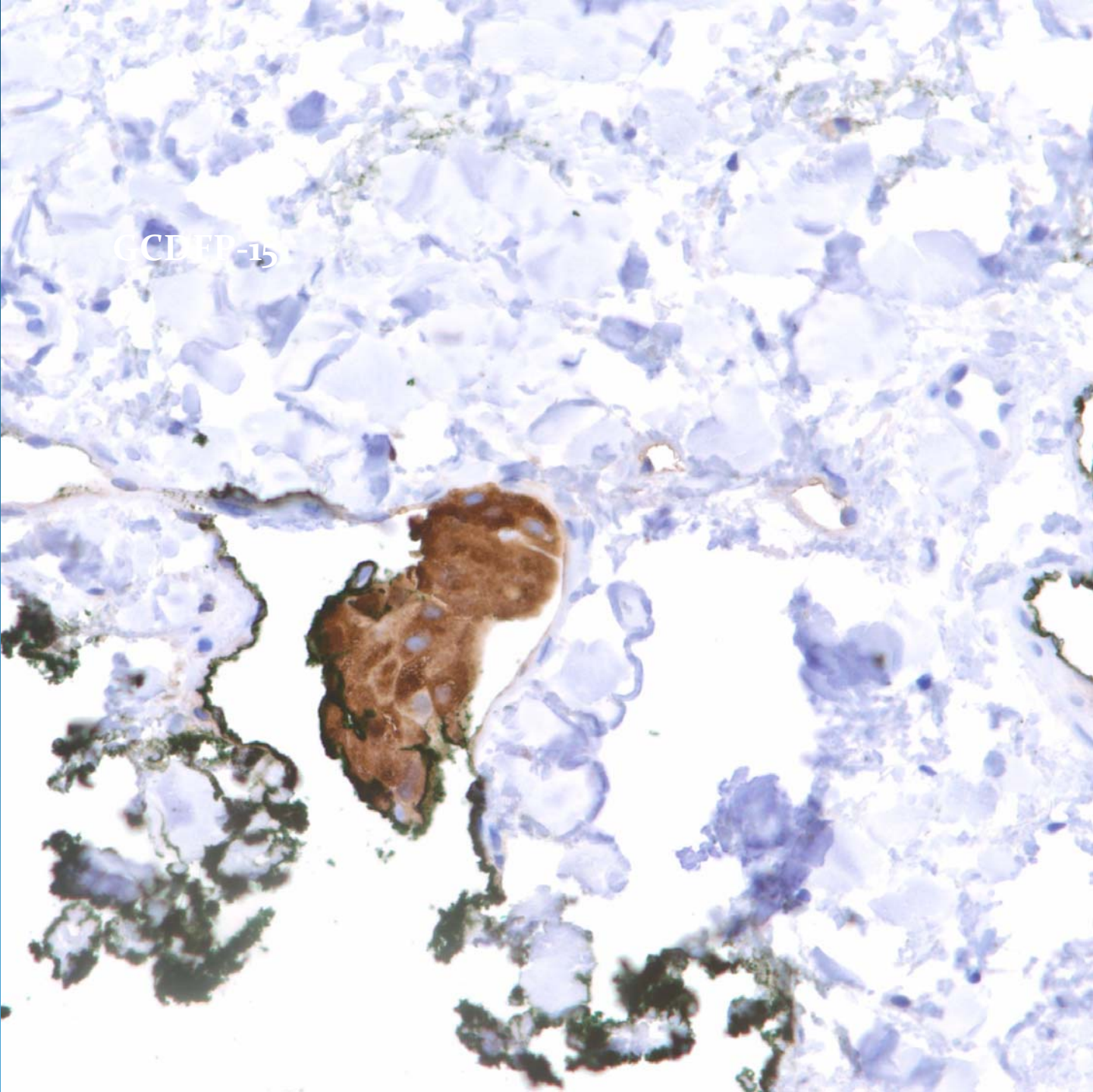
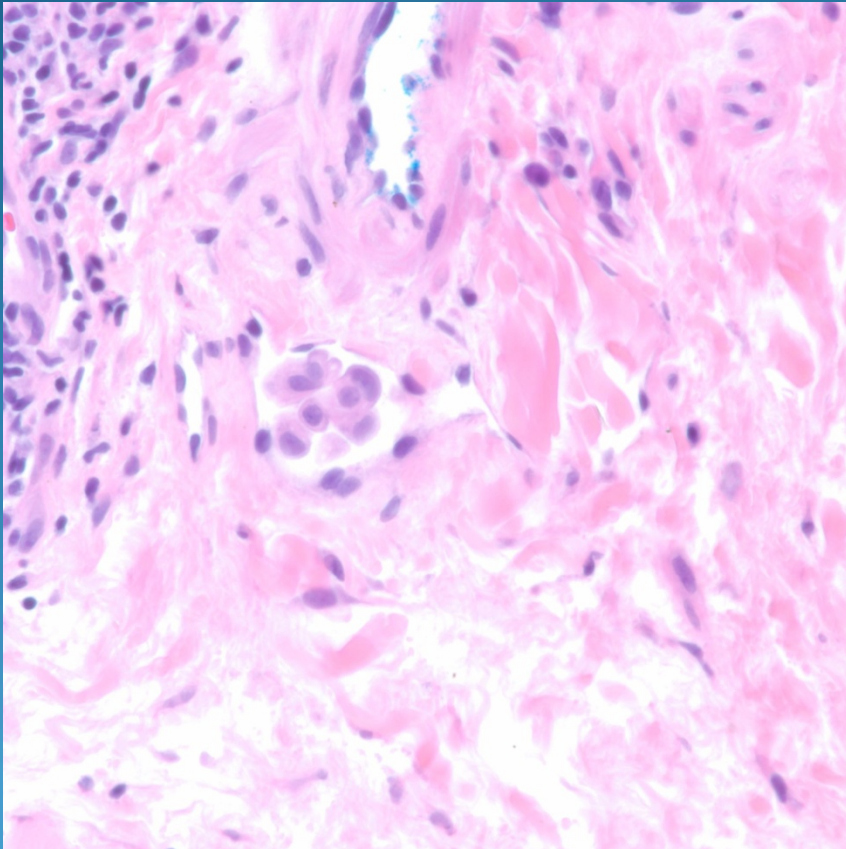


GCEP-15



Metastatic Adenocarcinoma Consistent with Breast Primary

Pearls



- Metastatic disease may occasionally be intravascular
- May need IHC to confirm