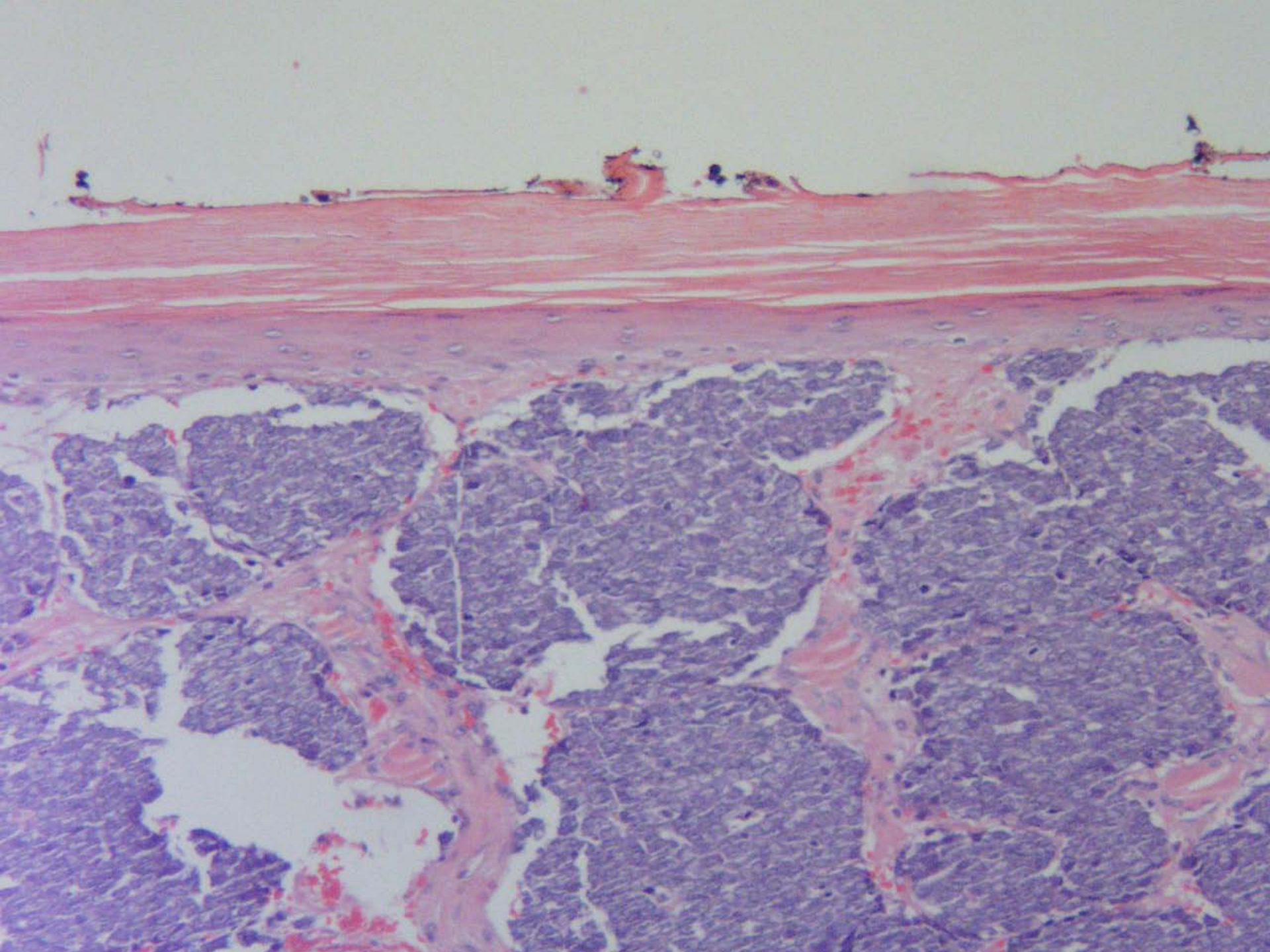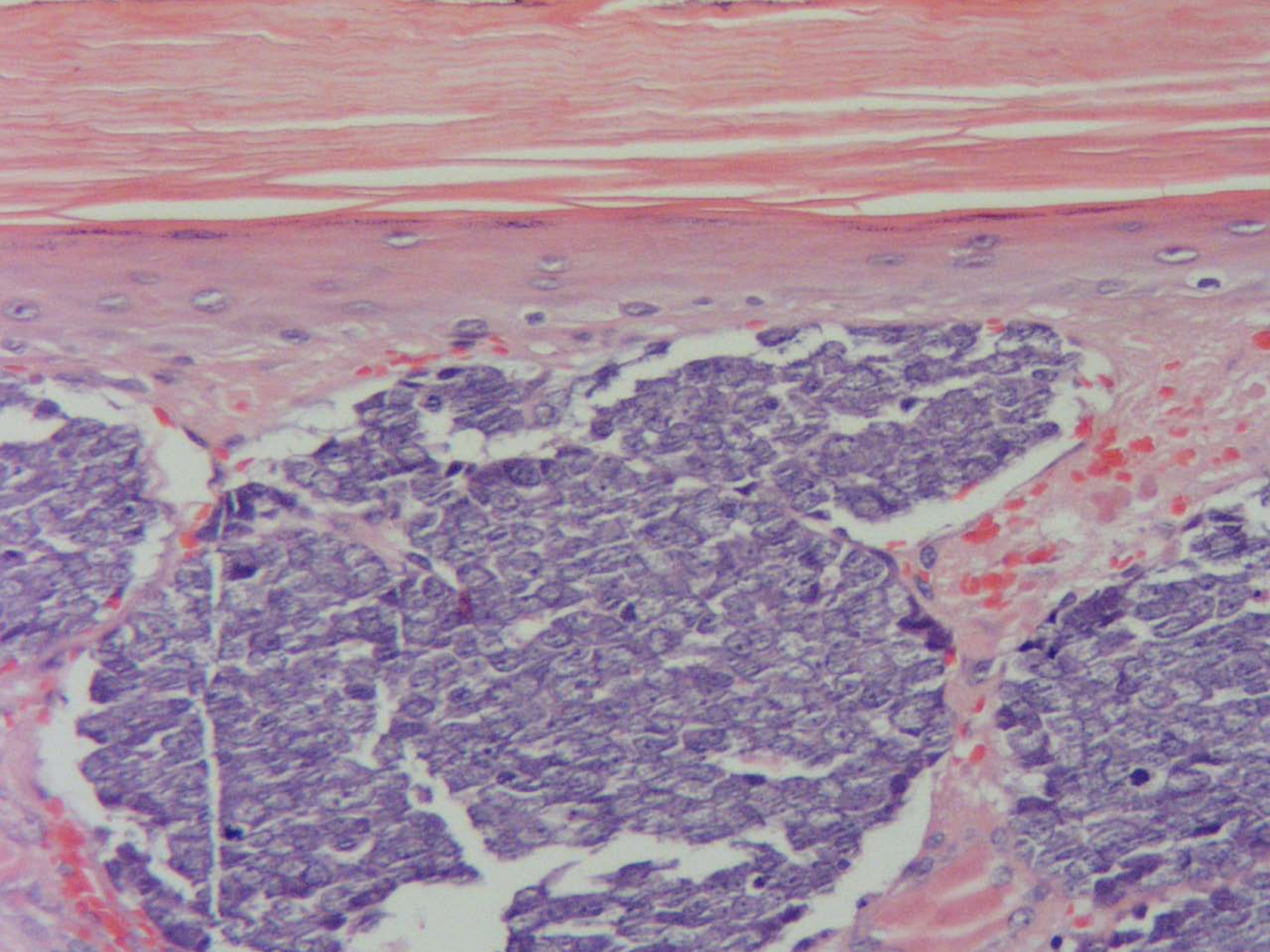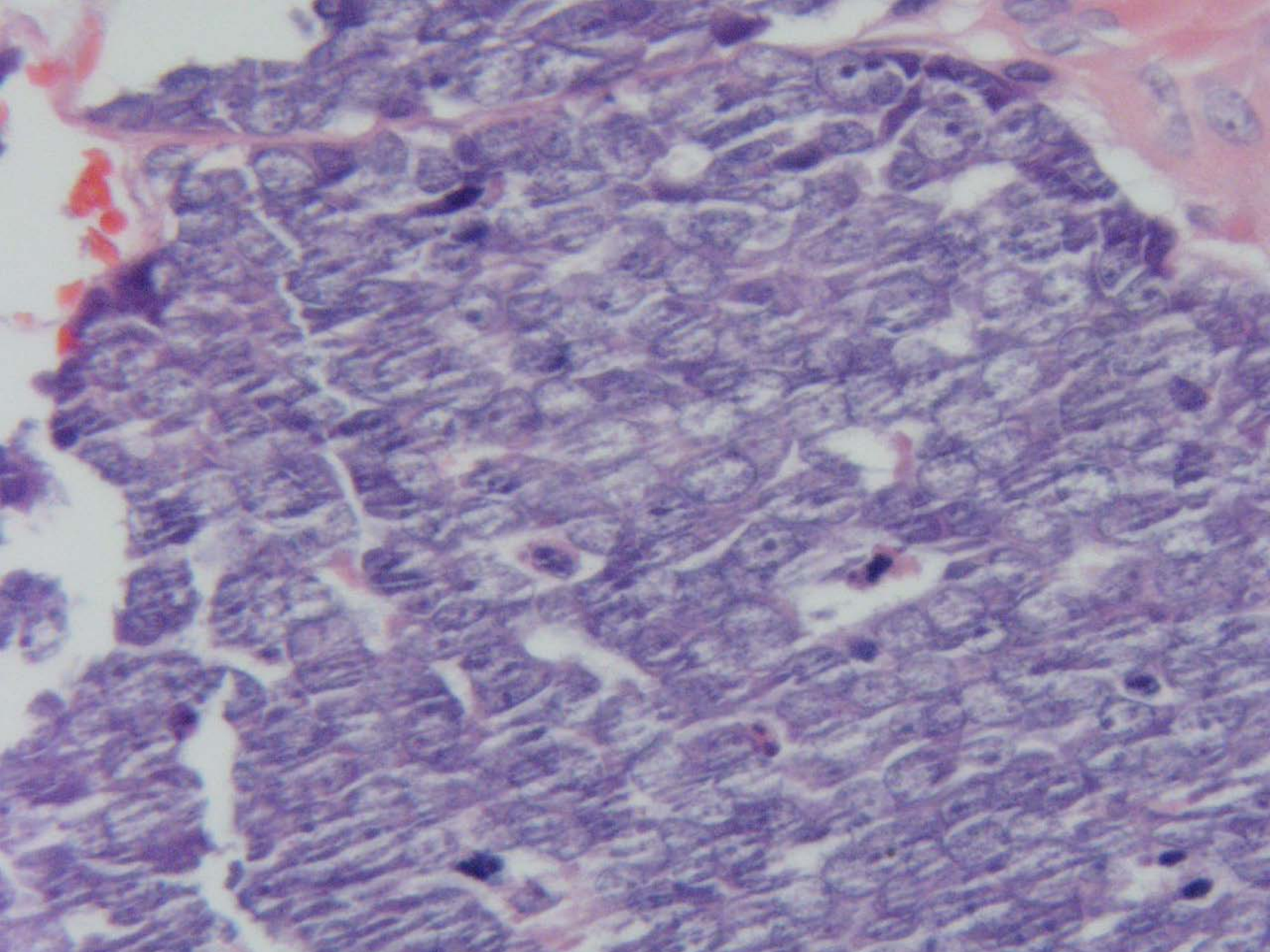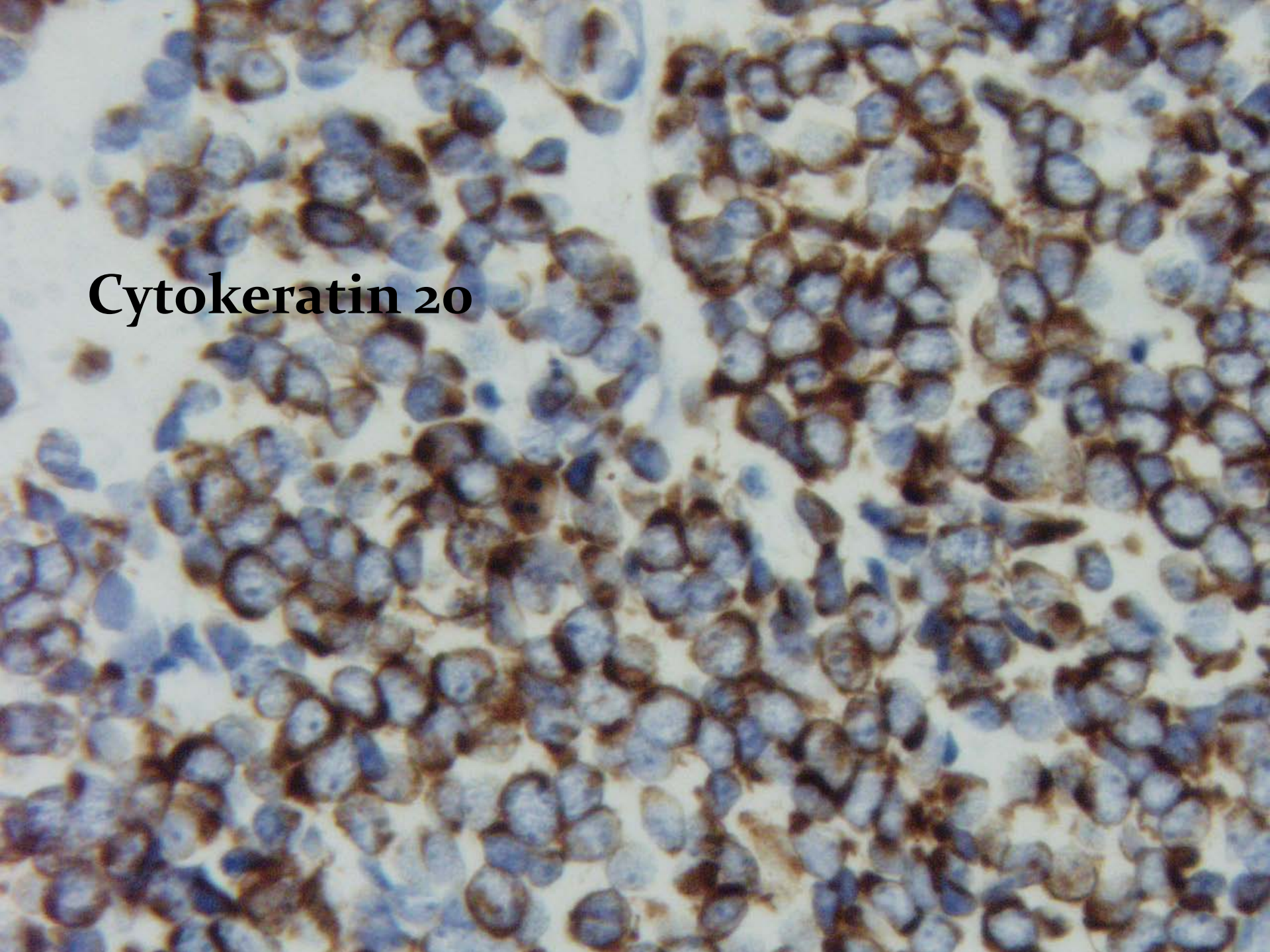
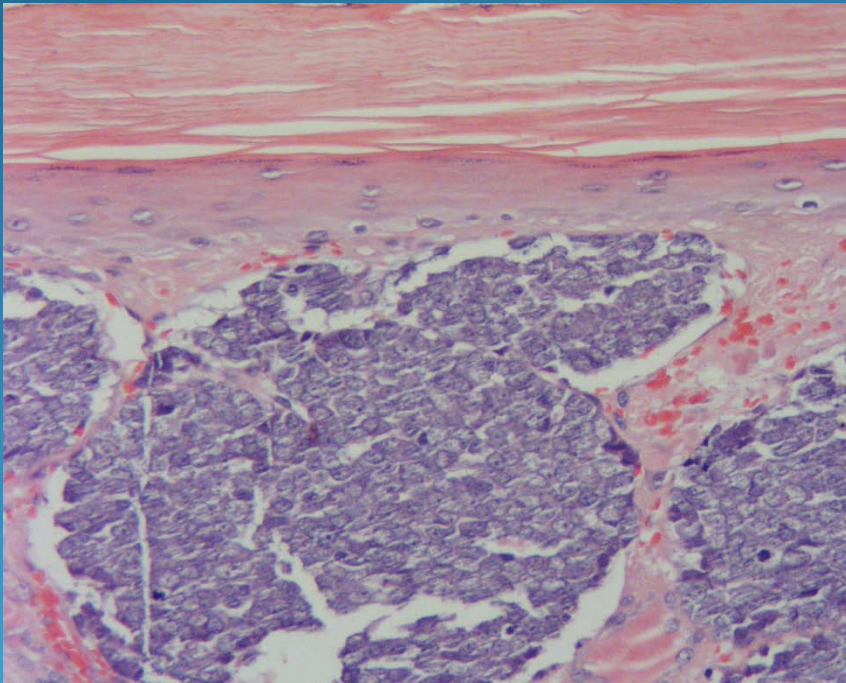


Merkel Cell Carcinoma

Cytokeratin 20



Pearls



- Blue hyperchromatic tumor diffusely filling the dermis
- Usually no epidermal attachment
- Nuclei have dispersed chromatin usually no prominent nucleoli
- Numerous mitotic figures