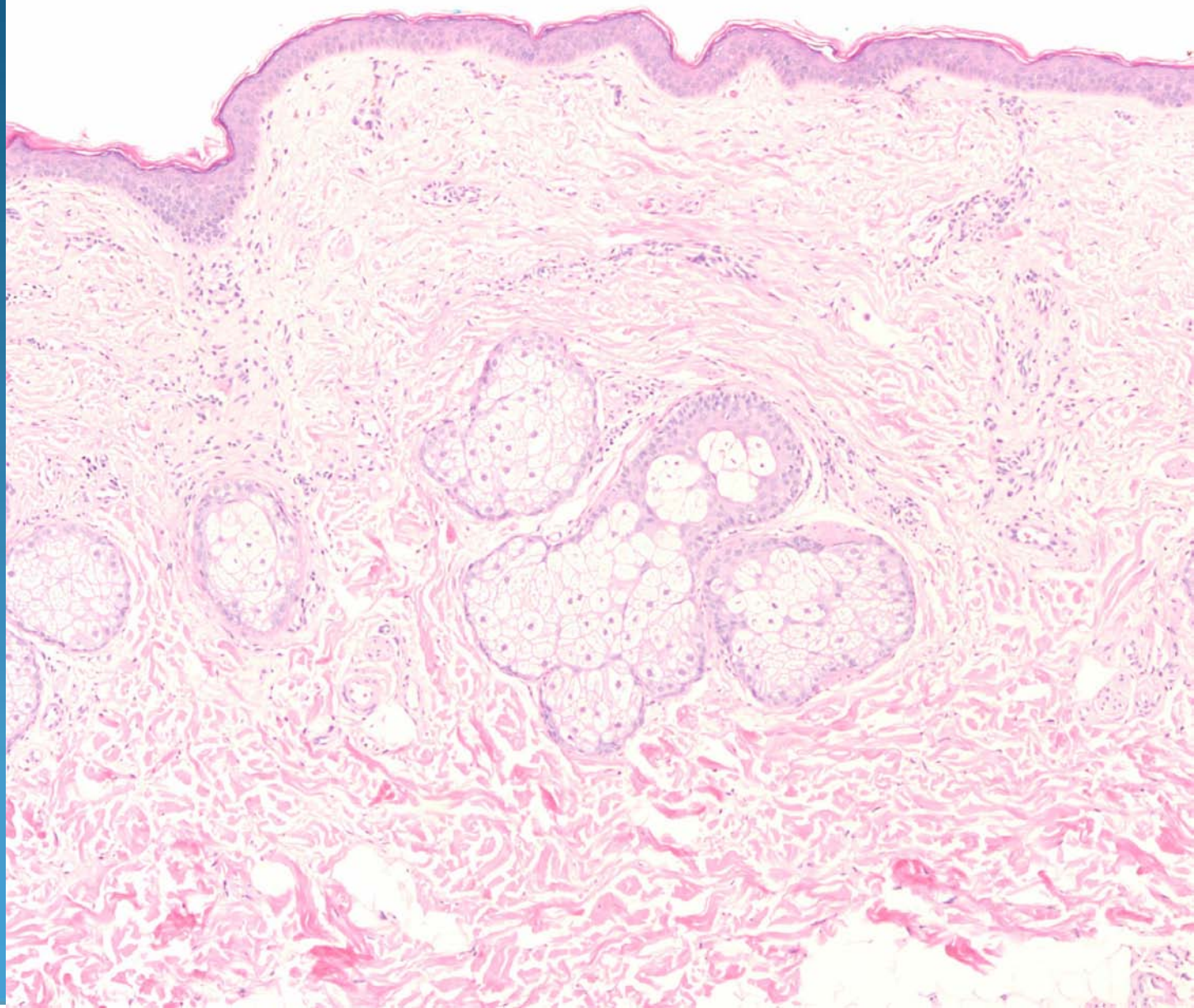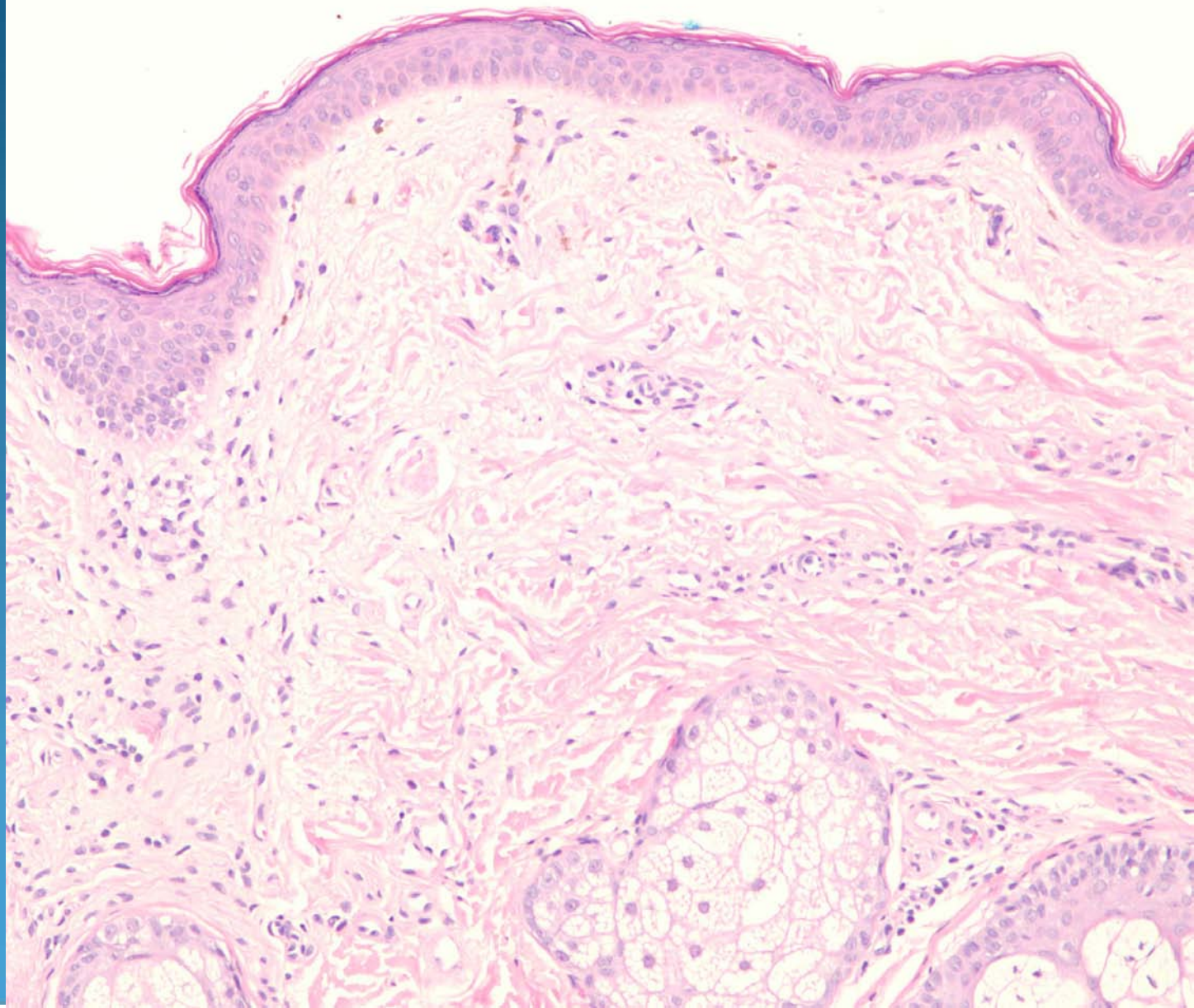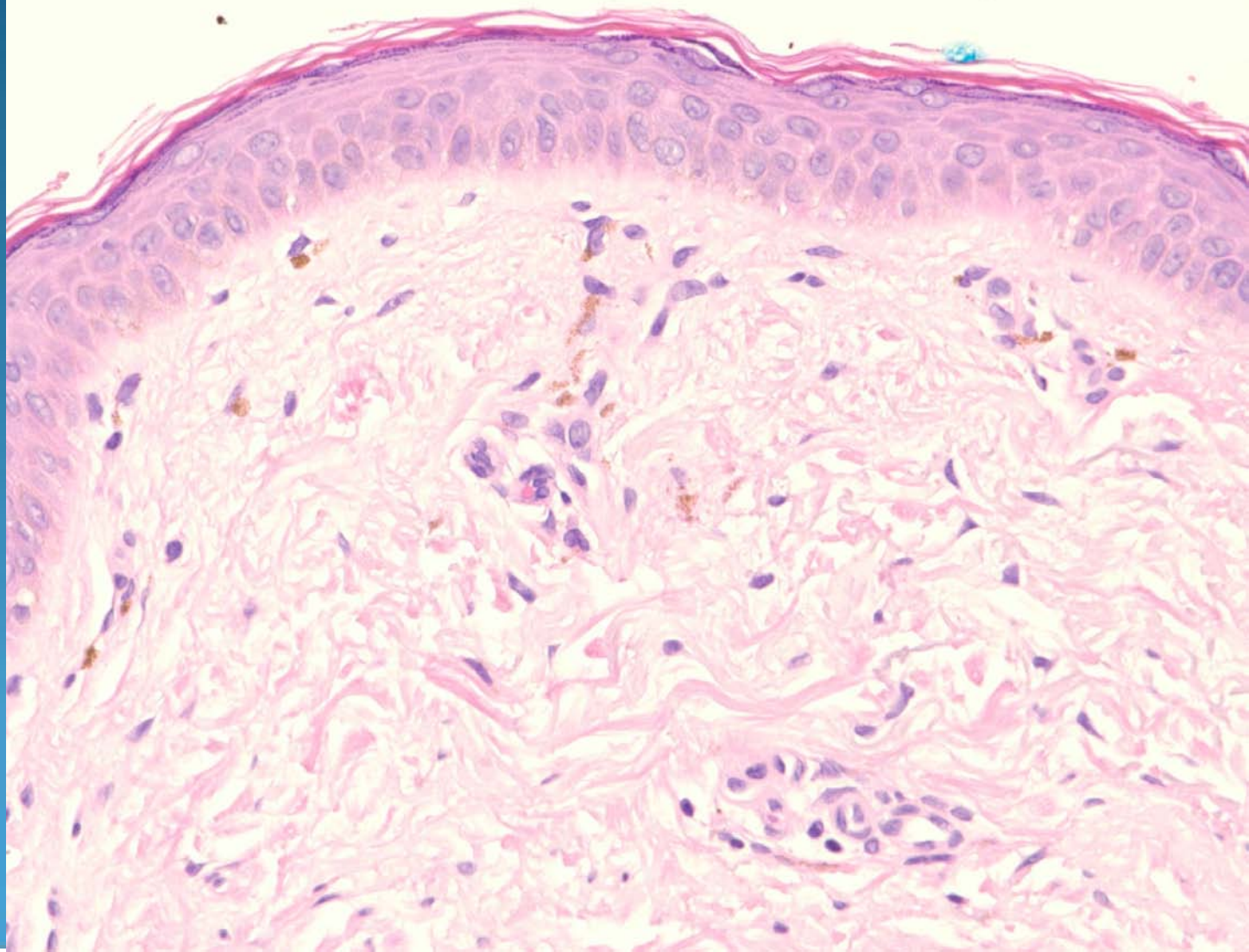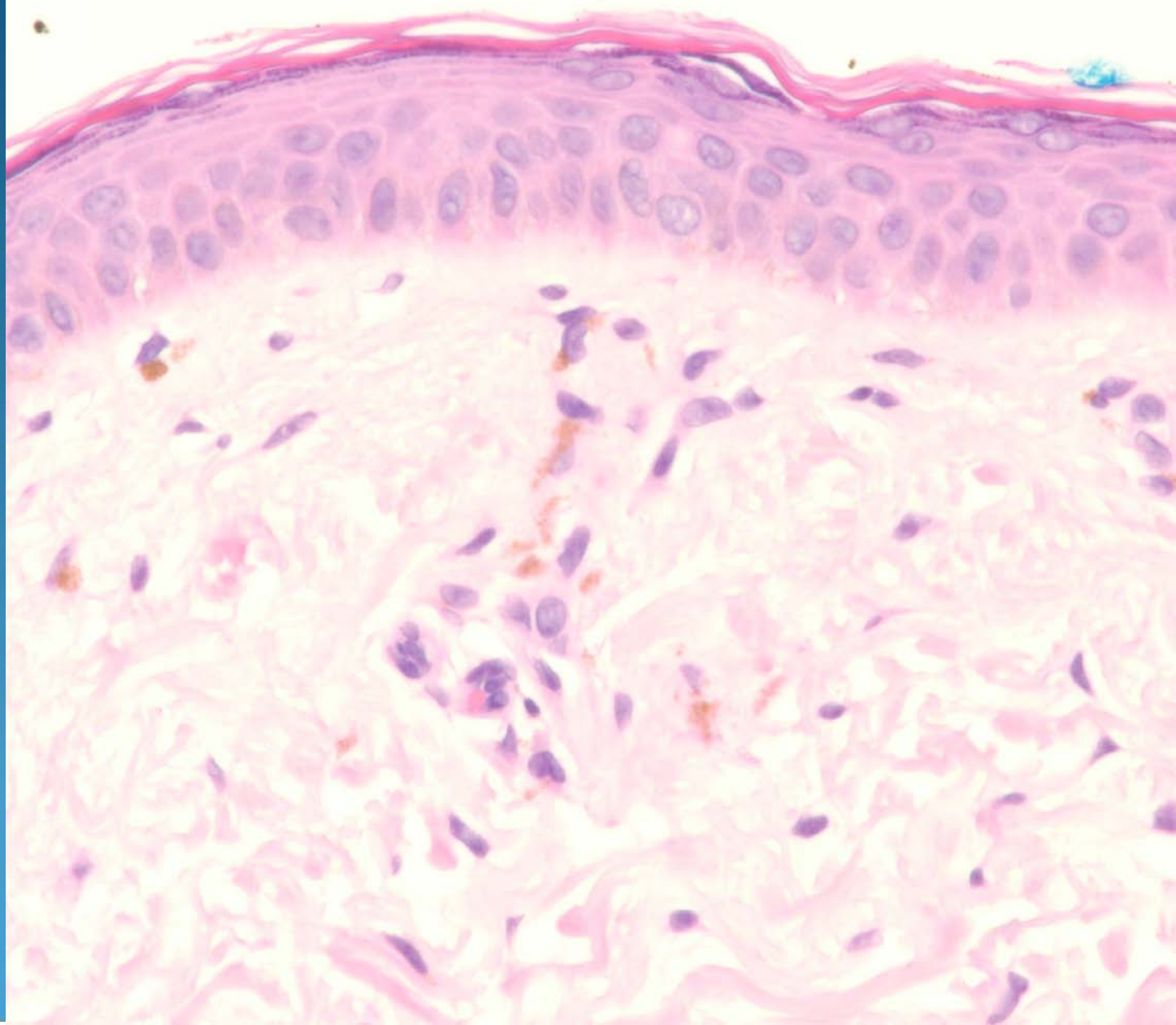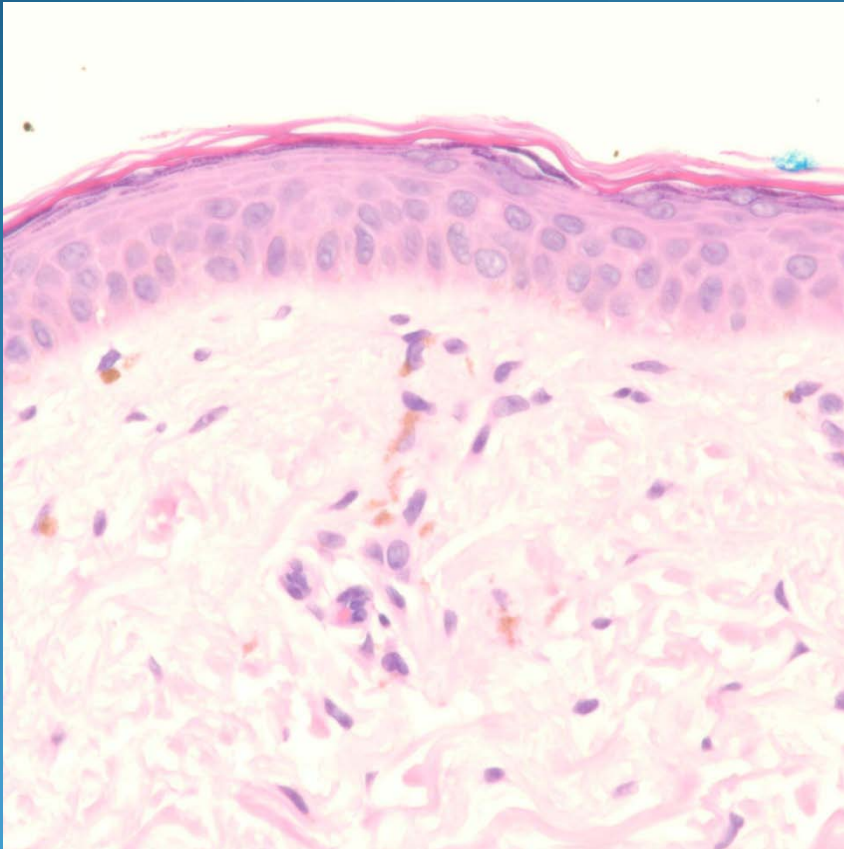


# Melasma

# Pearls



- Clinical-pathologic correlation
- Scattered melanophages
- No increase in melanocytes
- Rule out blue nevus, tattoo