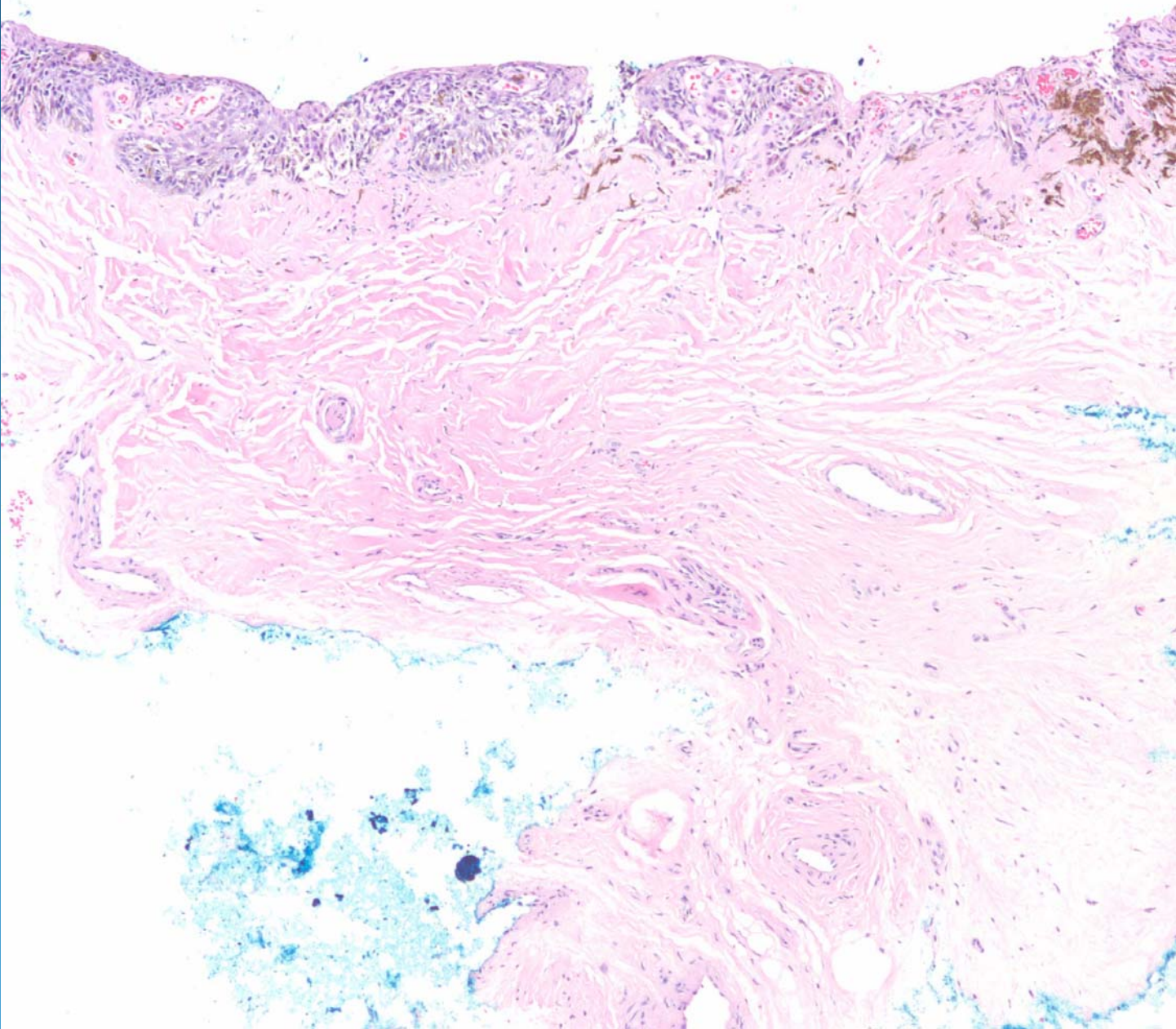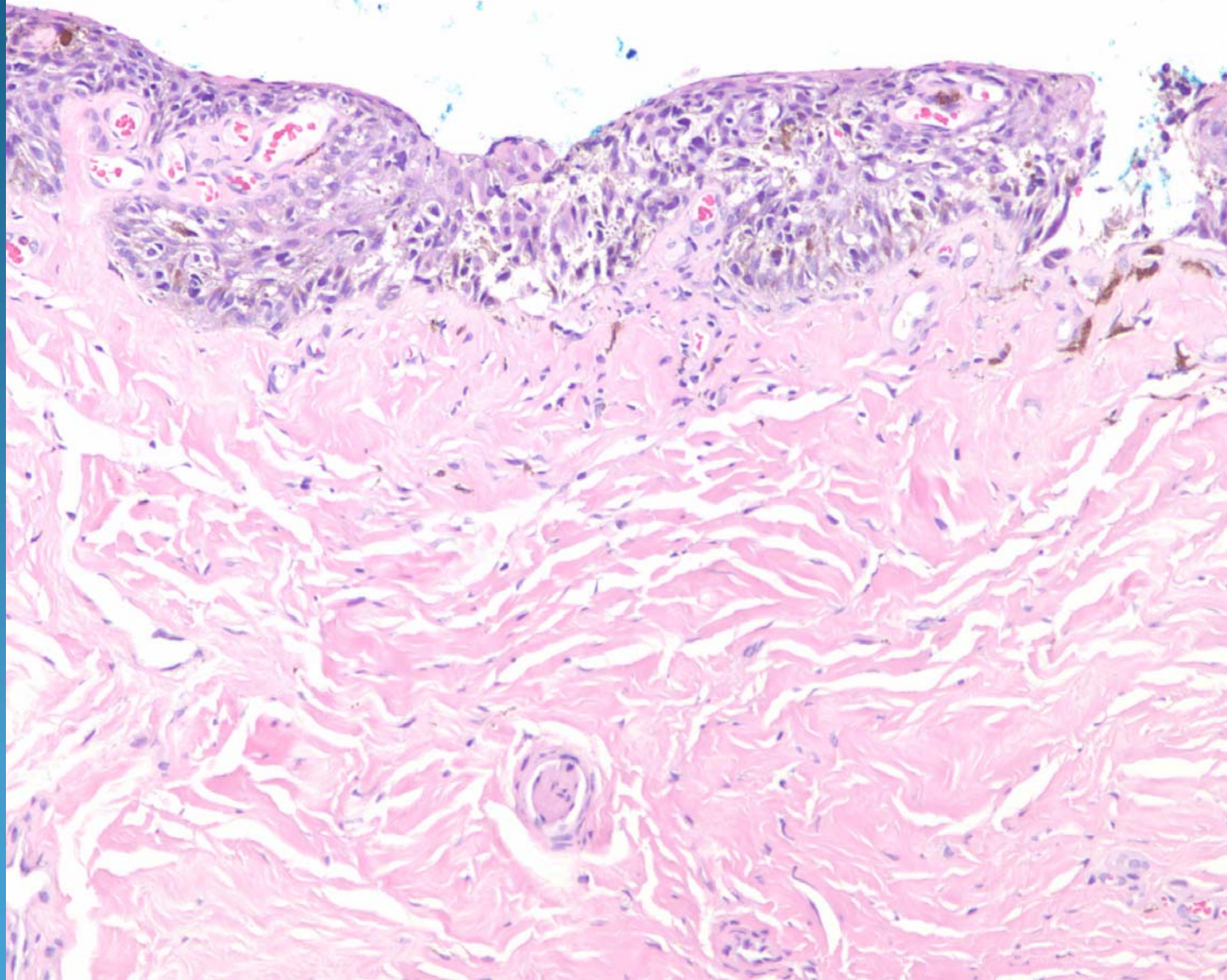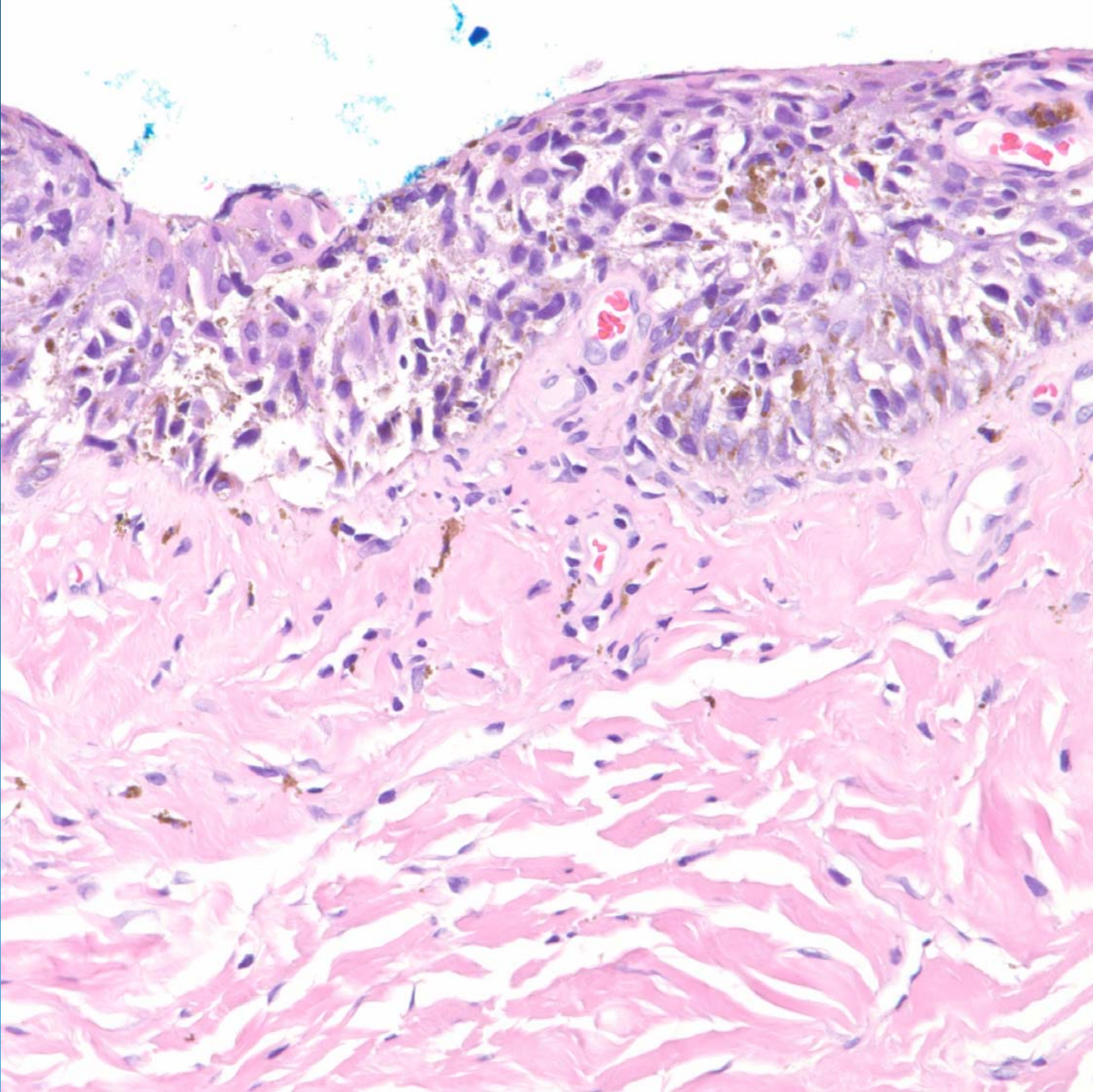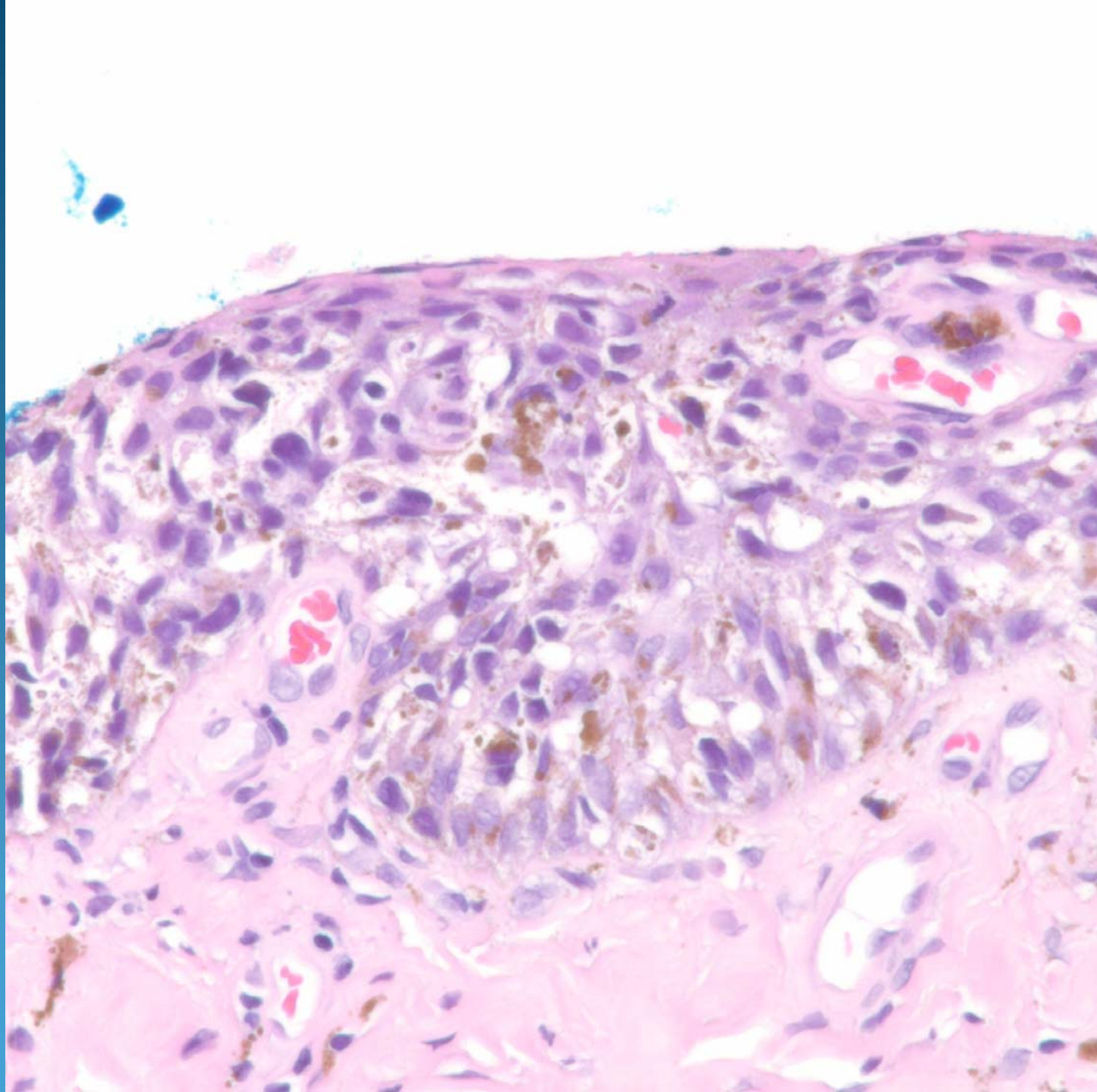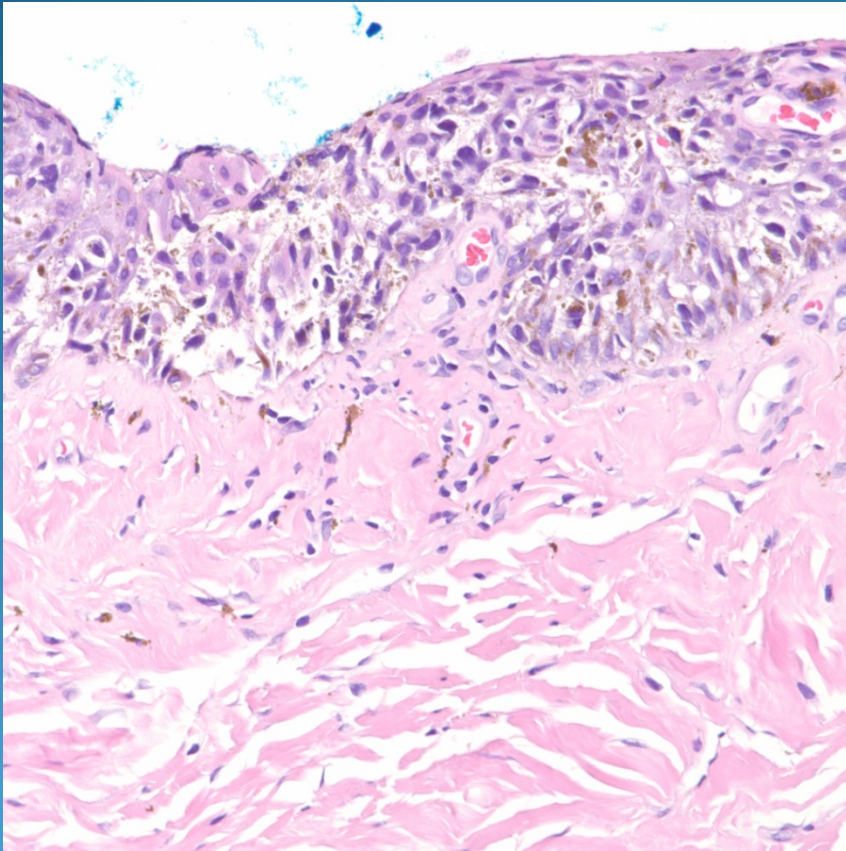


# Melanoma in Situ of the Nailbed

# Pearls



- Histologically similar to acral melanoma in situ
- Cytologically malignant melanocytes at the dermal-epidermal junction
- Sampling issues always a problem