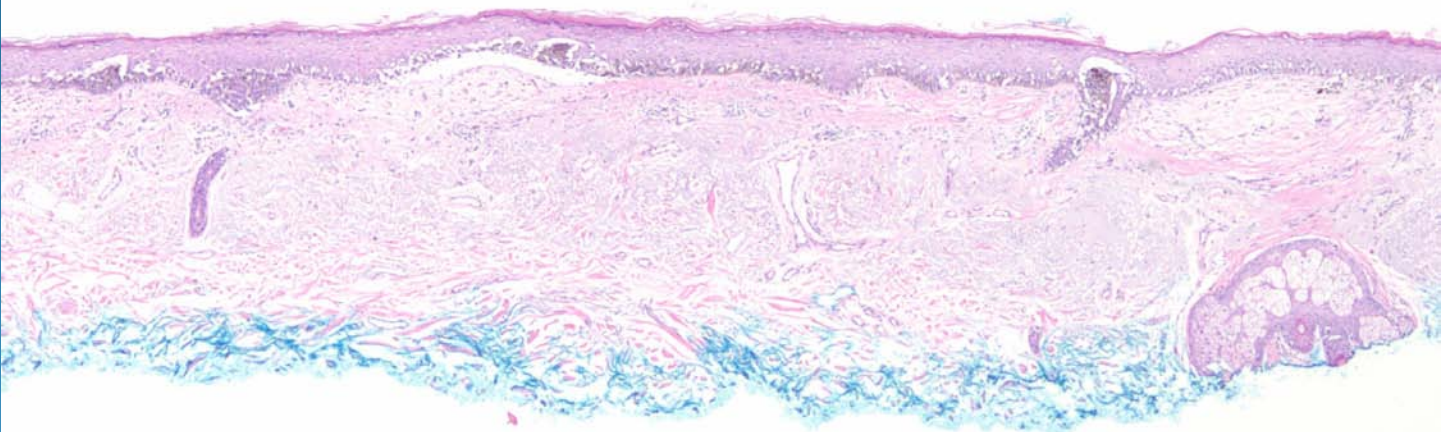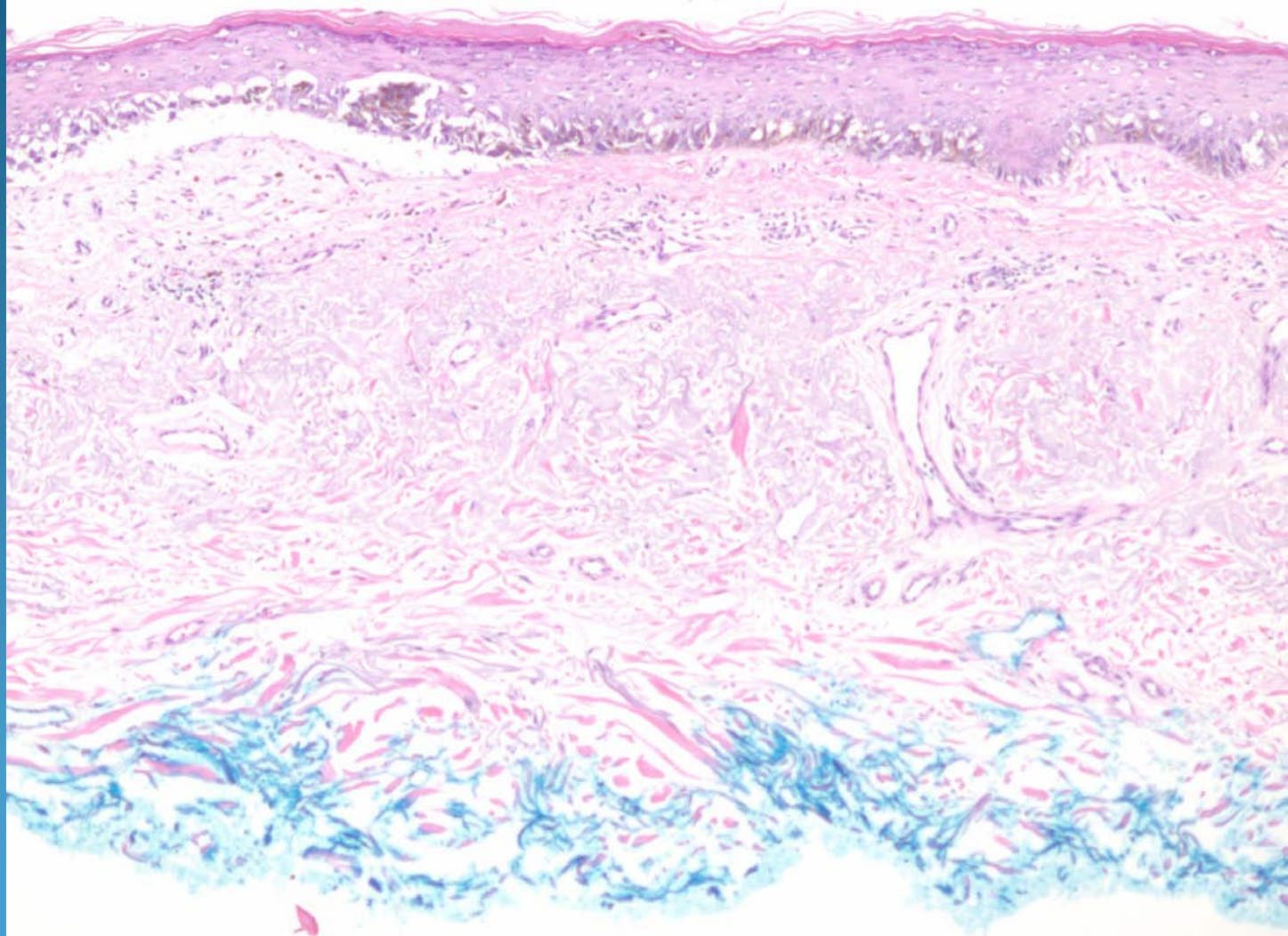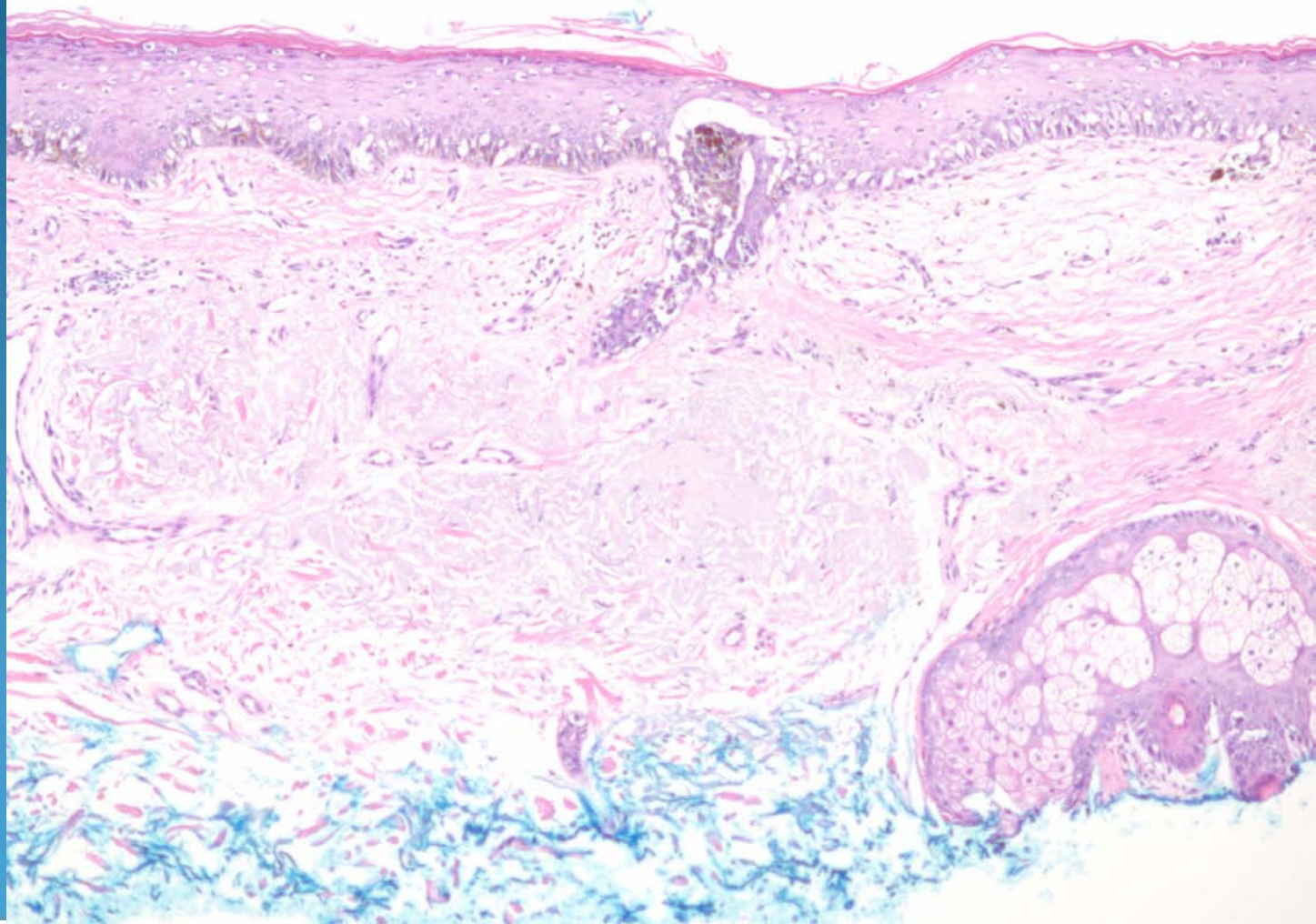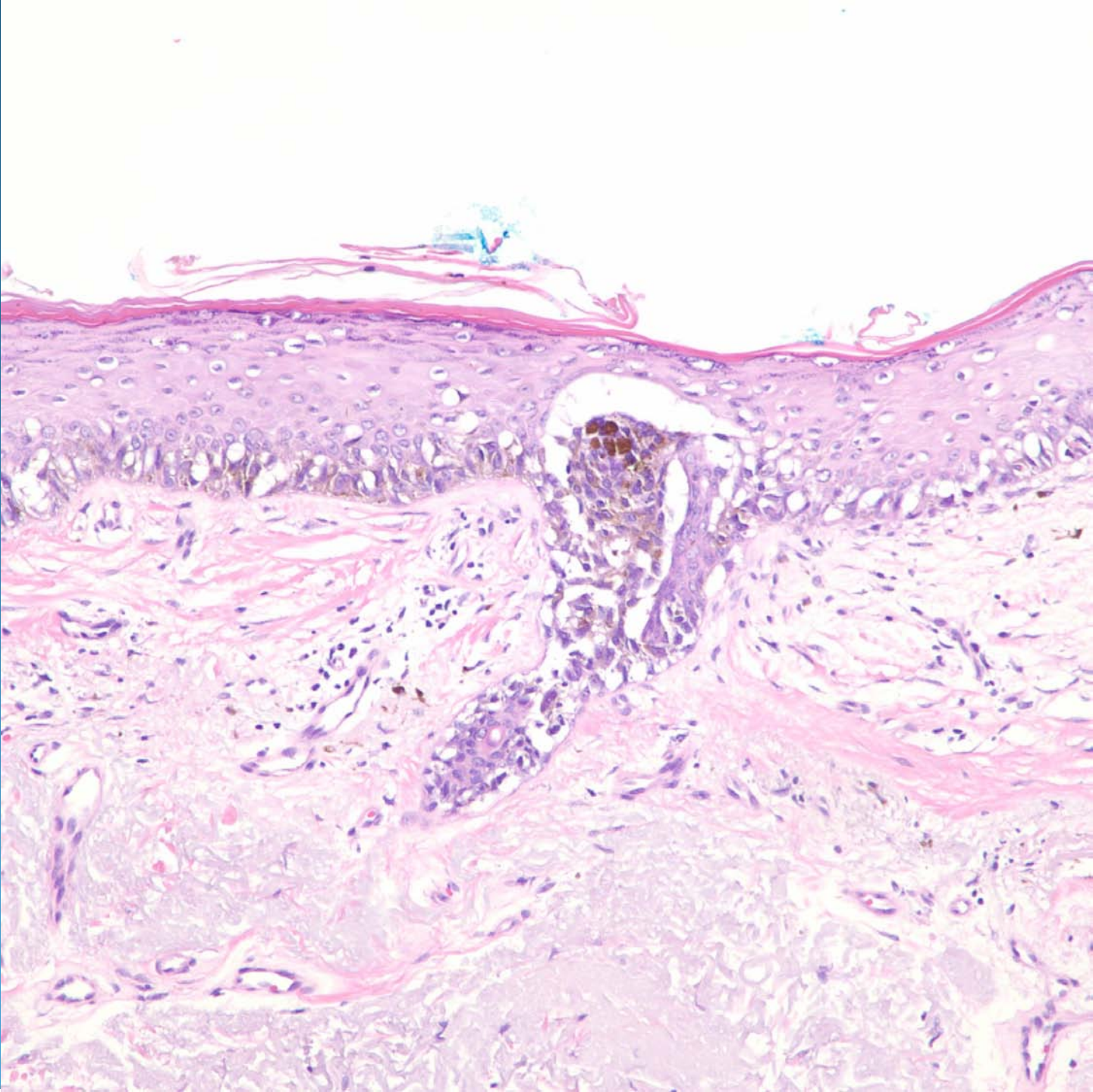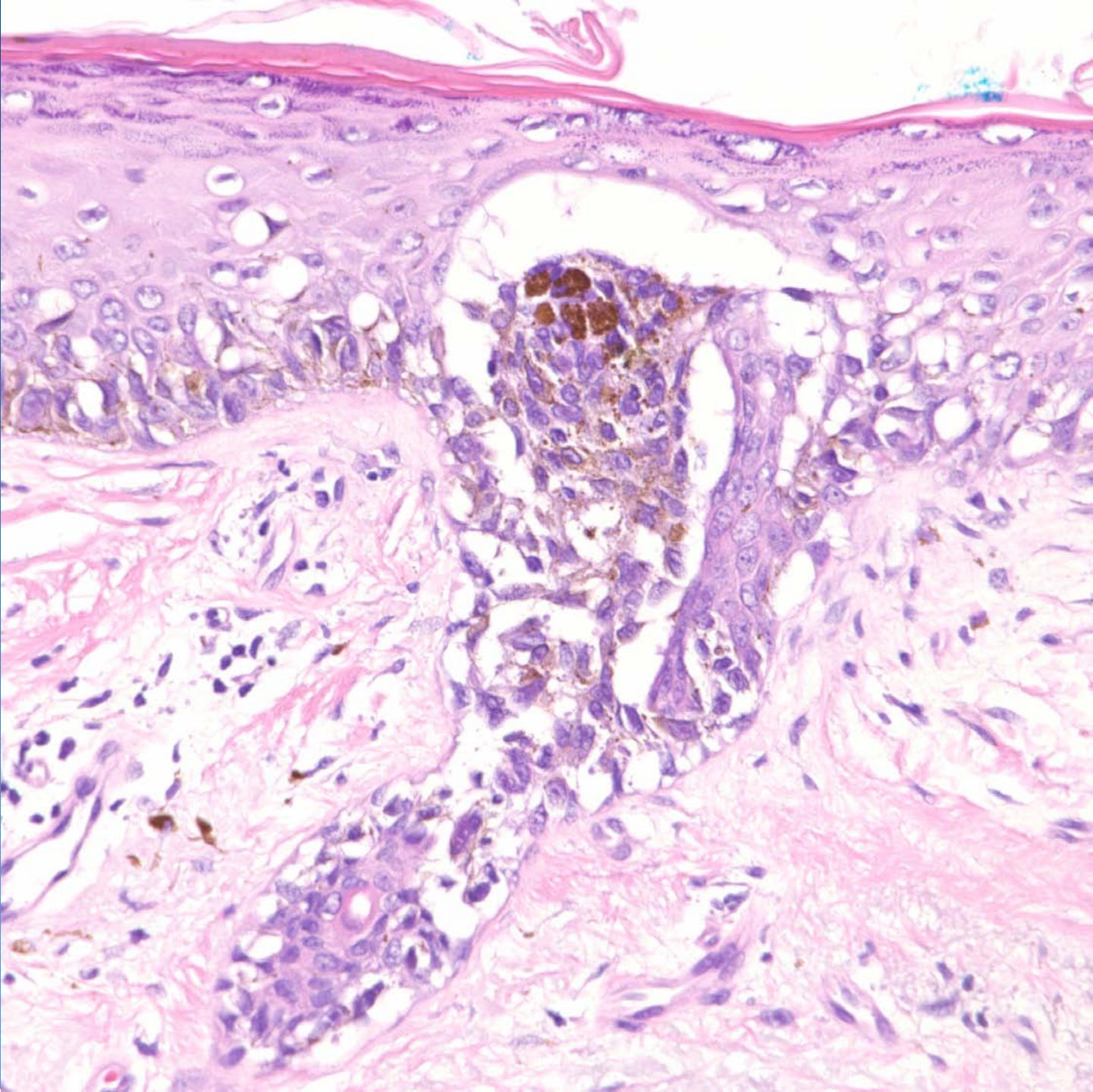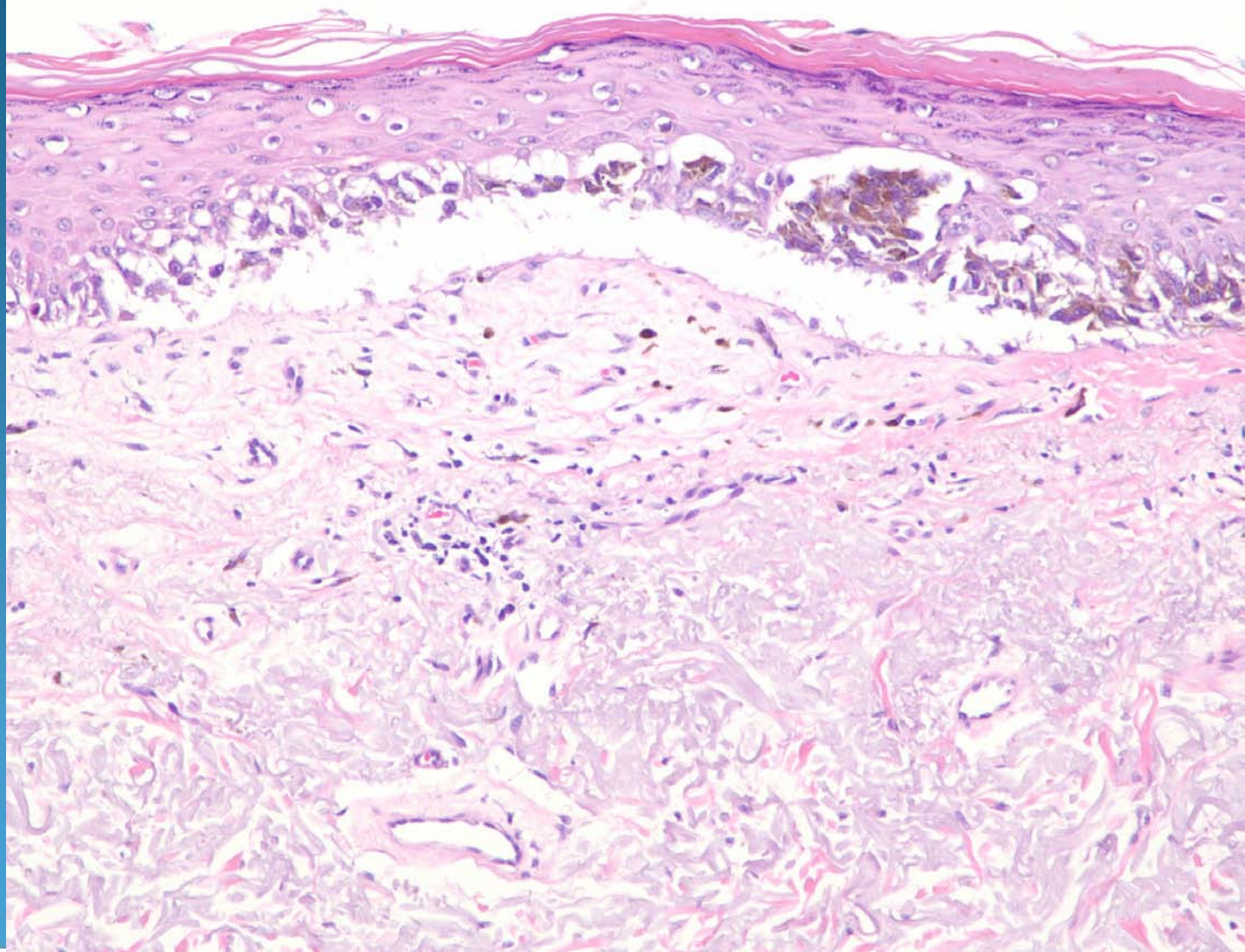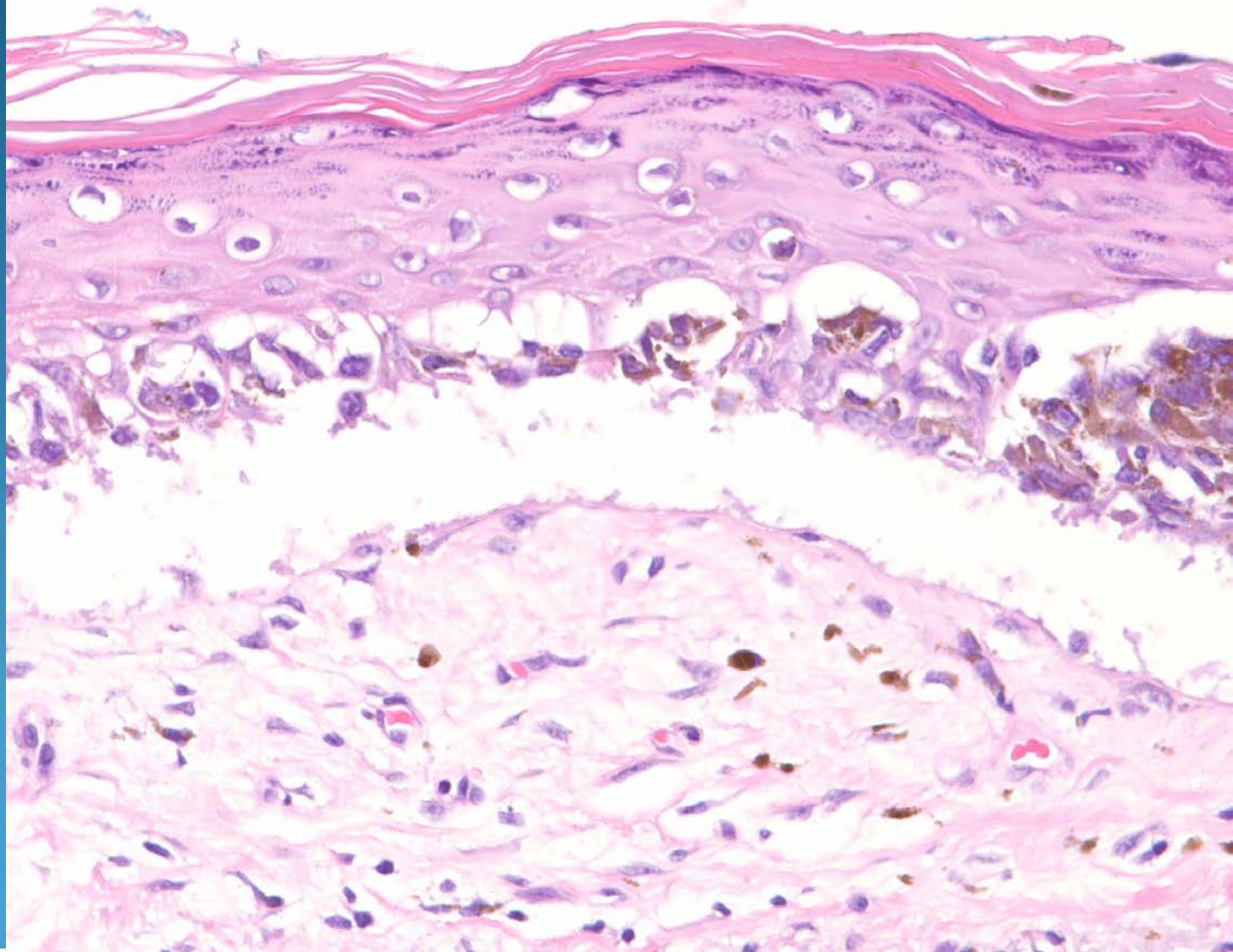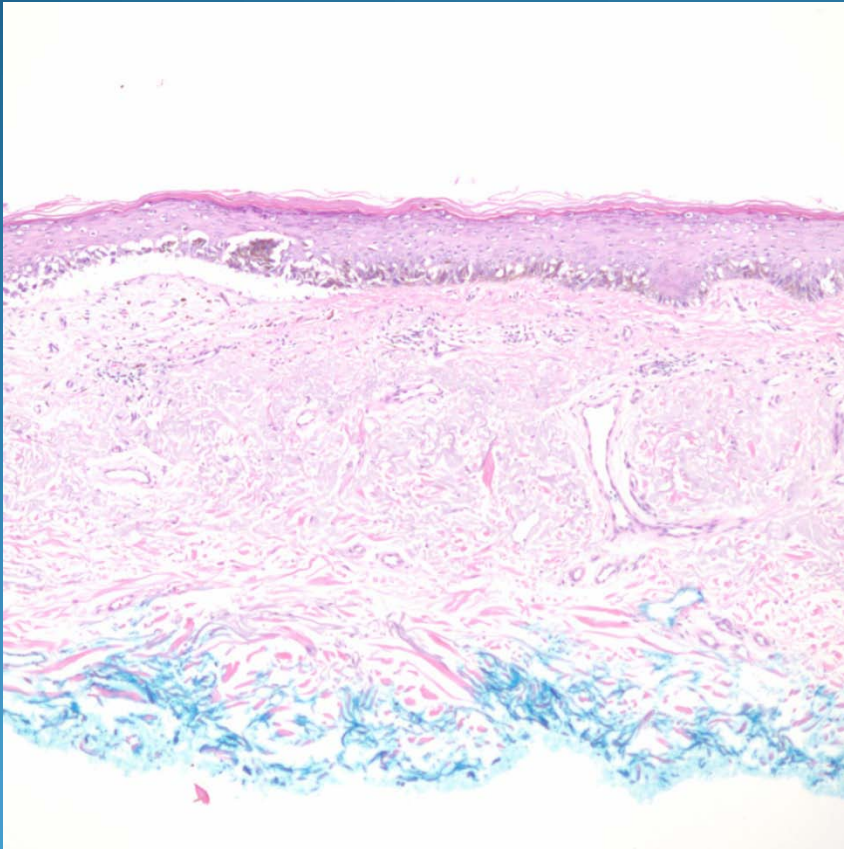


Melanoma in Situ, Lentigo Maligna Type

Pearls



- Expansile discohesive nests of pleomorphic melanocytes
- Asymmetric
- Epidermal thinning on sun damaged skin