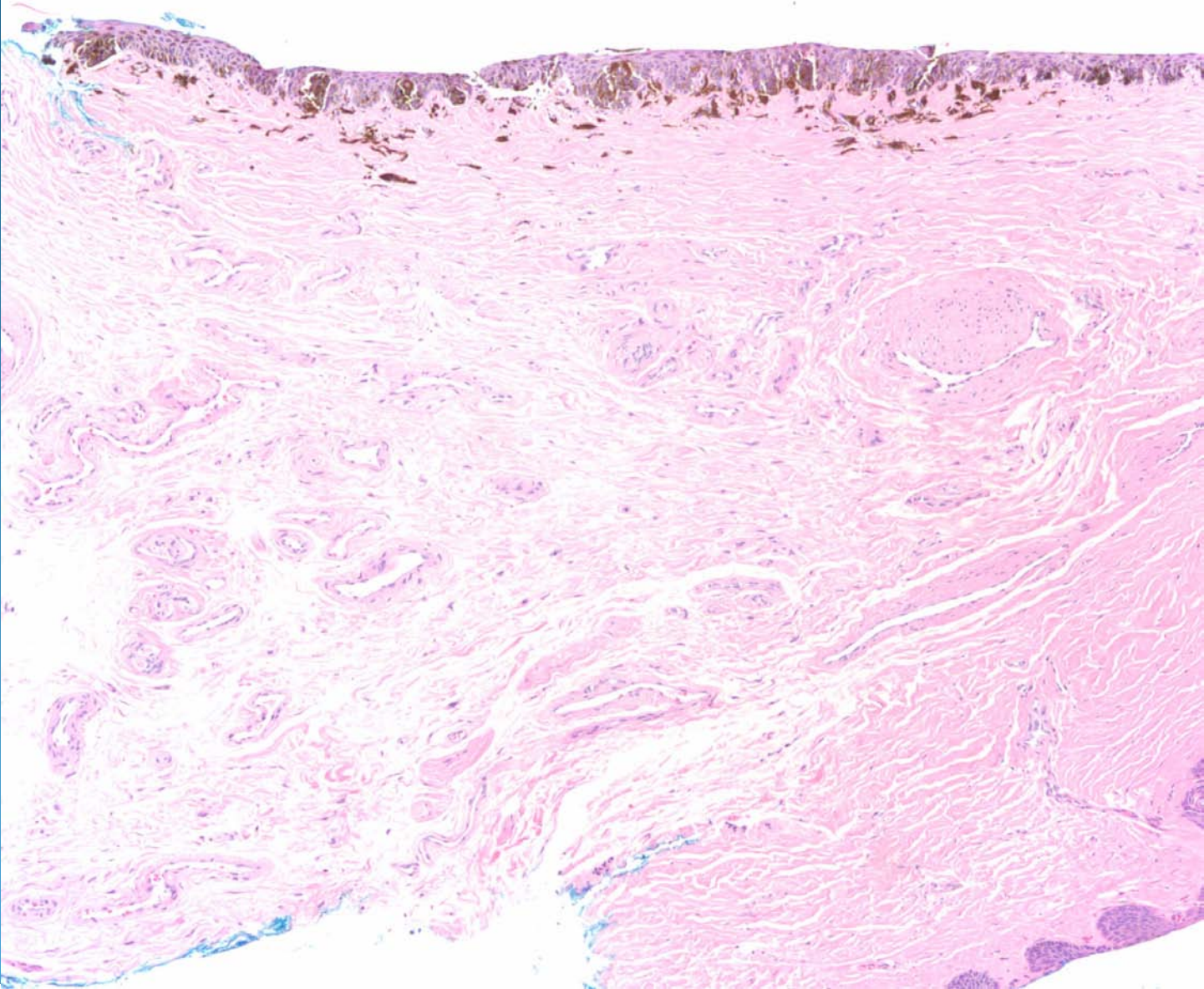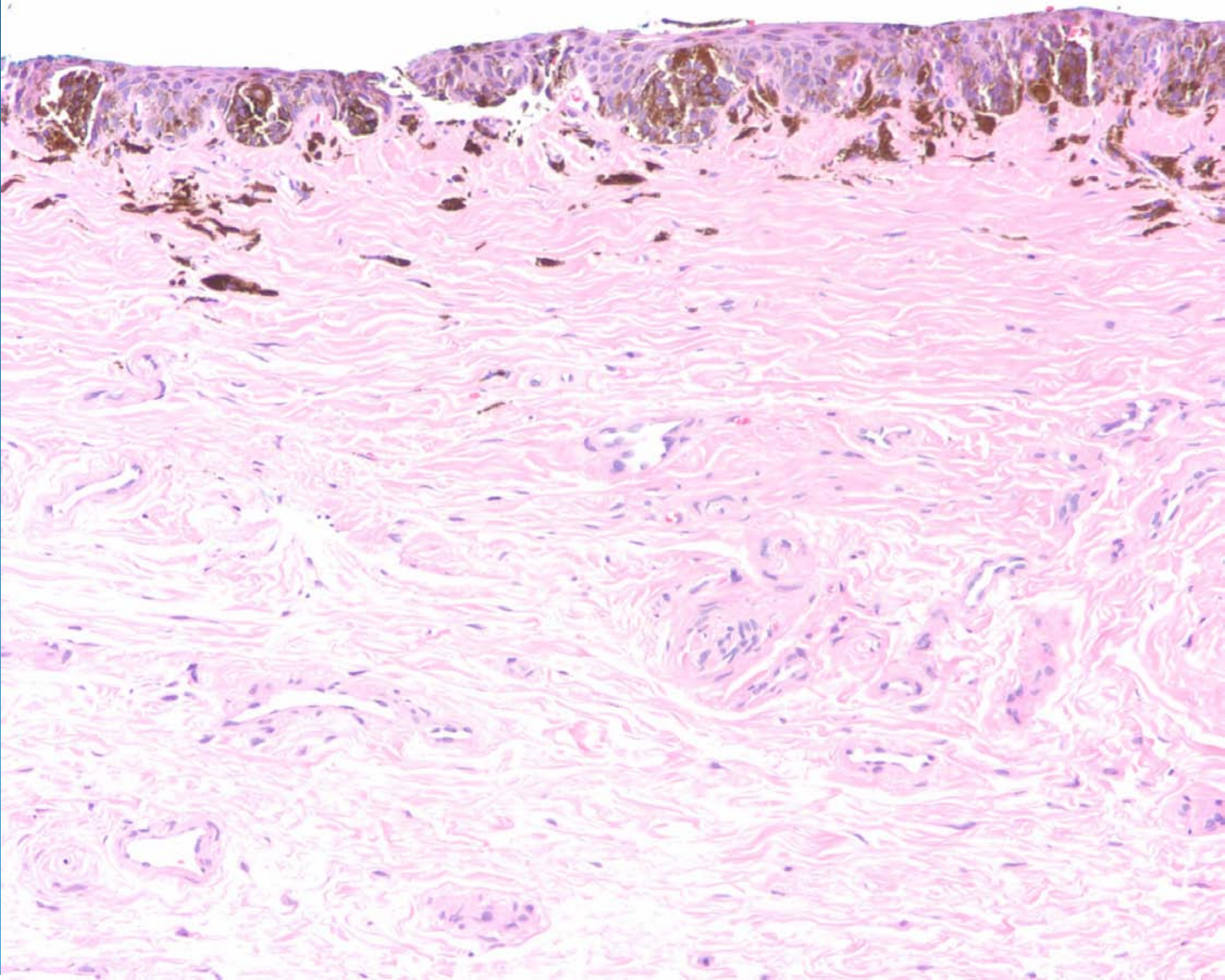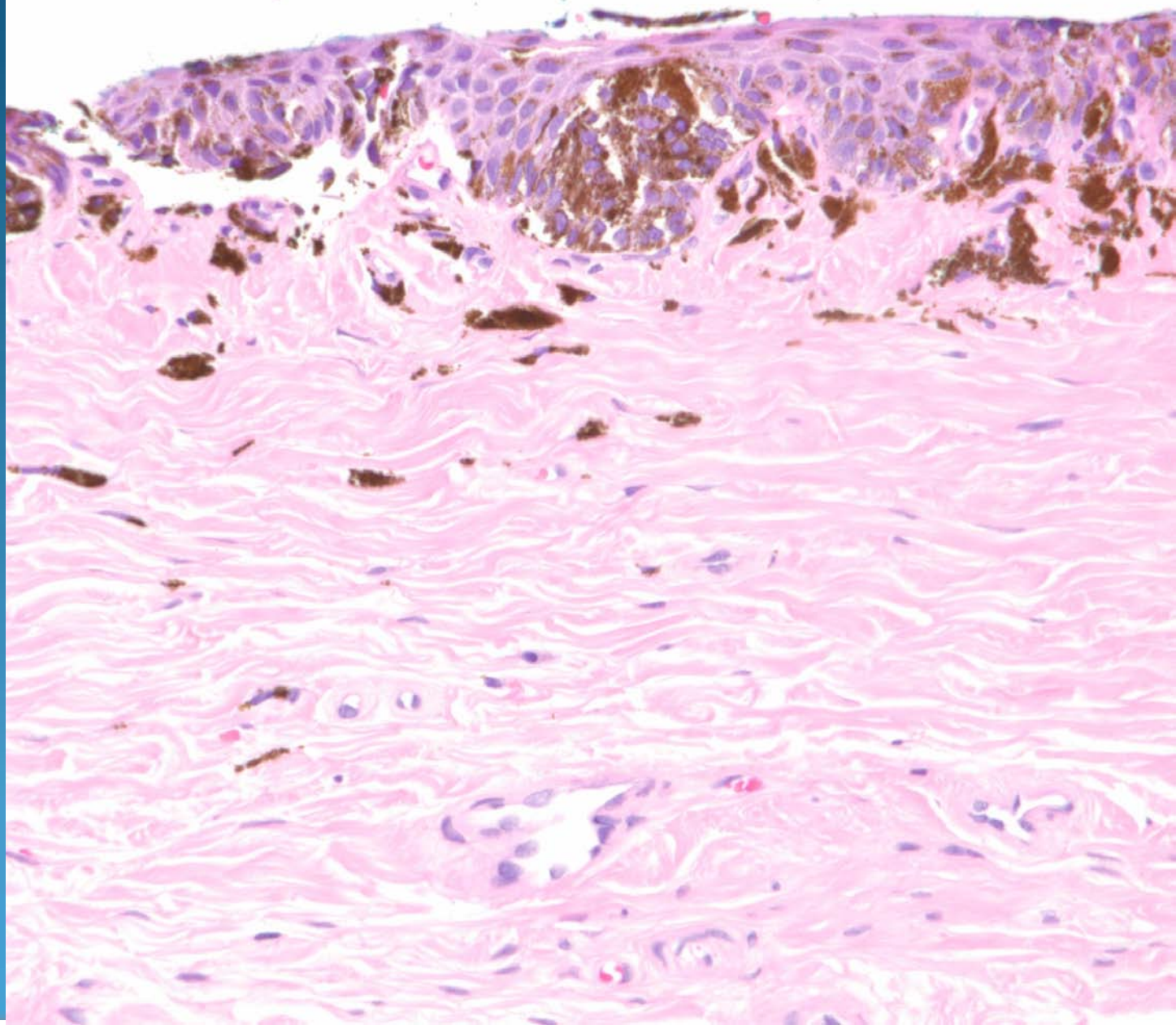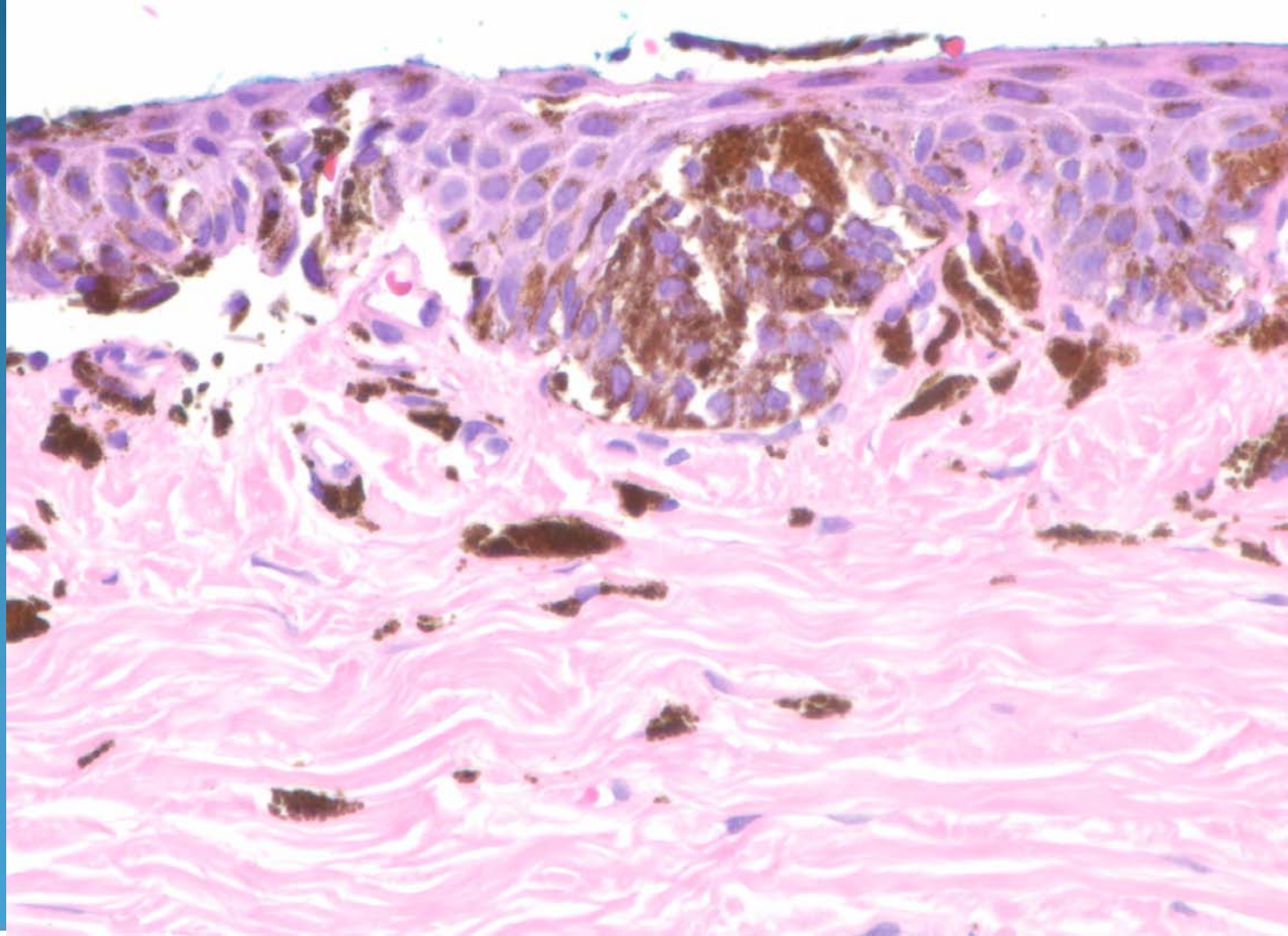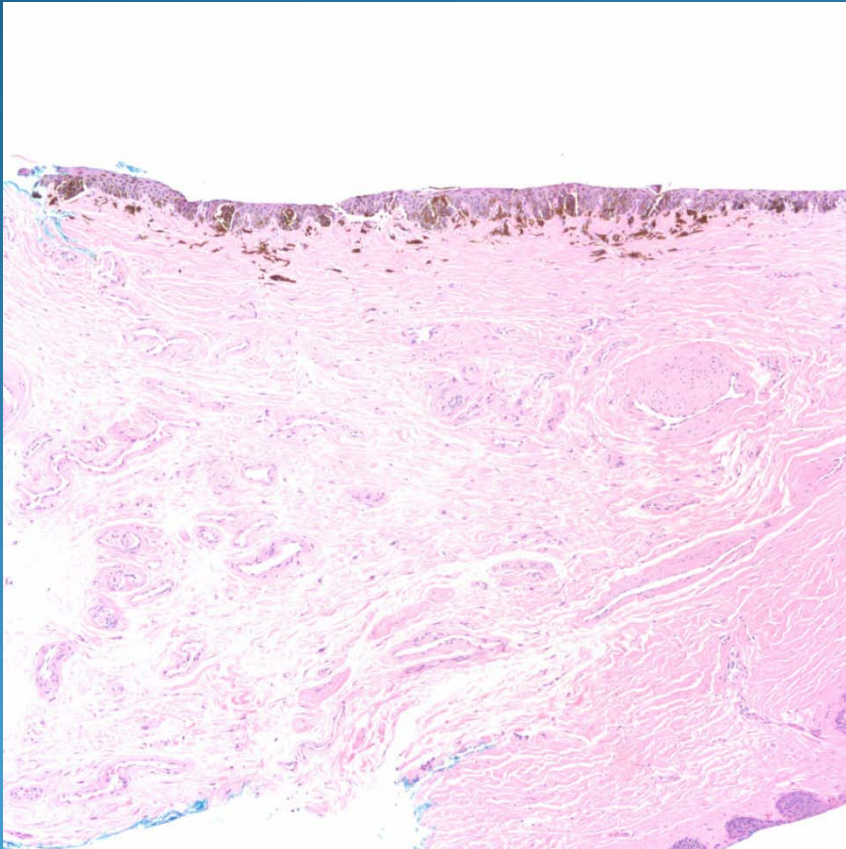


Melanocytic Nevus of Nail

Pearls



- Must recognize the squamous epithelium of nail fold/nail matrix
- Should have even pigmentation and minimal variation of size and shape of melanocytic nuclei
- Always cut deeper to rule out hidden atypia
- Correlate with clinical appearance.