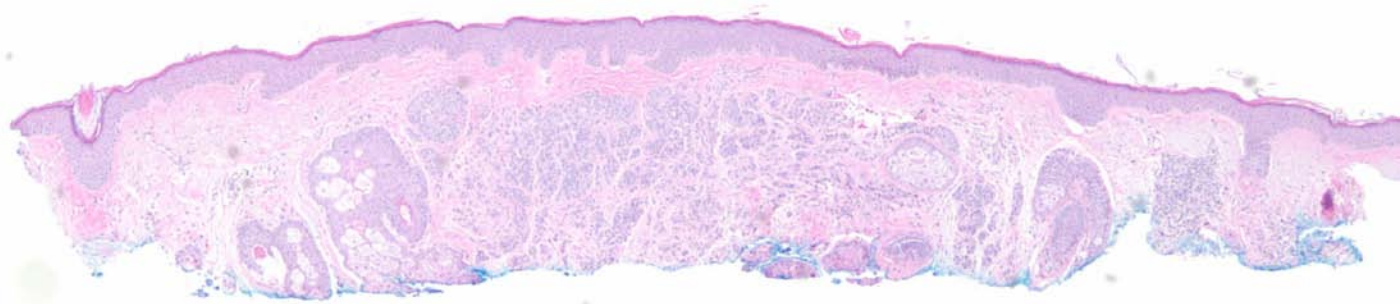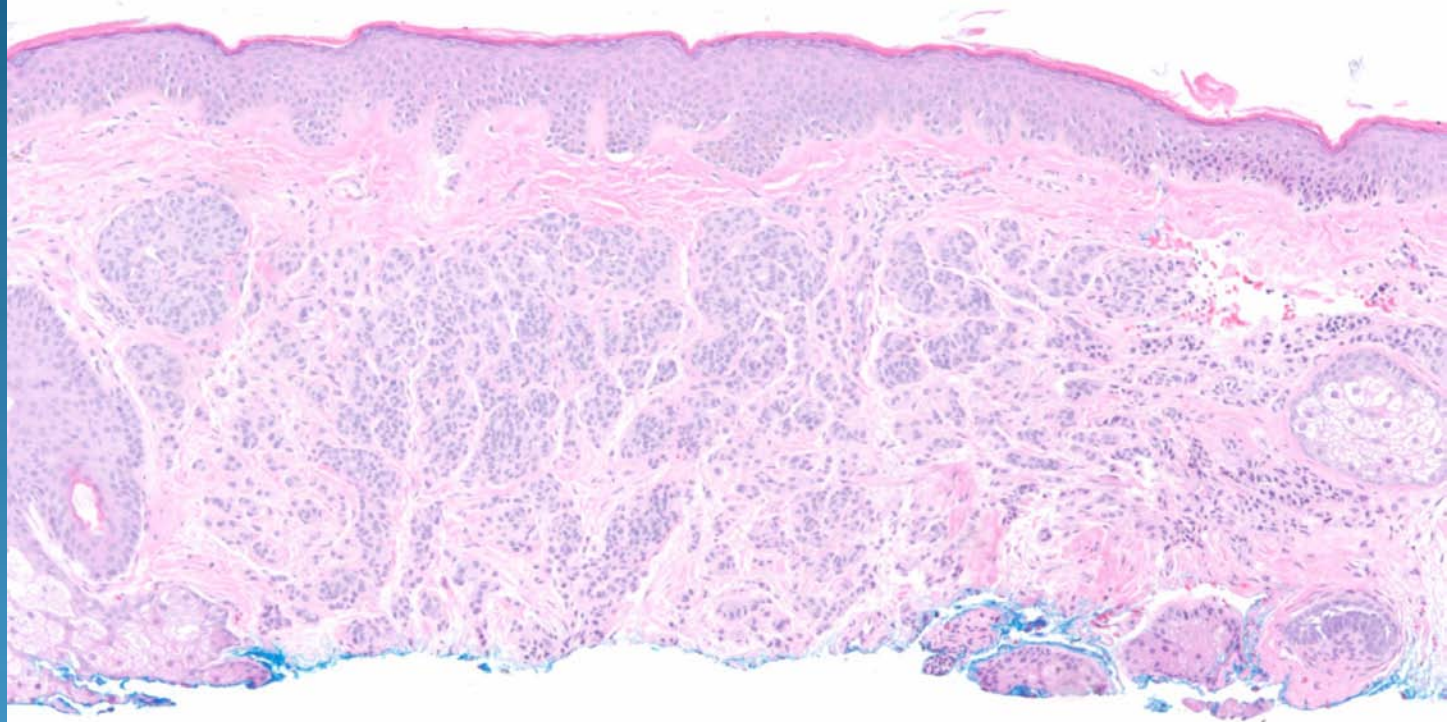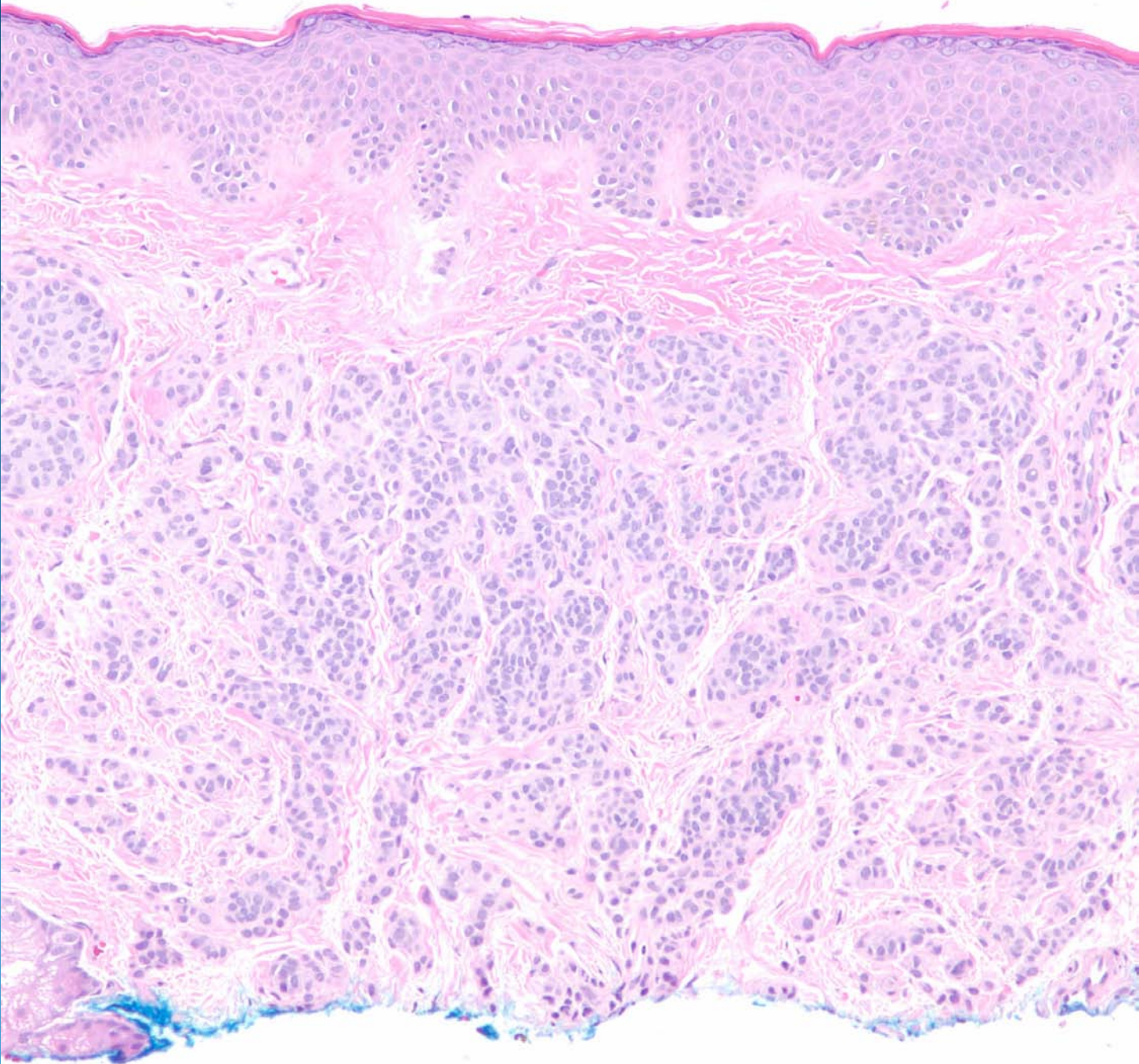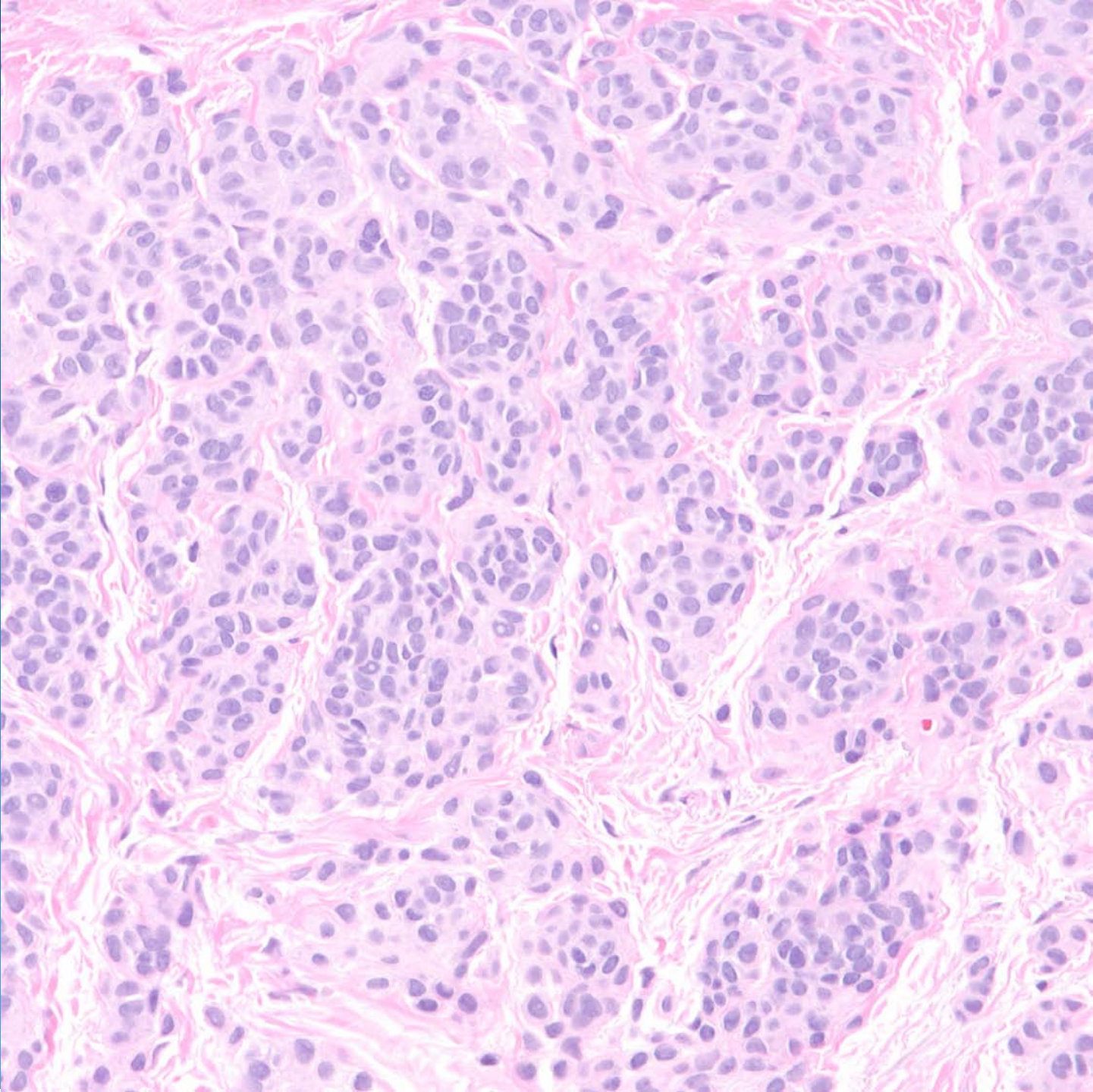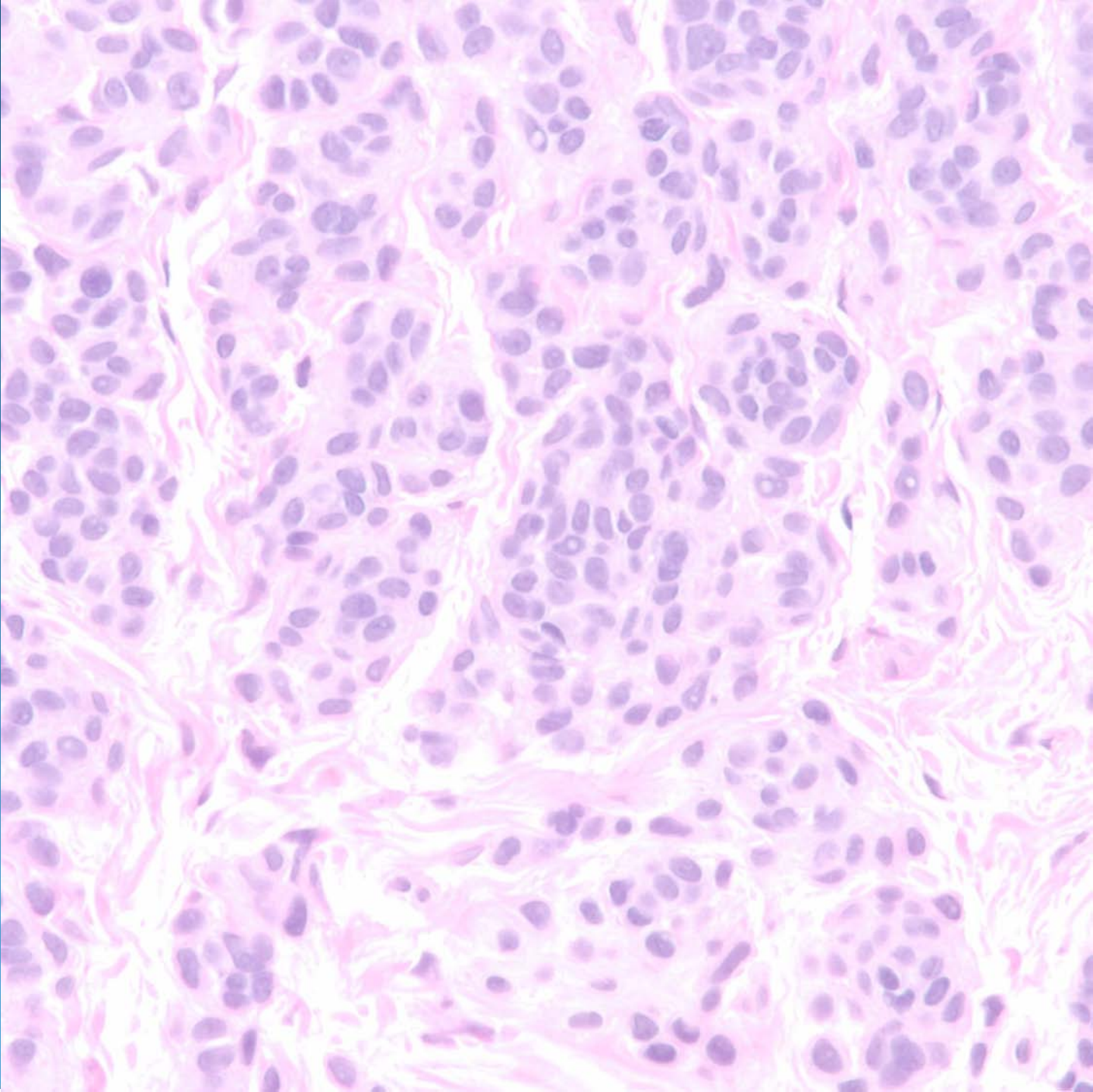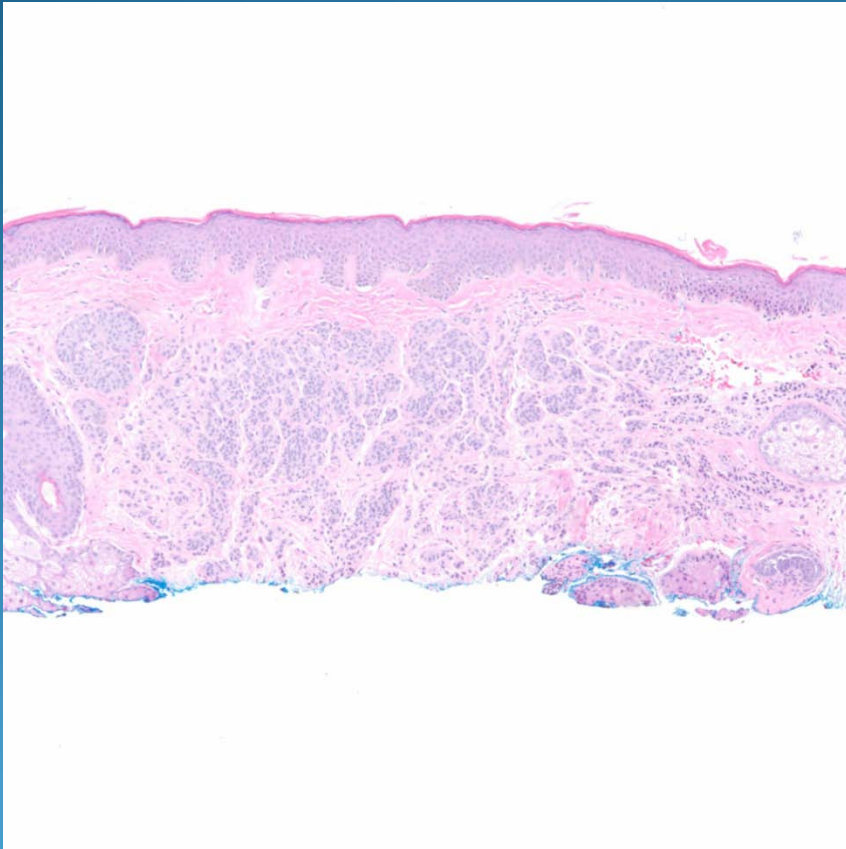


Melanocytic Nevus, Intradermal Type

Pearls



- Nests of bland melanocytes localized to dermis
- Maturation, good peripheral circumscription, no cytologic atypia, no mitotic figures in deeper melanocytes