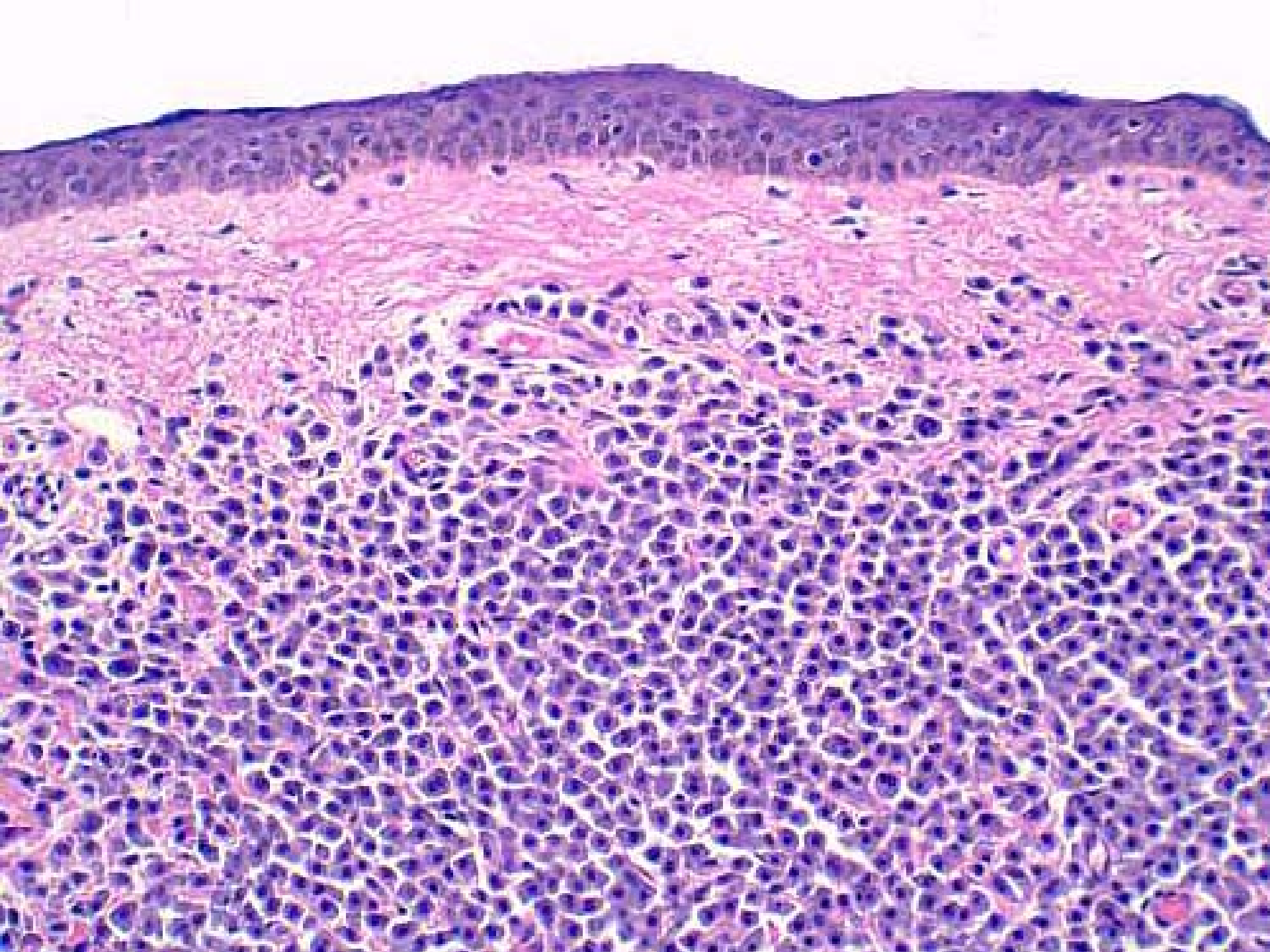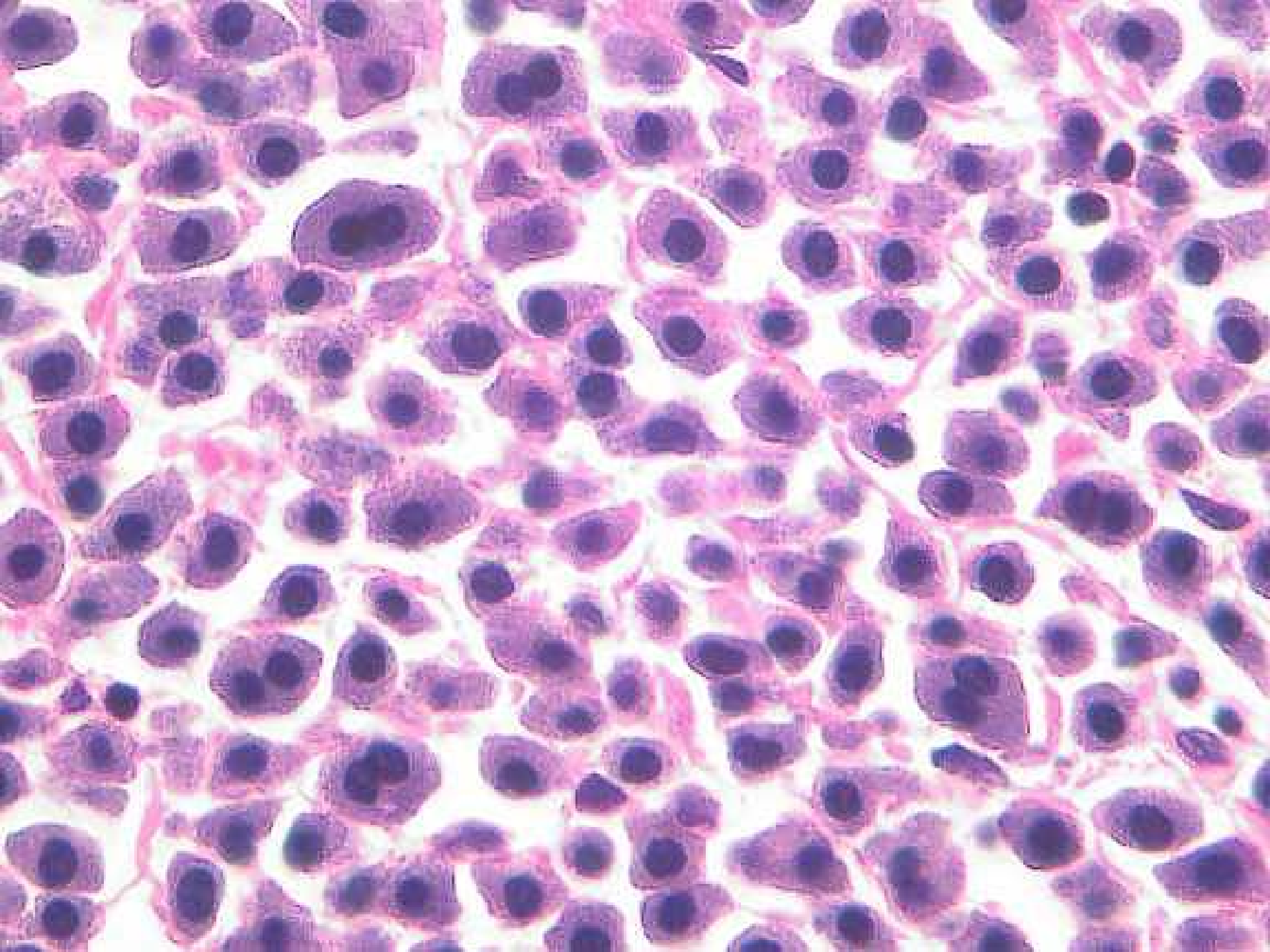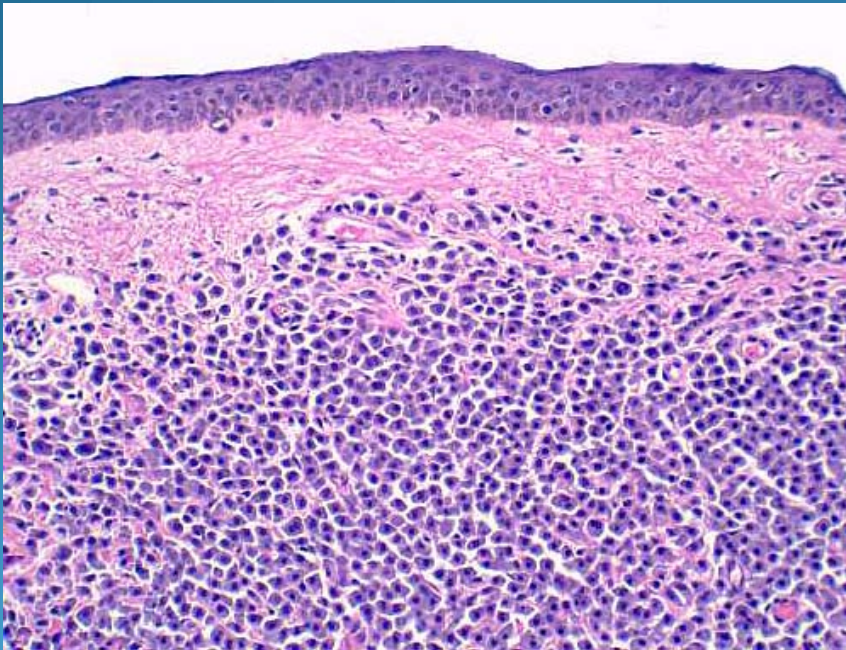


Mastocytoma

Pearls



- Nodular collection of mature mast cells showing “fried-egg” appearance
- May have Grenz zone
- Rarely bullous change