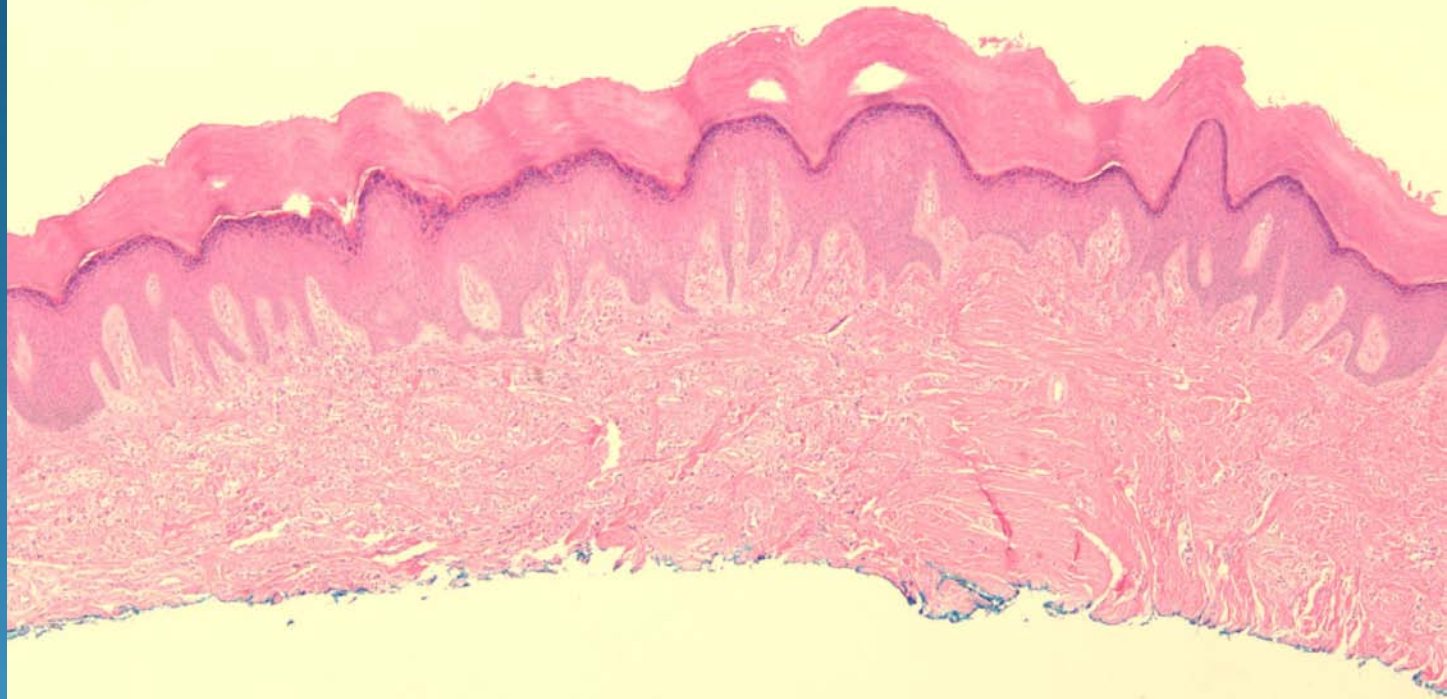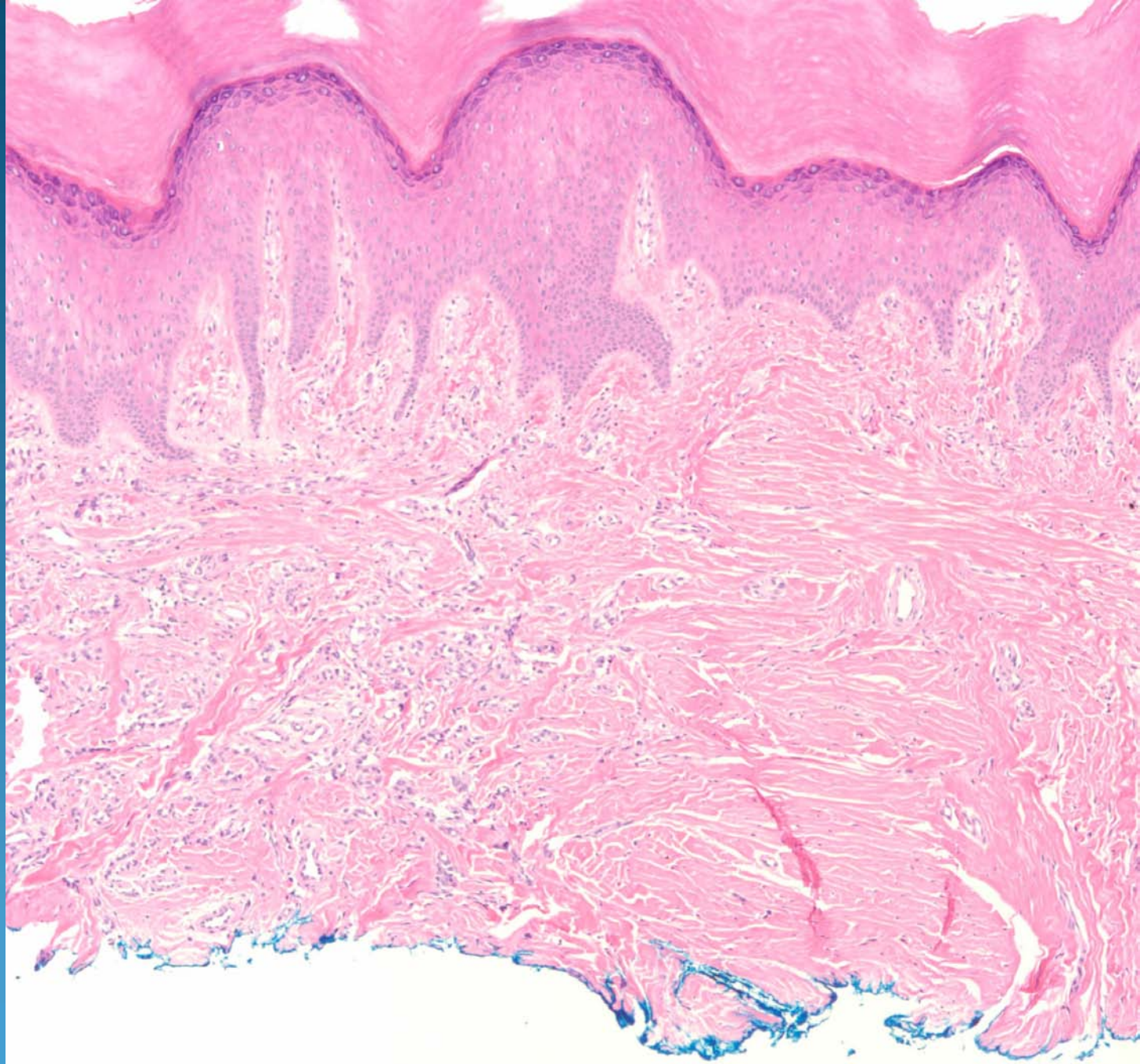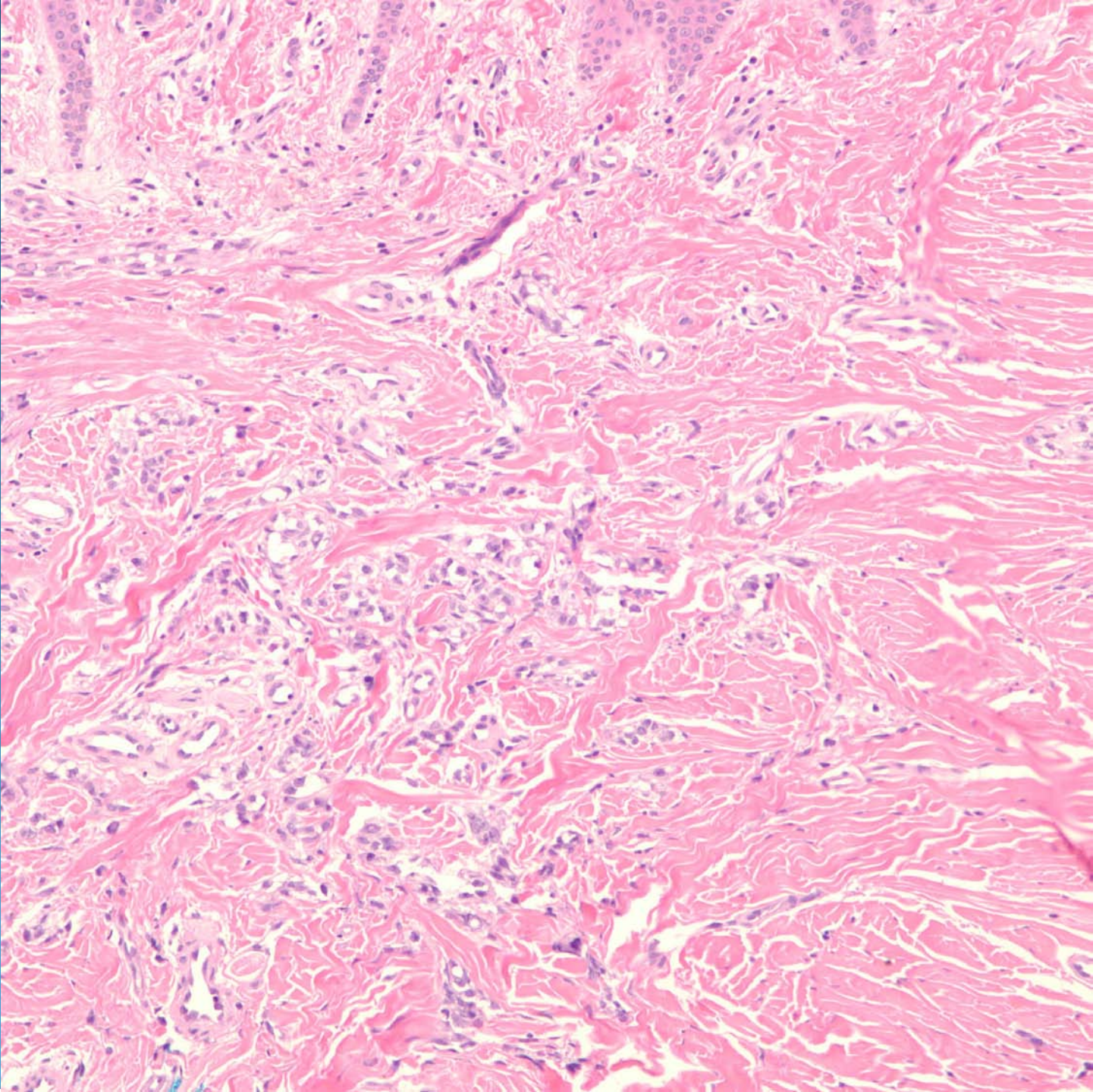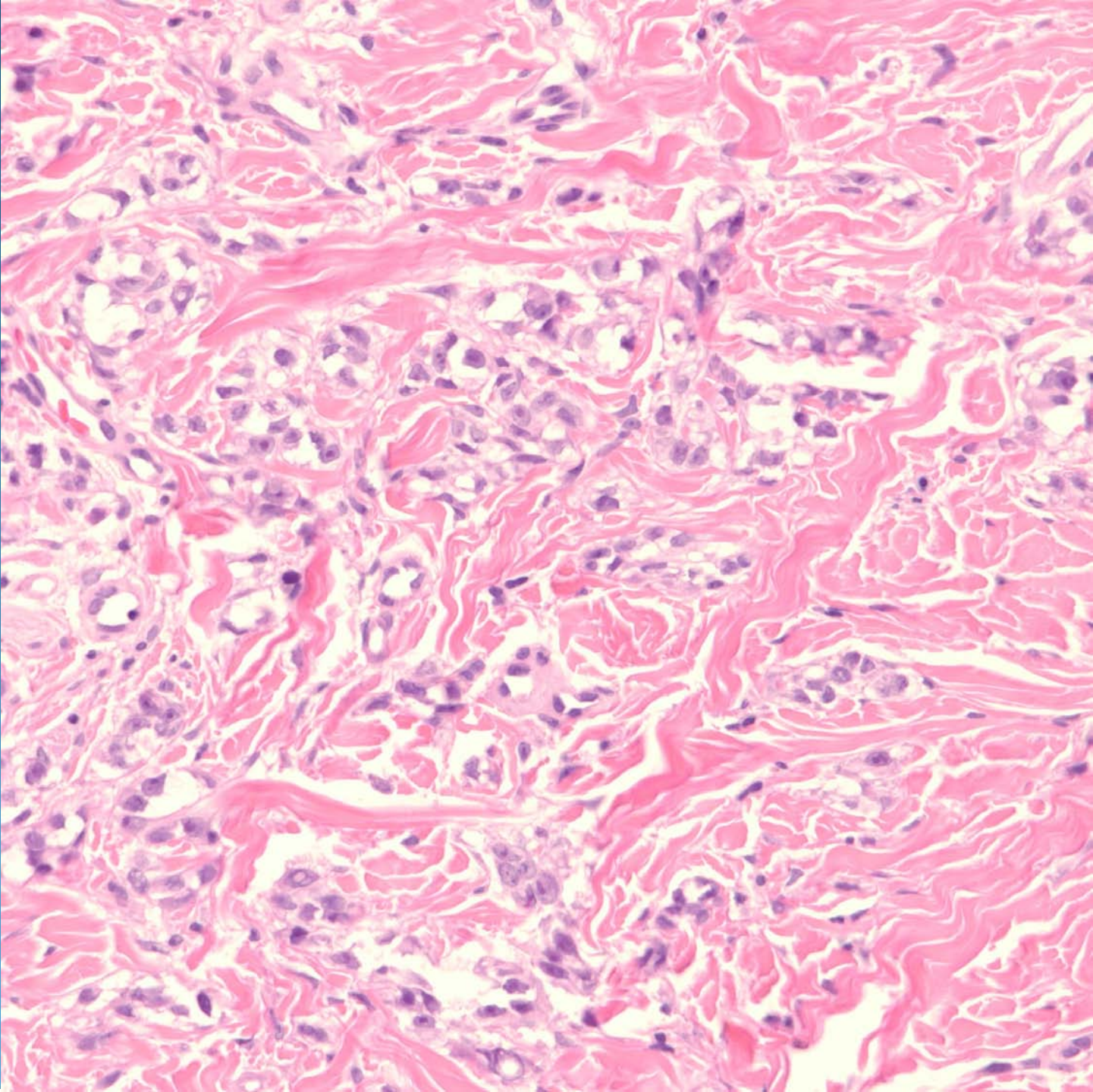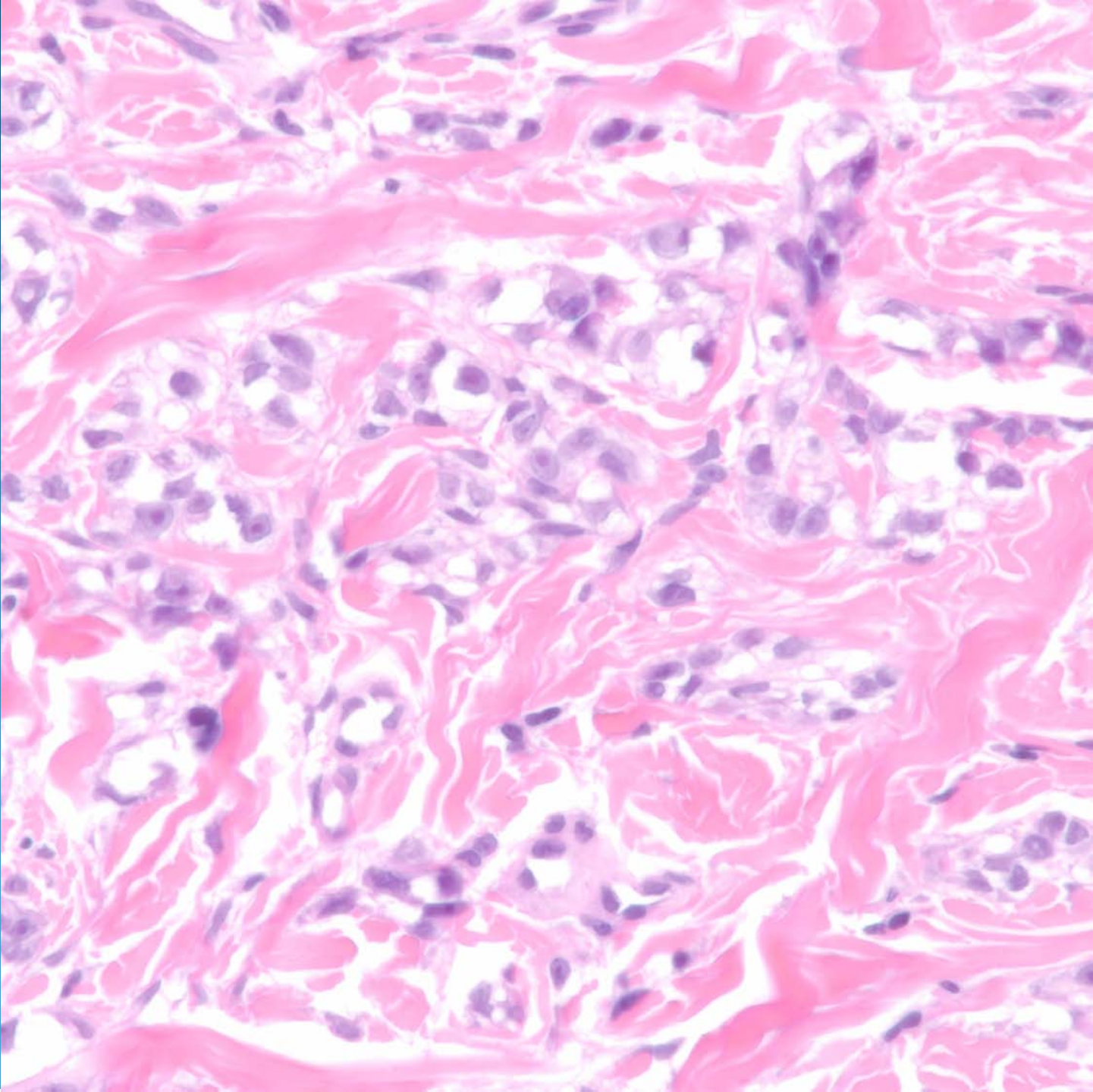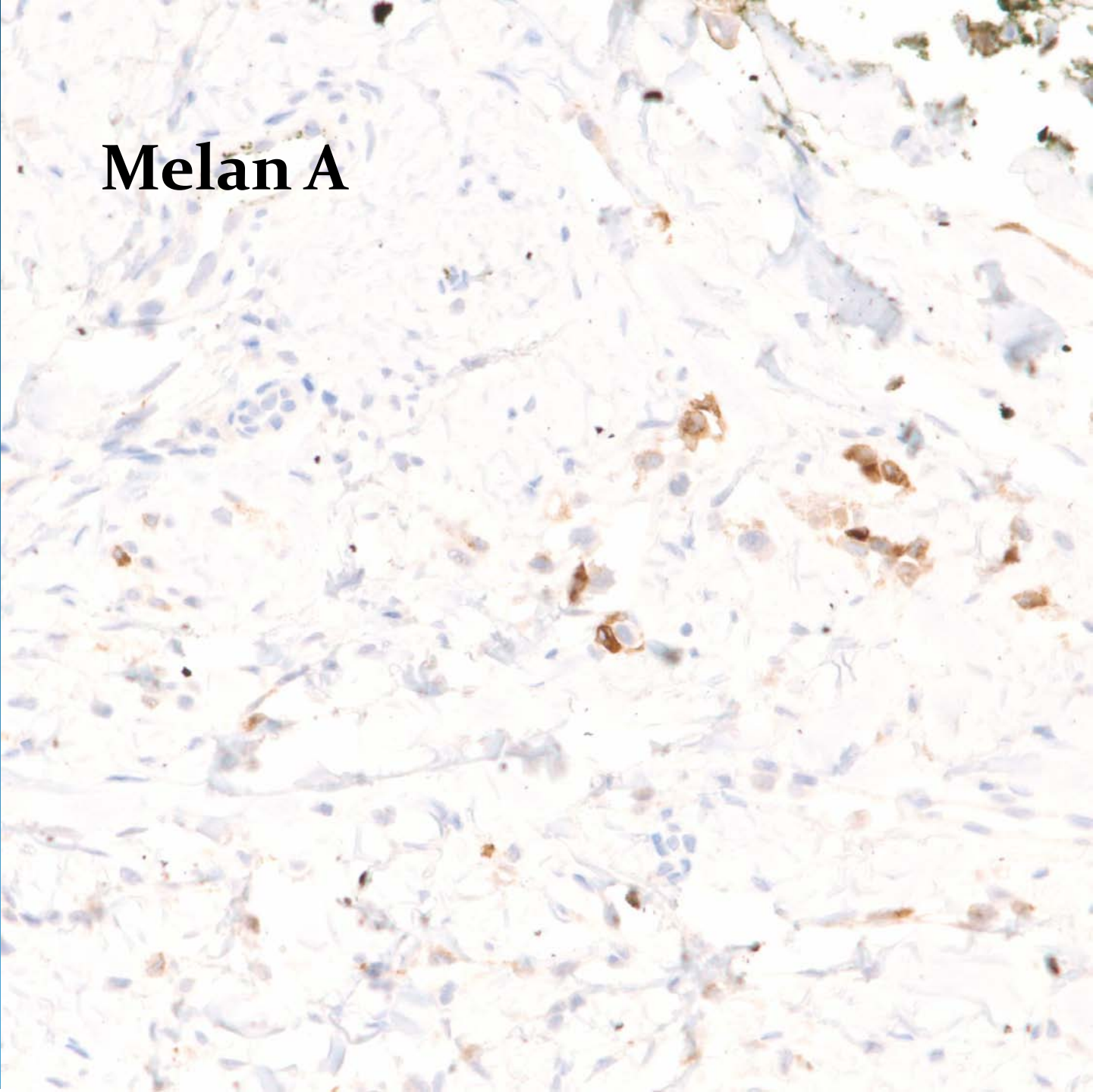
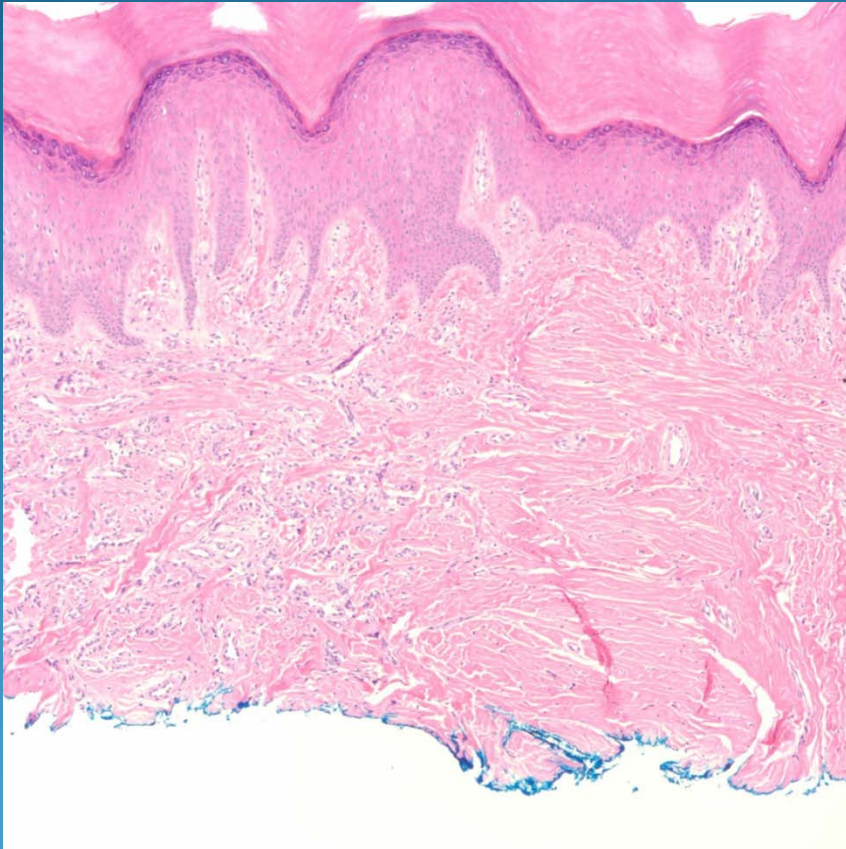


Melan A



Recurrent Malignant Melanoma

Pearls



- Low power of scar with adjacent pleomorphic cells
- Usually lacks junctional connection
- Melanoma cells may lack pigment
- May need to confirm with IHC