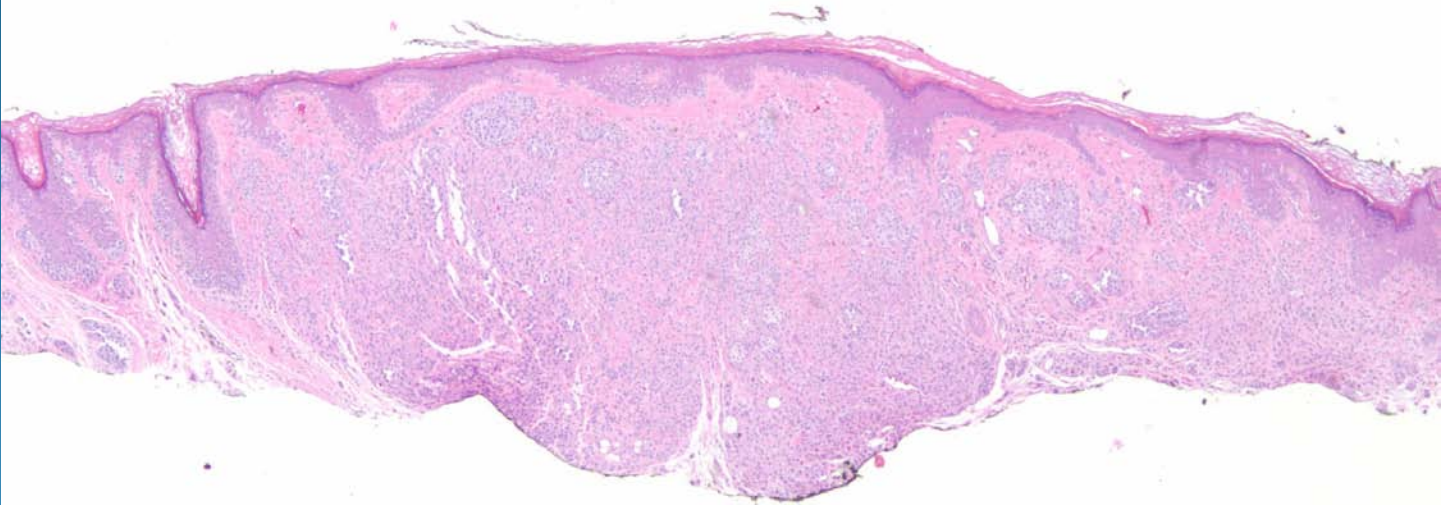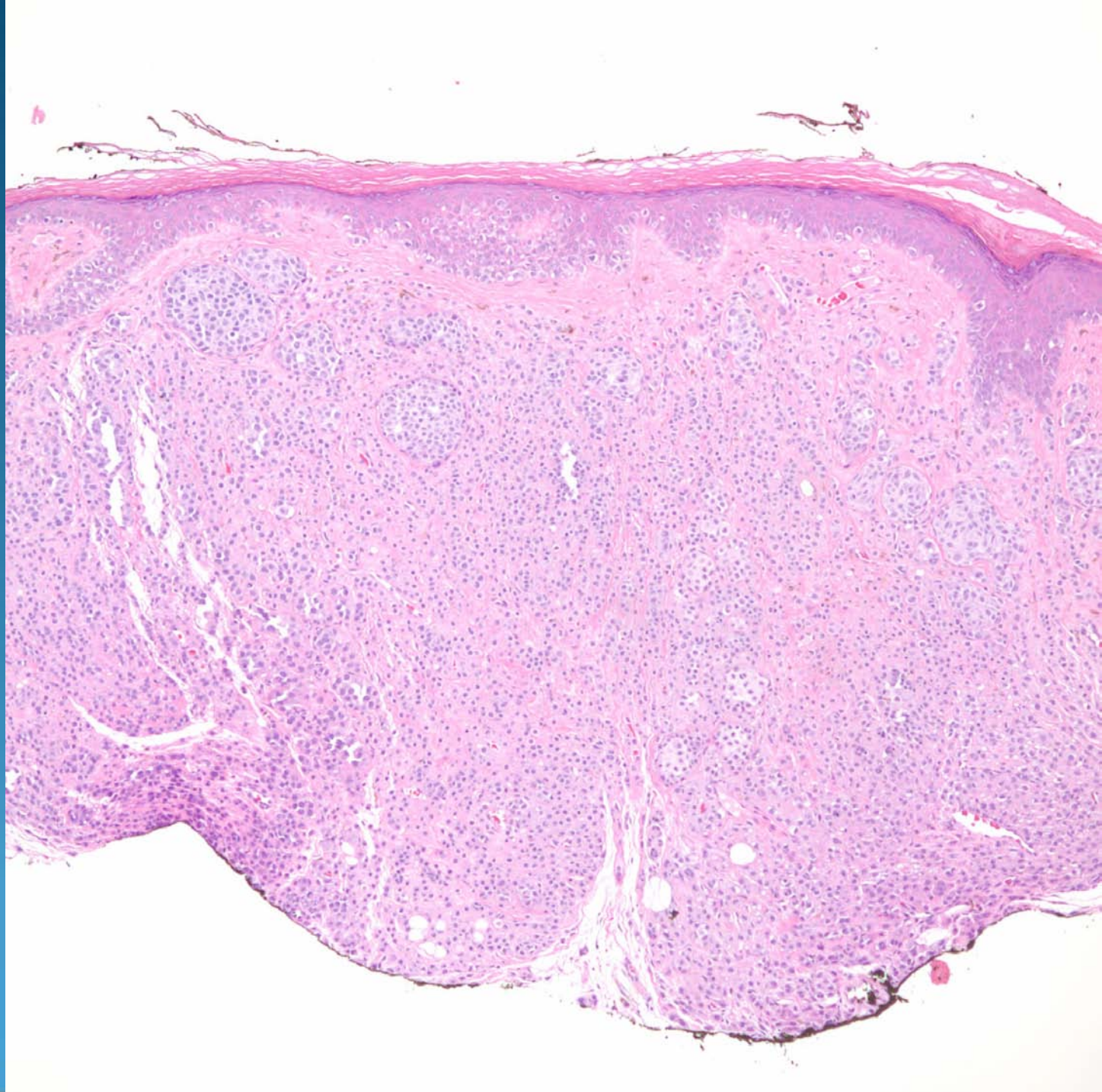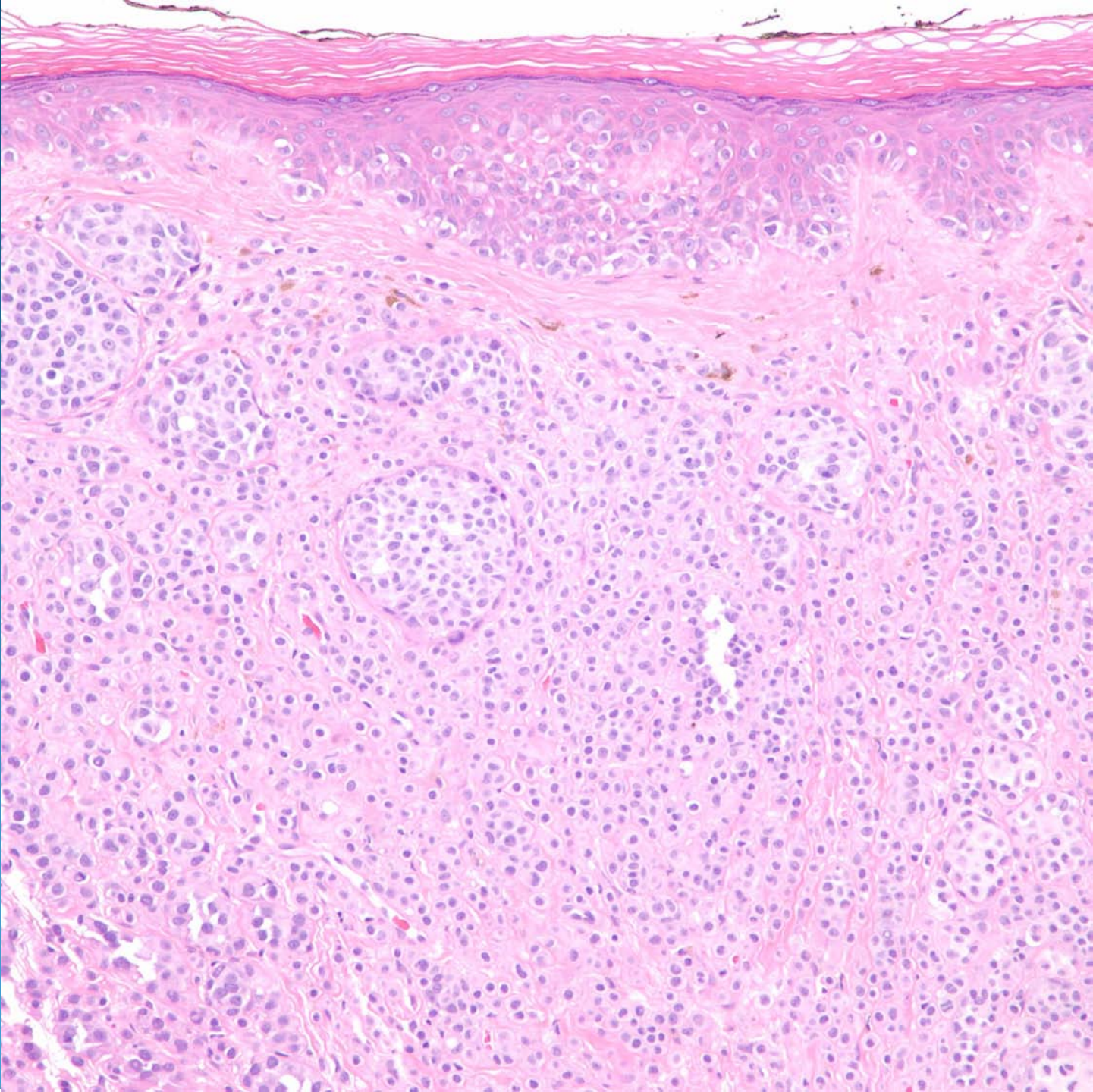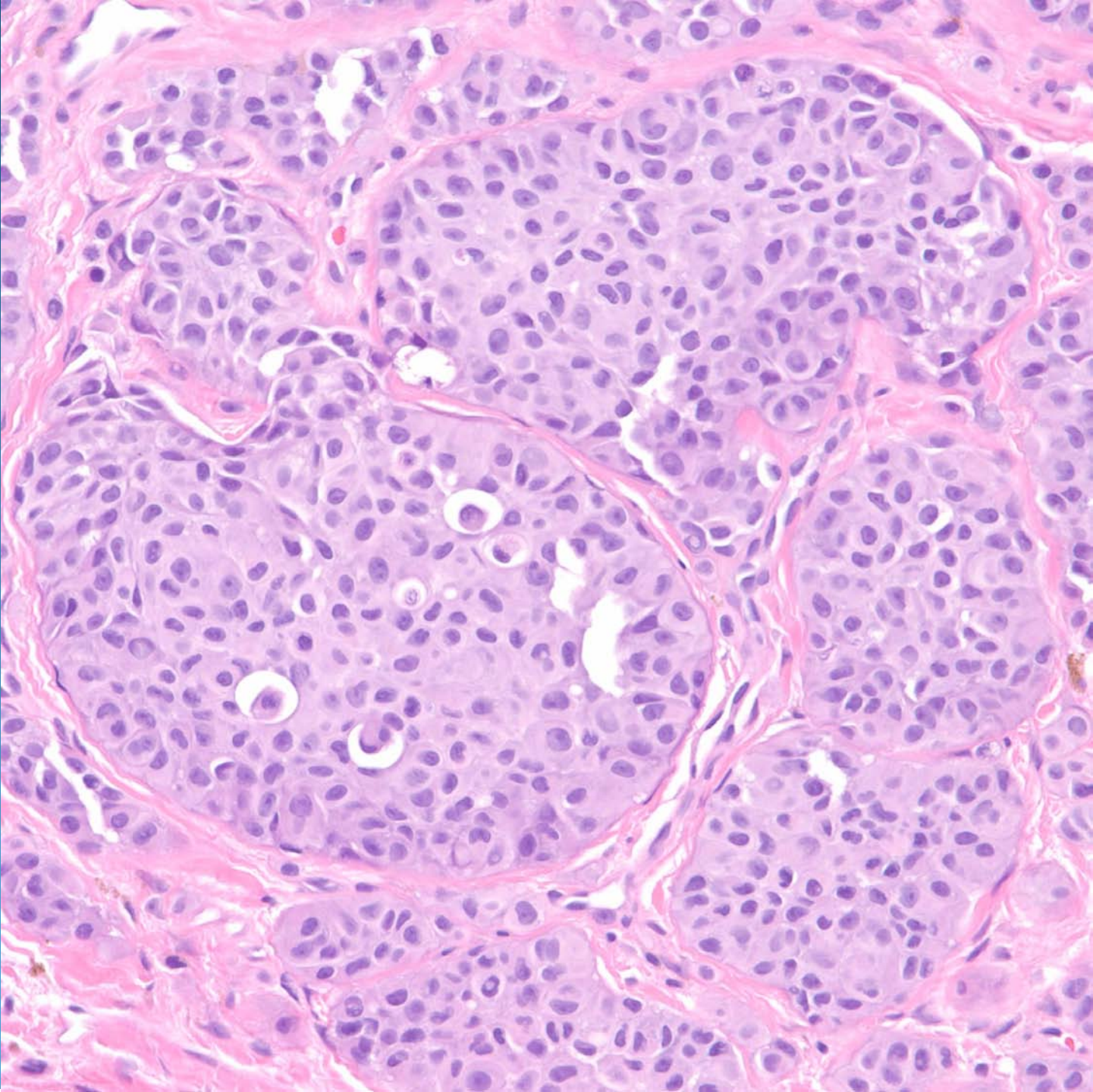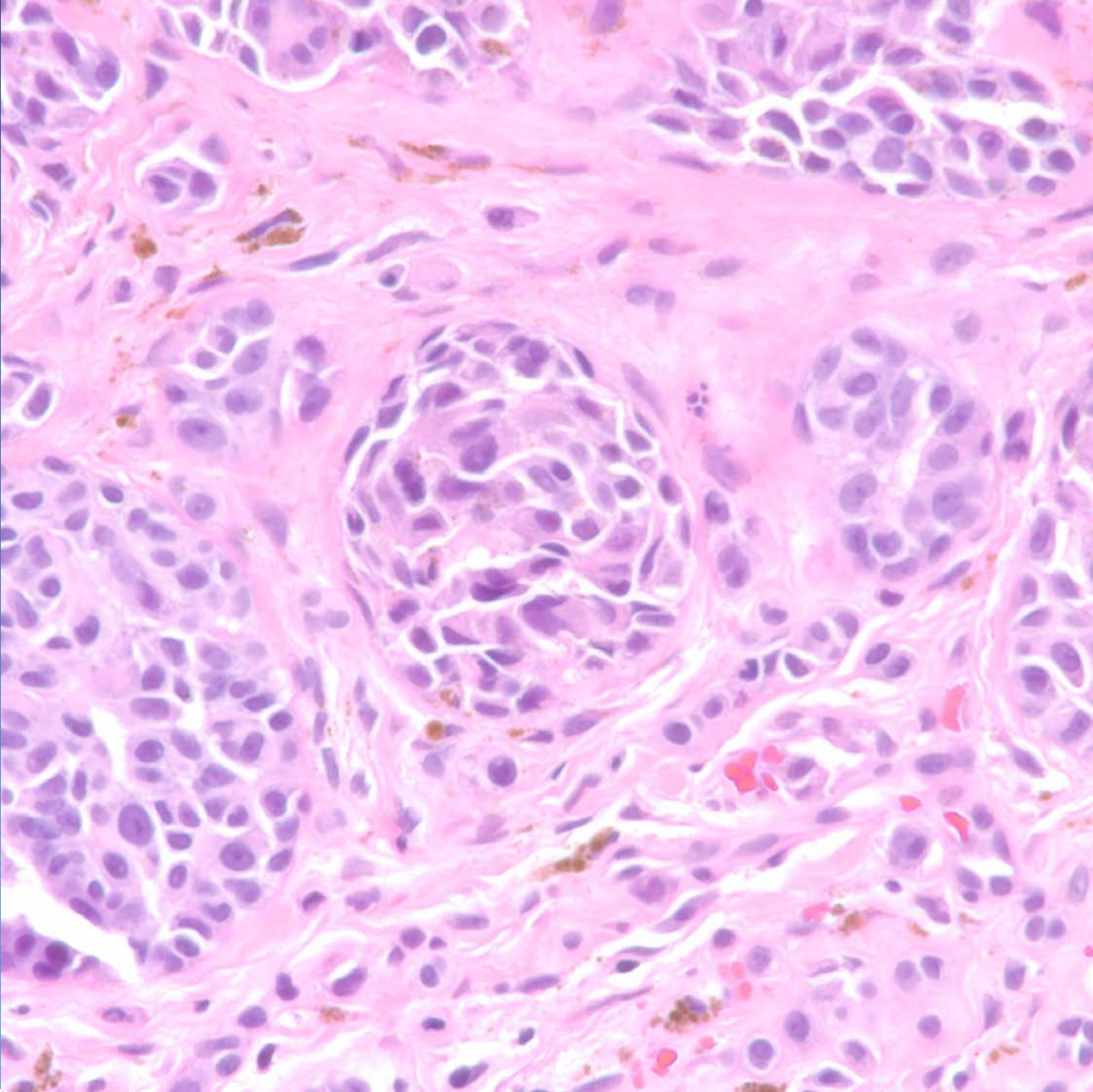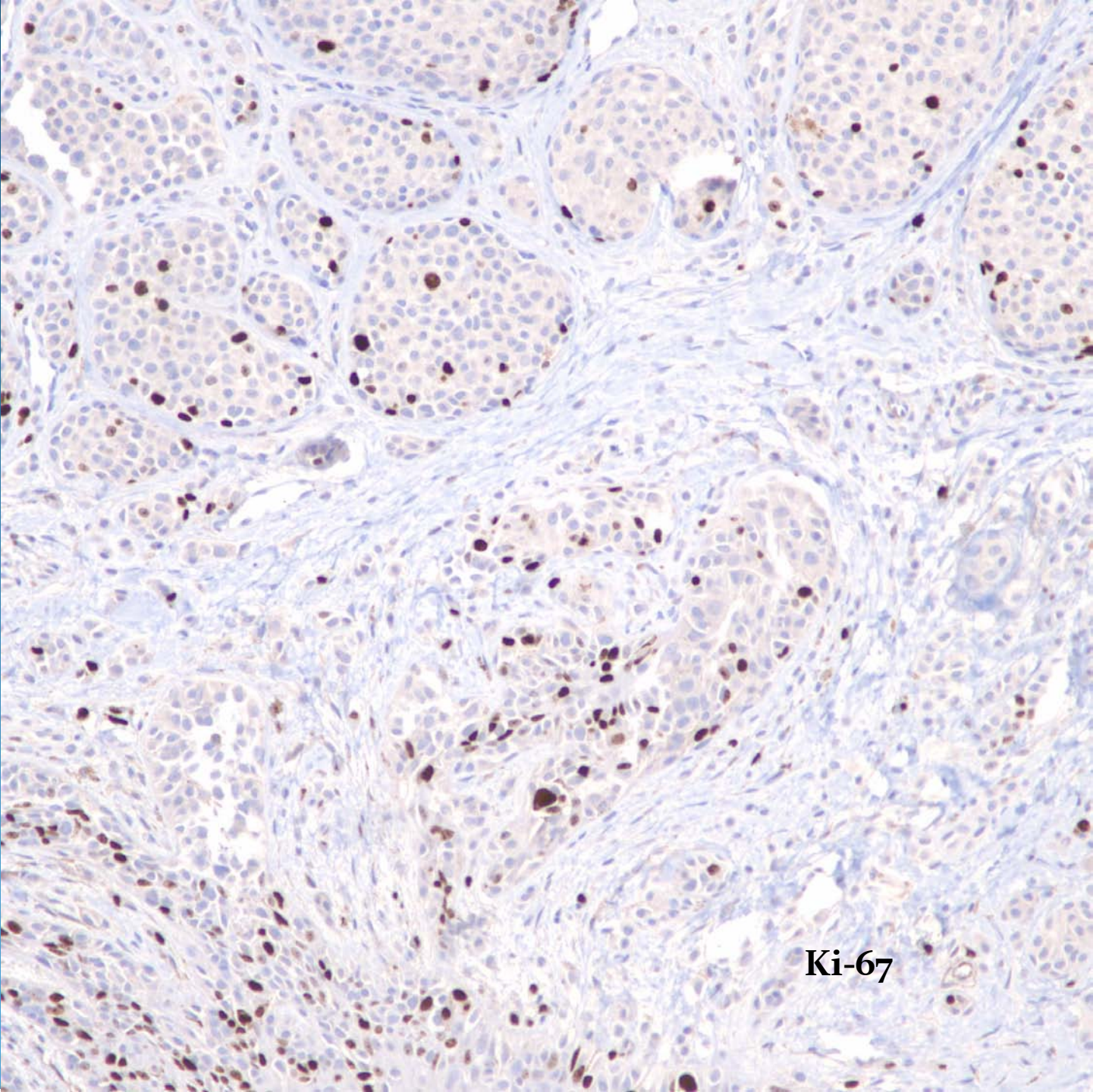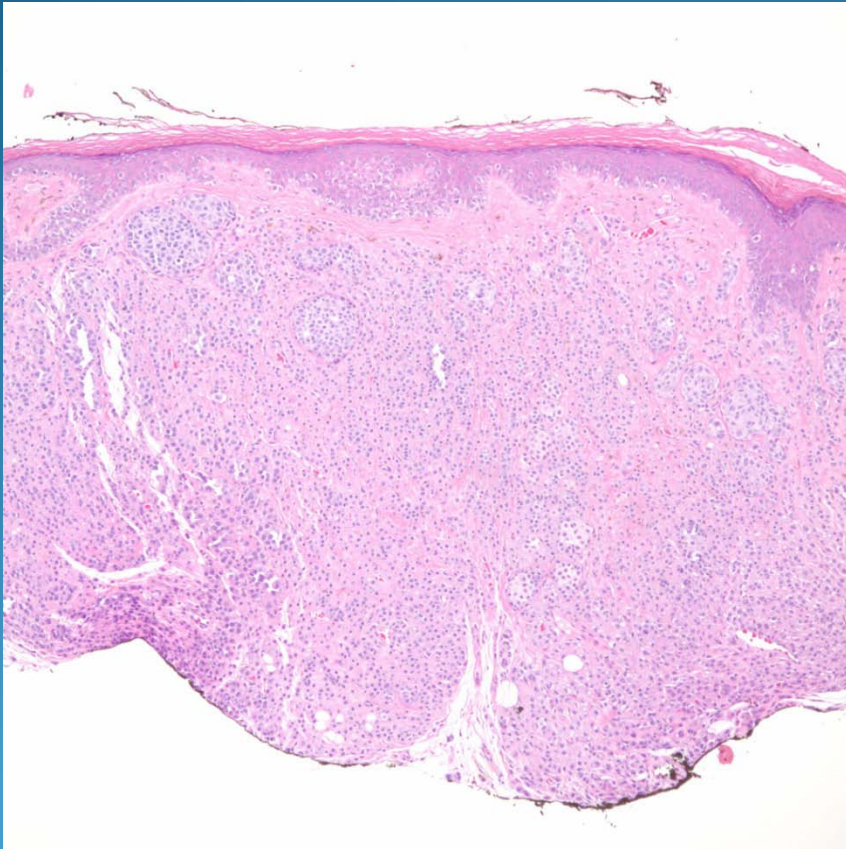


Ki-67

Malignant Melanoma Nevoid Type

Pearls



- Silhouette of benign melanocytic nevus
- Solid confluent growth pattern of melanocytes with no maturation
- Cytologically atypical melanocytes at base of lesion with prominent nucleoli and deep mitotic figures