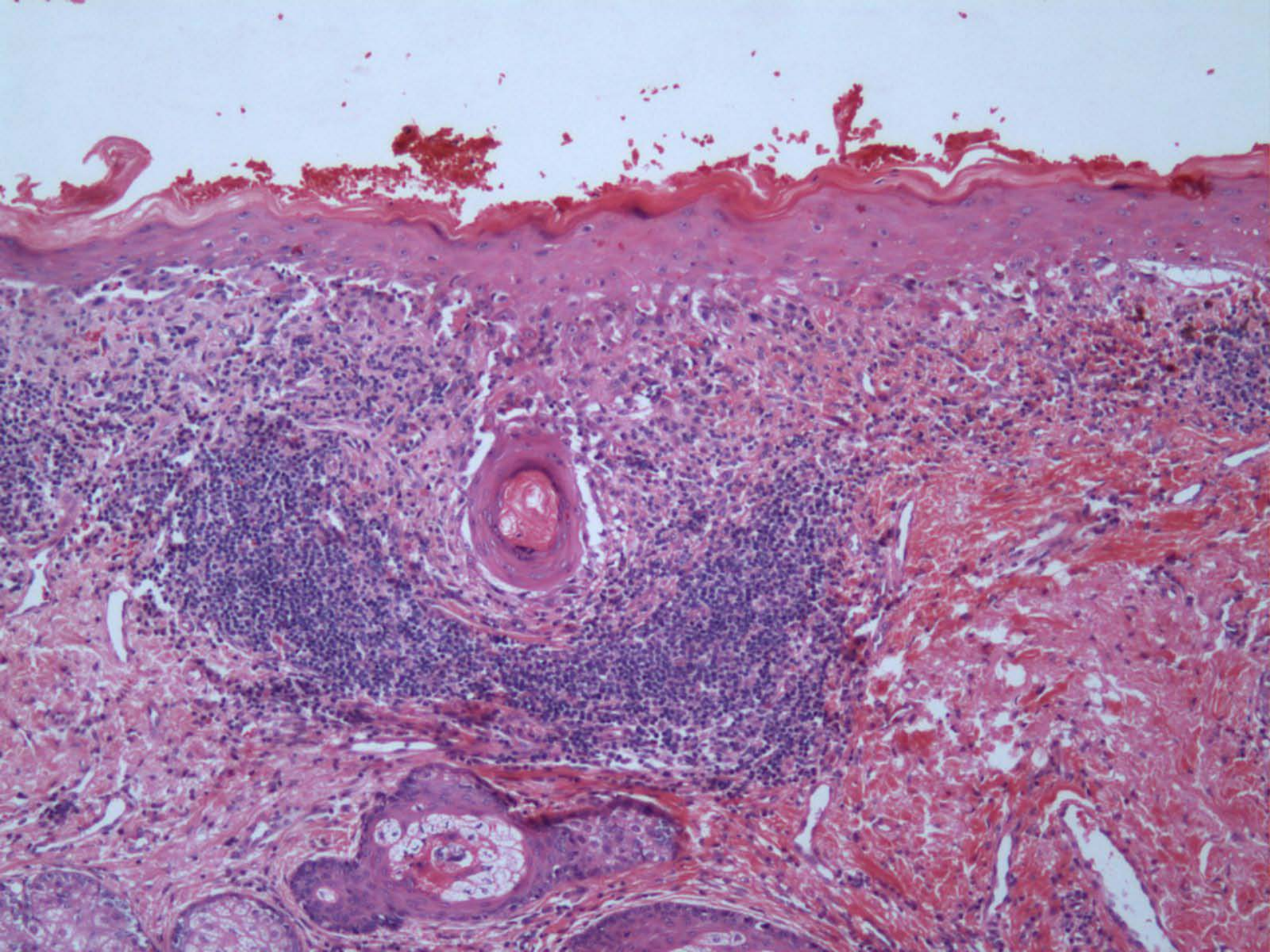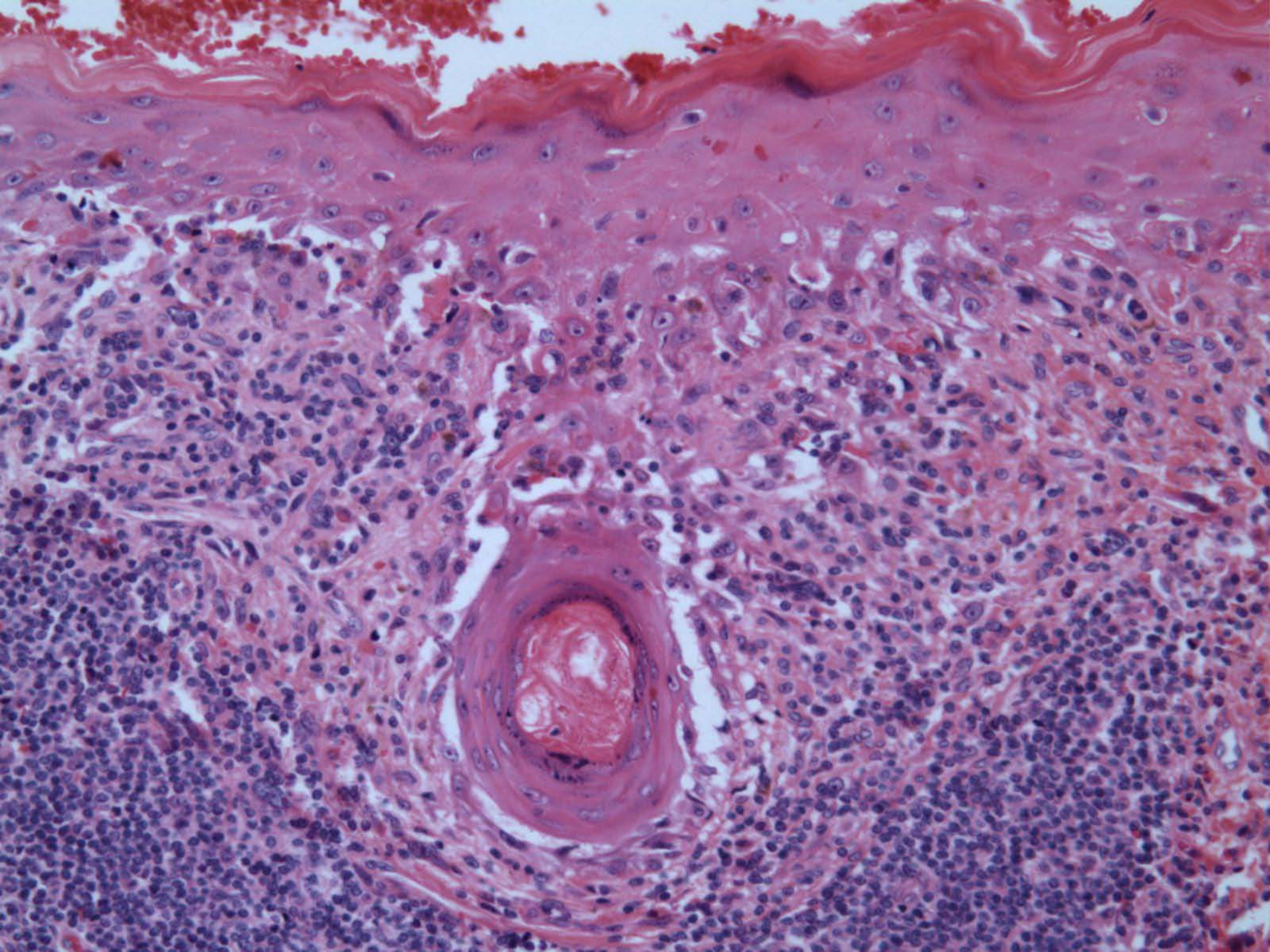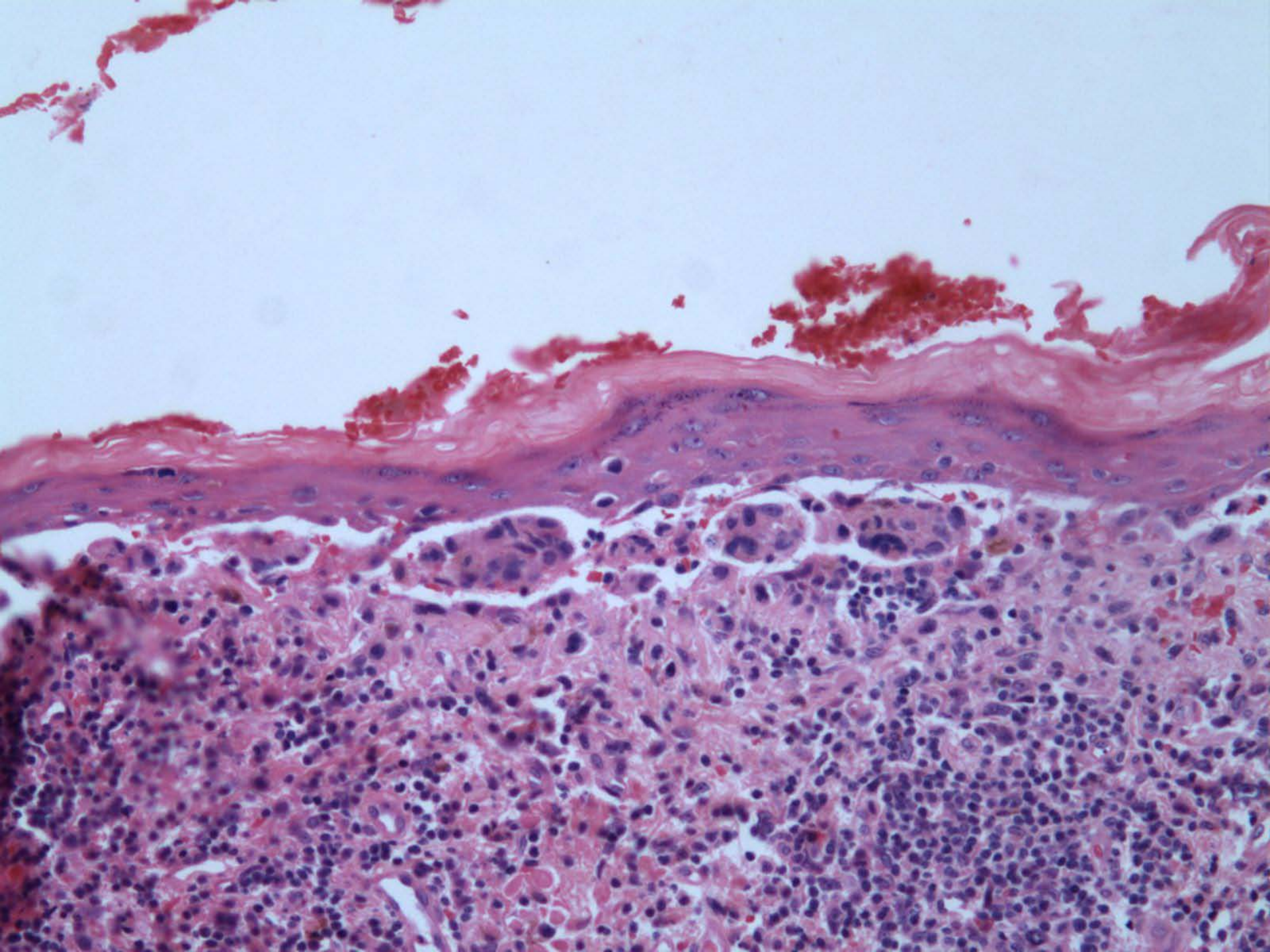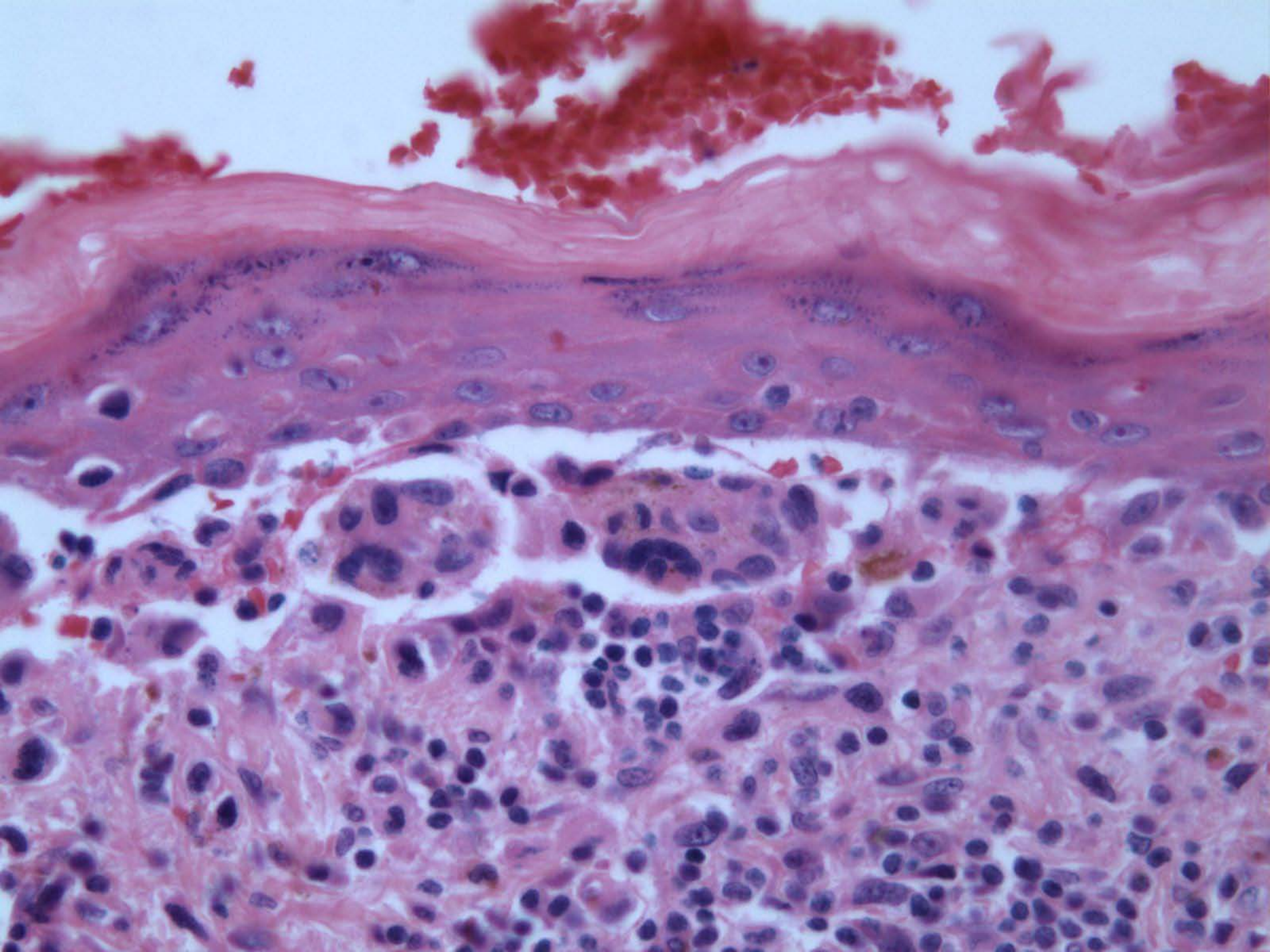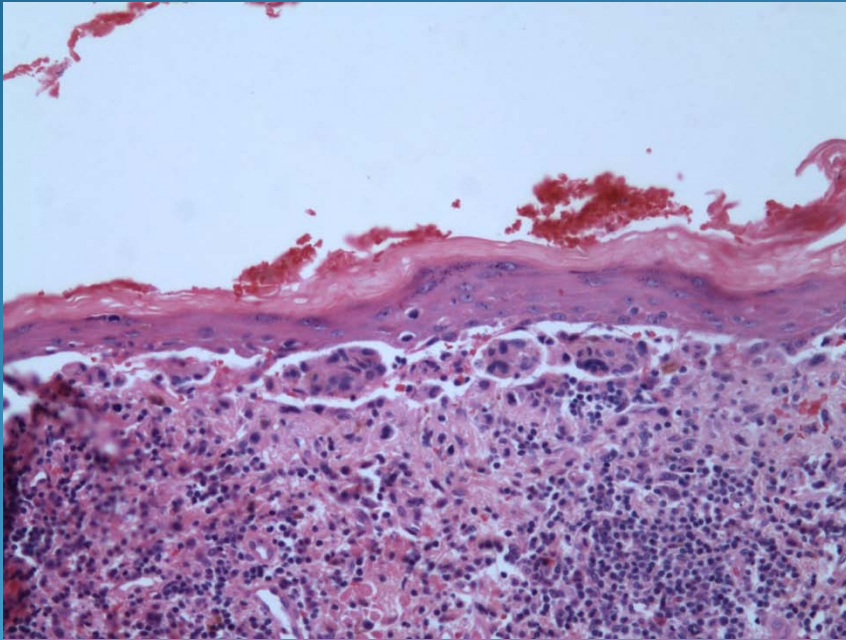


Malignant Melanoma

-Lentigo Maligna

Pearls



- Confluent and discohesive nests of melanocytes arranged at the dermal epidermal junction
- Extension along follicular epithelium
- Thinned epidermis
- Pagetoid spread not always present
- Severe solar elastosis