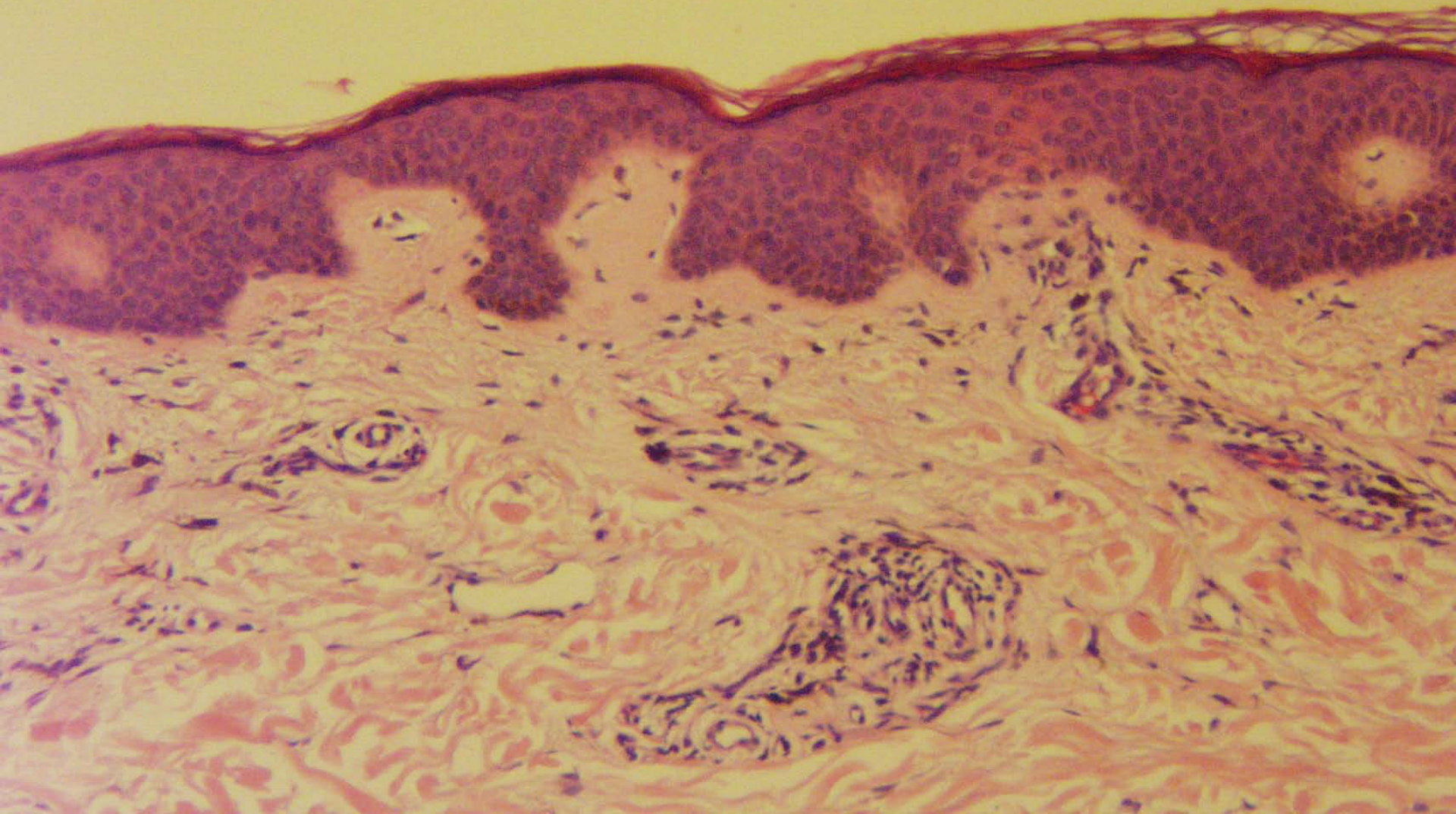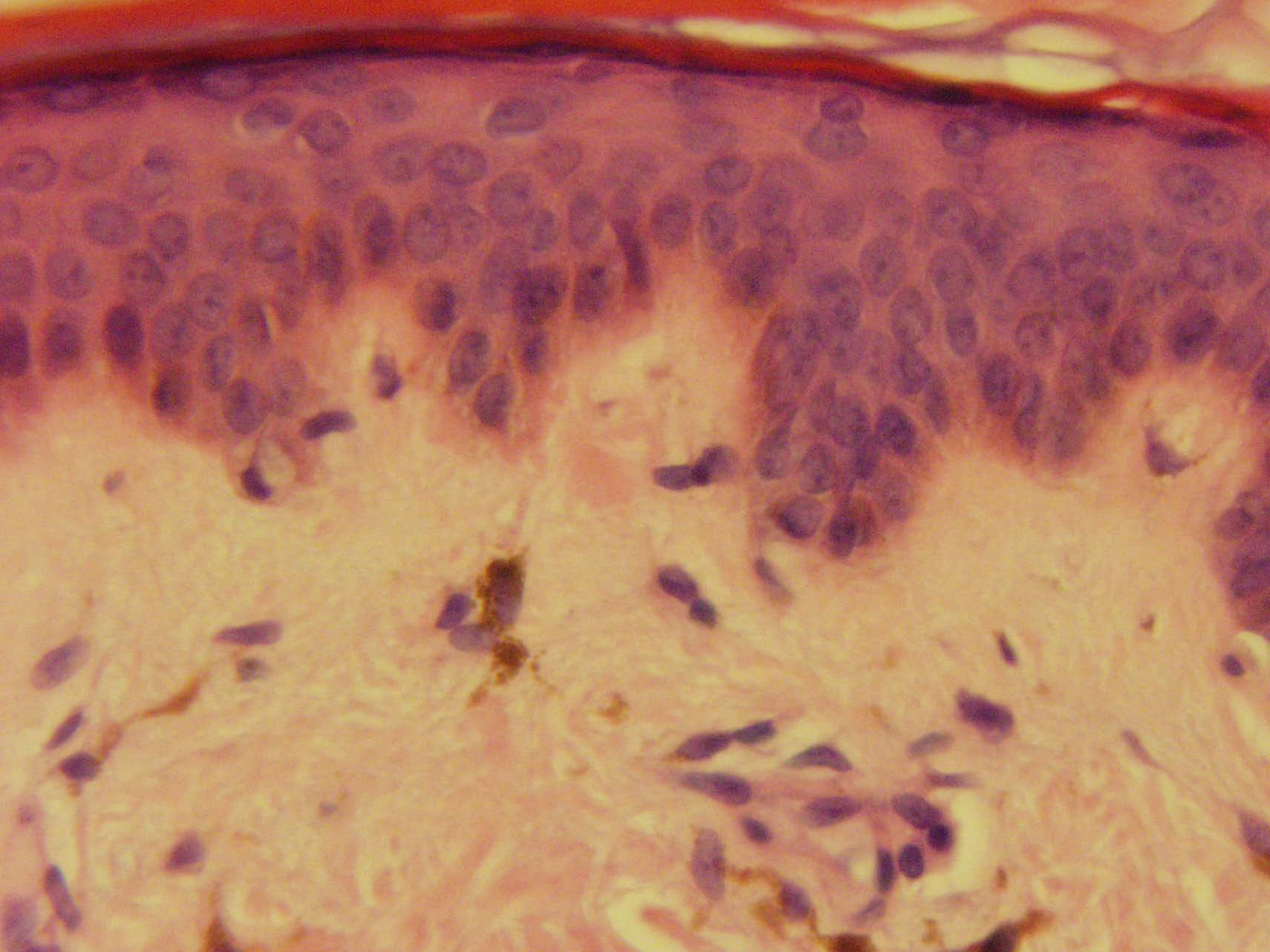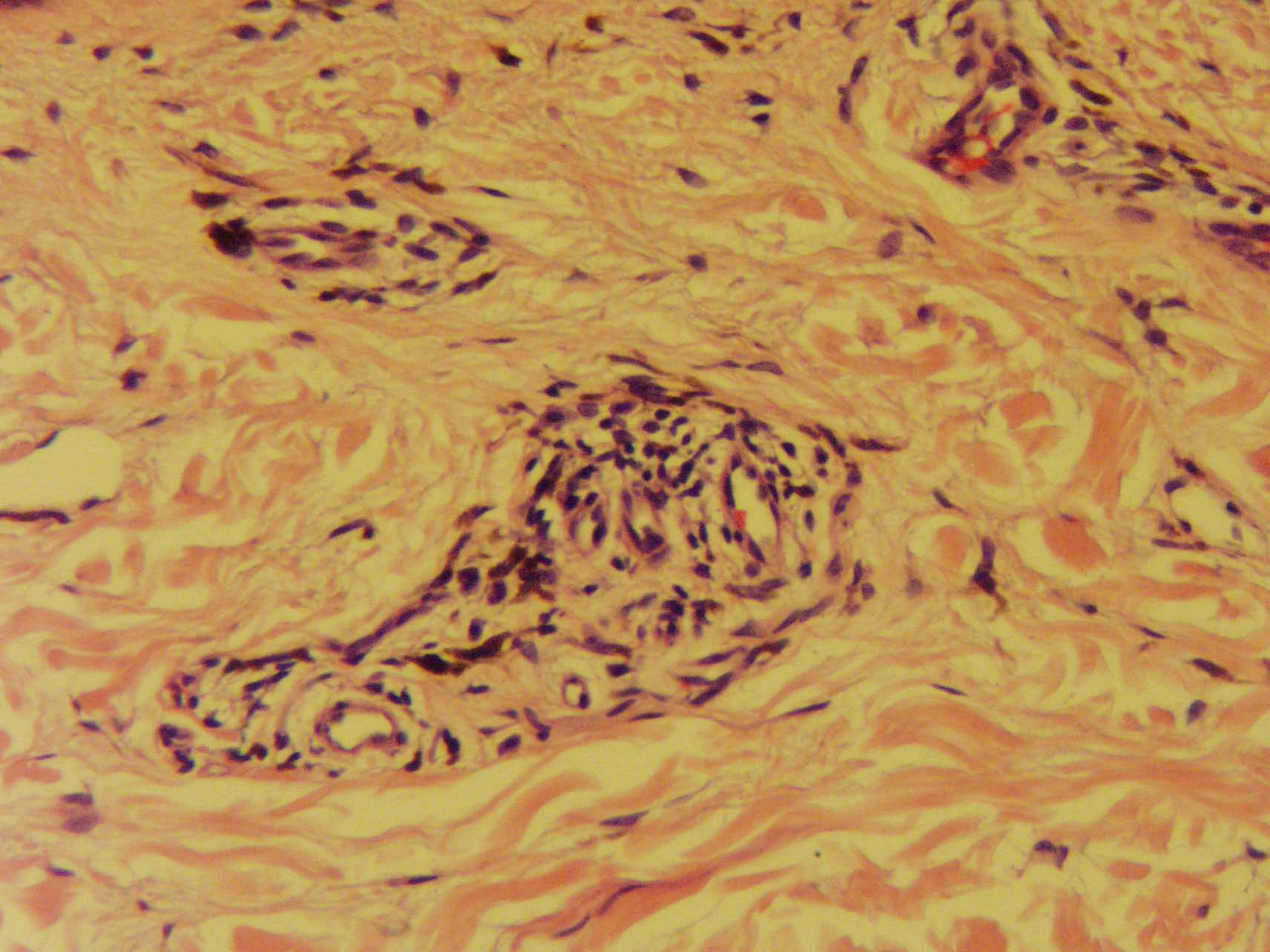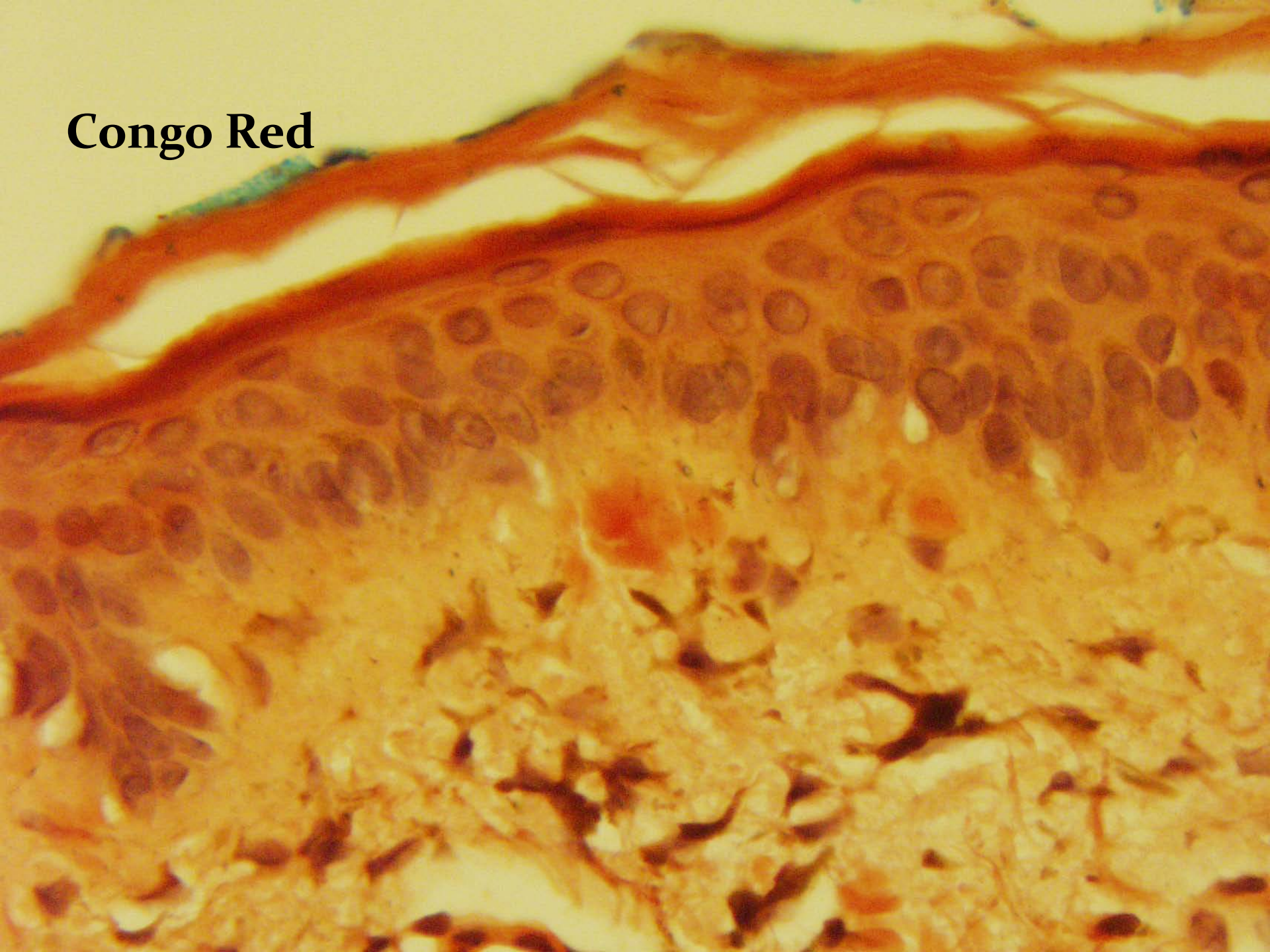
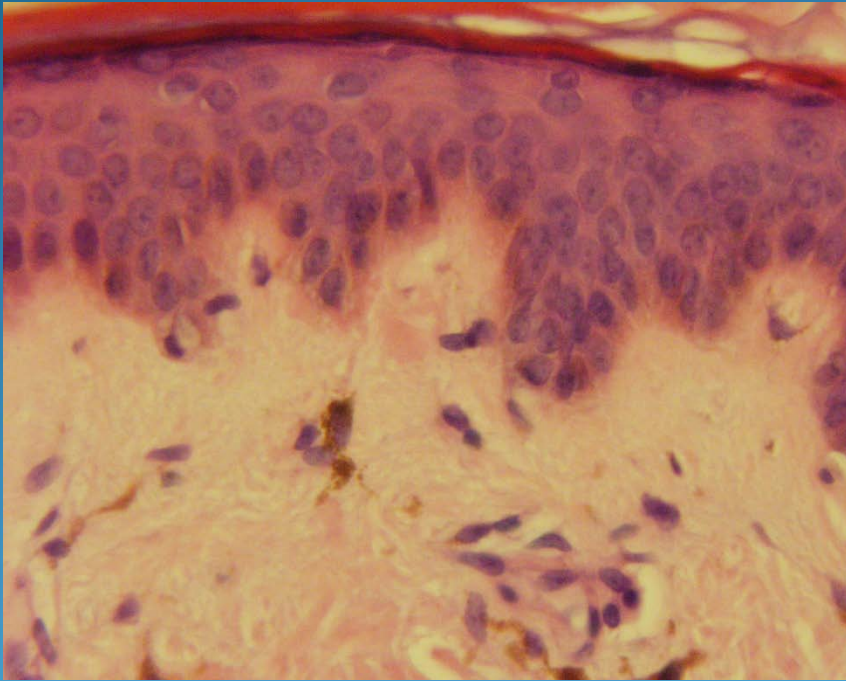


Macular Amyloid

Congo Red



Pearls



- Amyloid hyaline globules at the dermal-epidermal junction
- Scattered melanophages