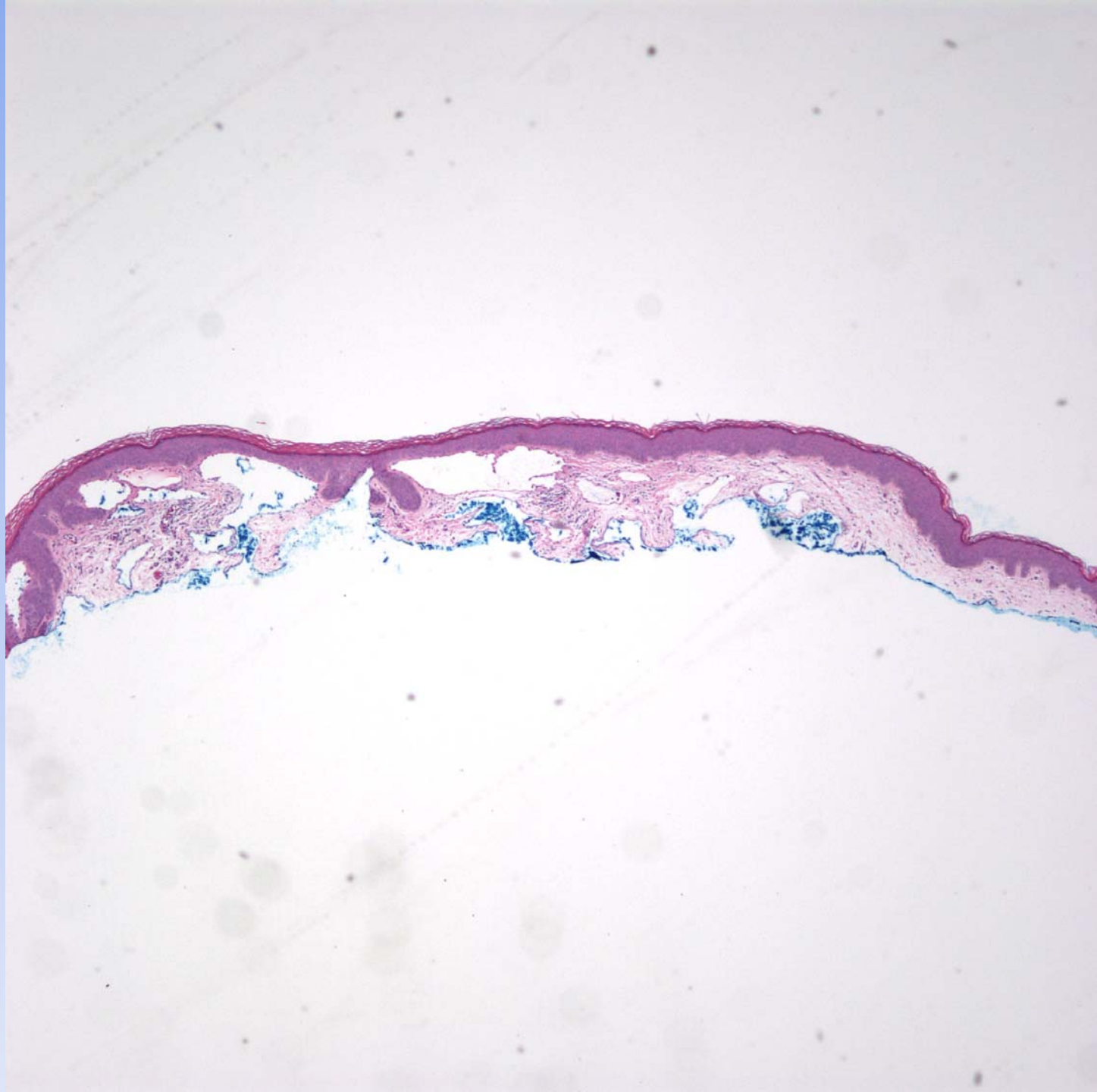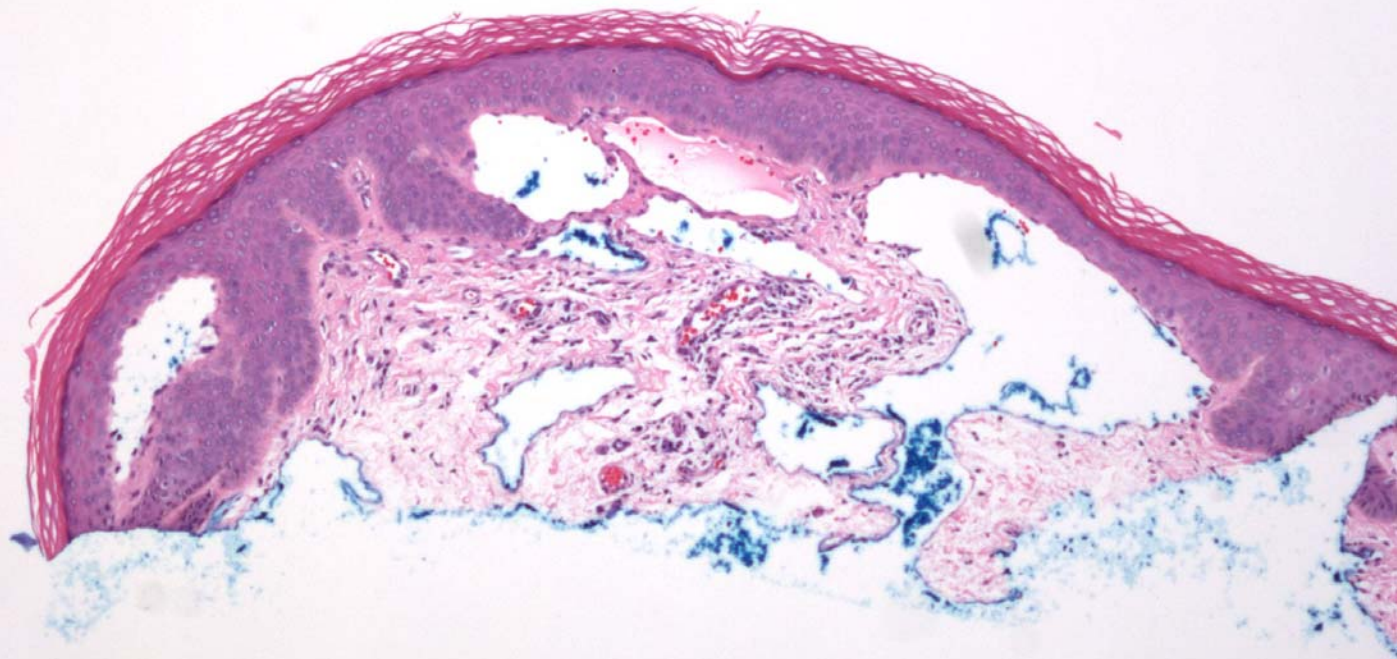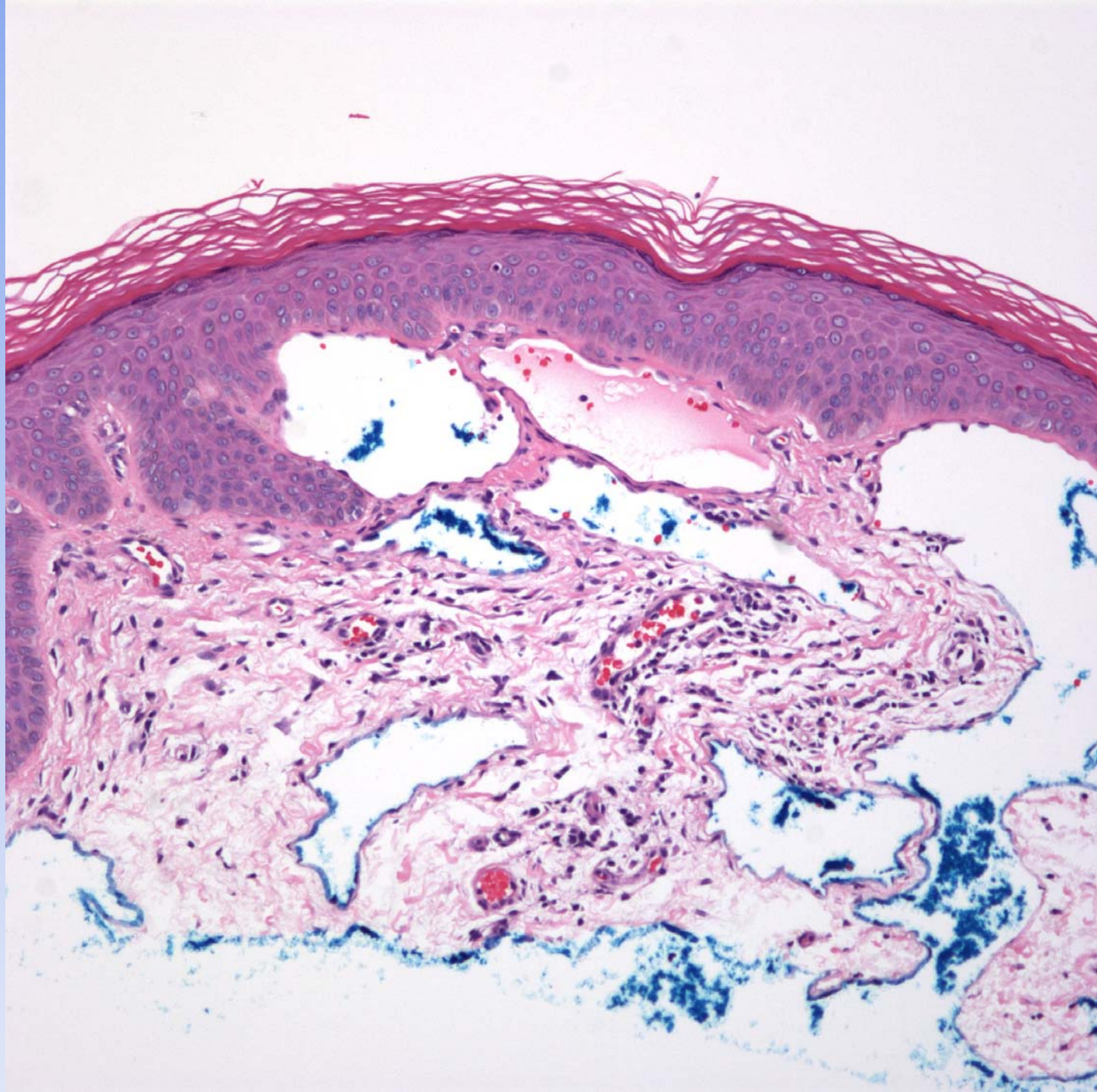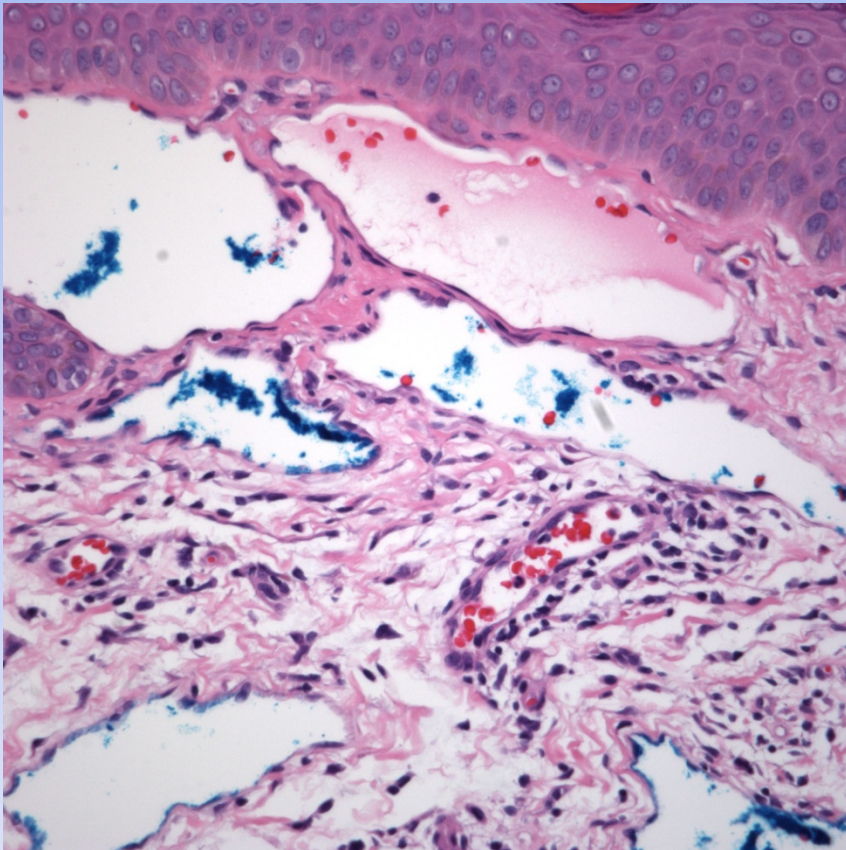






# Lymphangioma

# Pearls



- Ectatic vascular spaces lined by bland endothelial cells
- Lumen contains lymph with minimal rbc's
- Soft tissue lesions may be extensively infiltrative