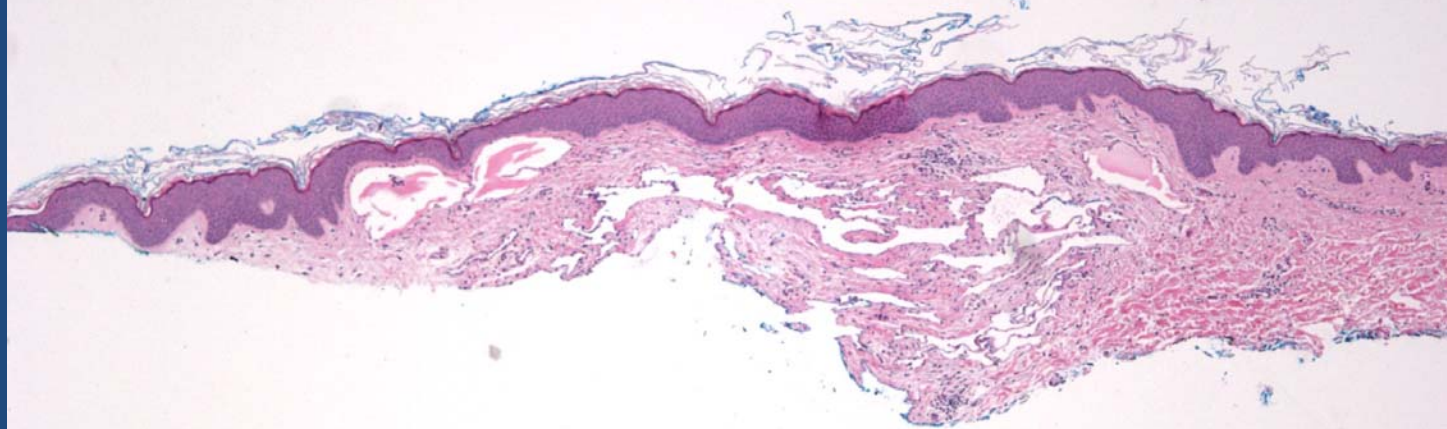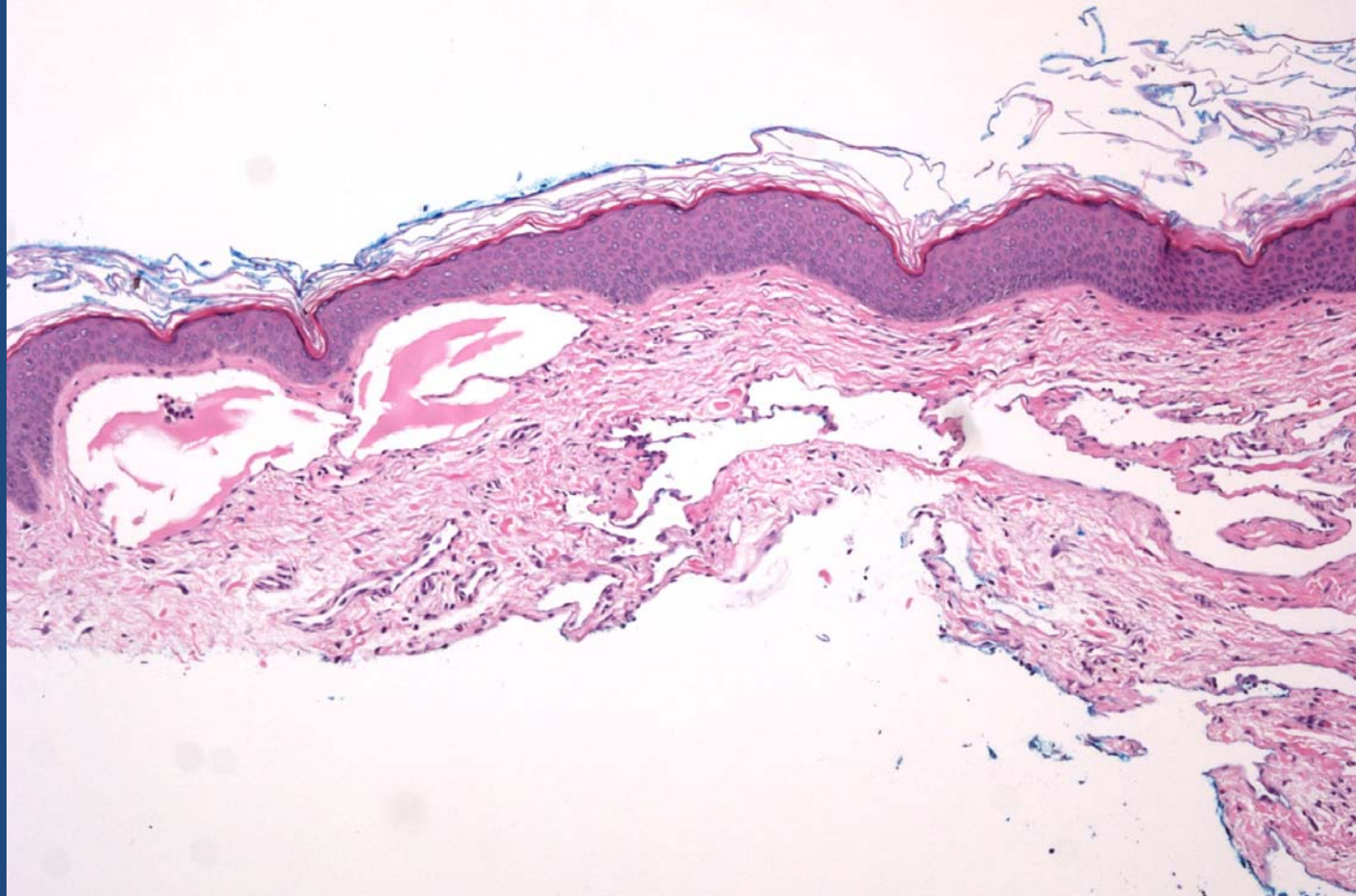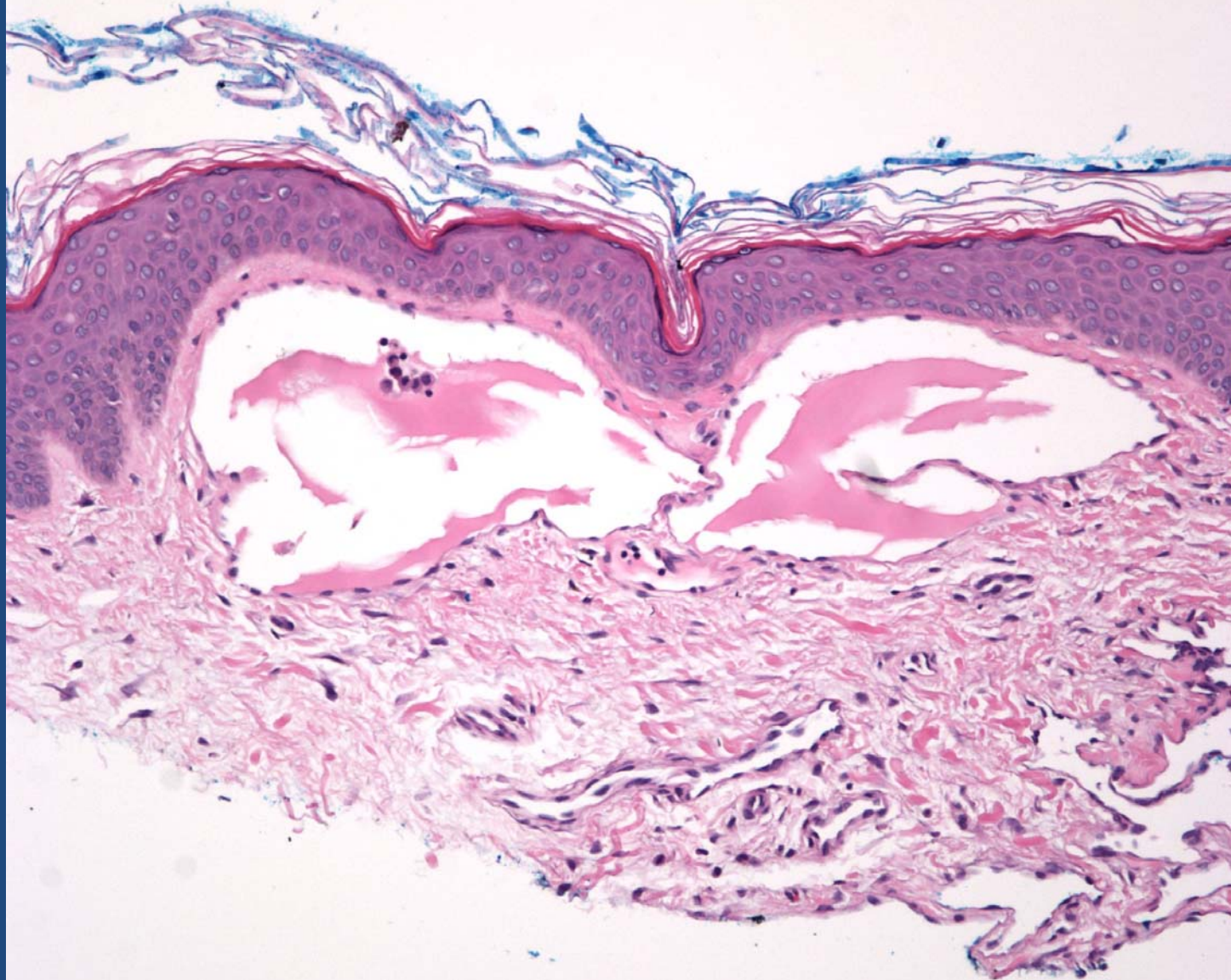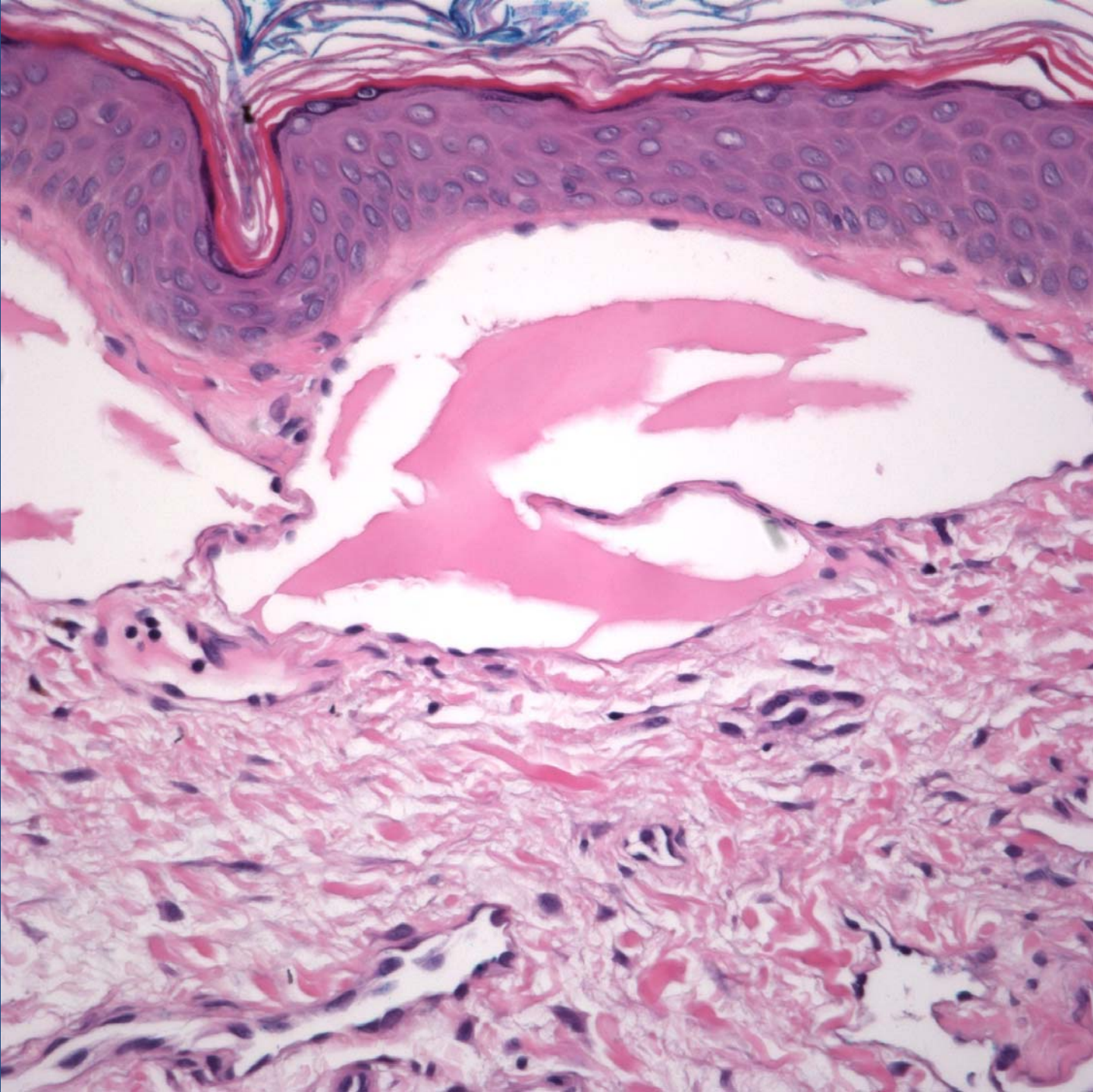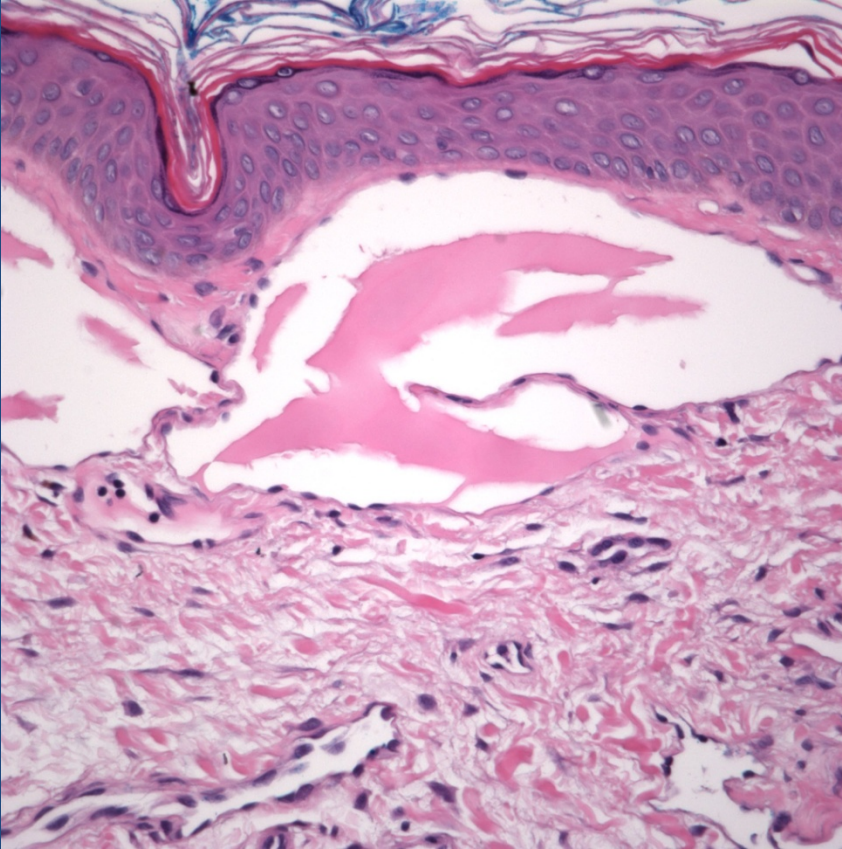


Lymphangioma

Pearls



- Ectatic vascular spaces lined by bland endothelial cells
- Proteinaceous serum, usually minimal rbc