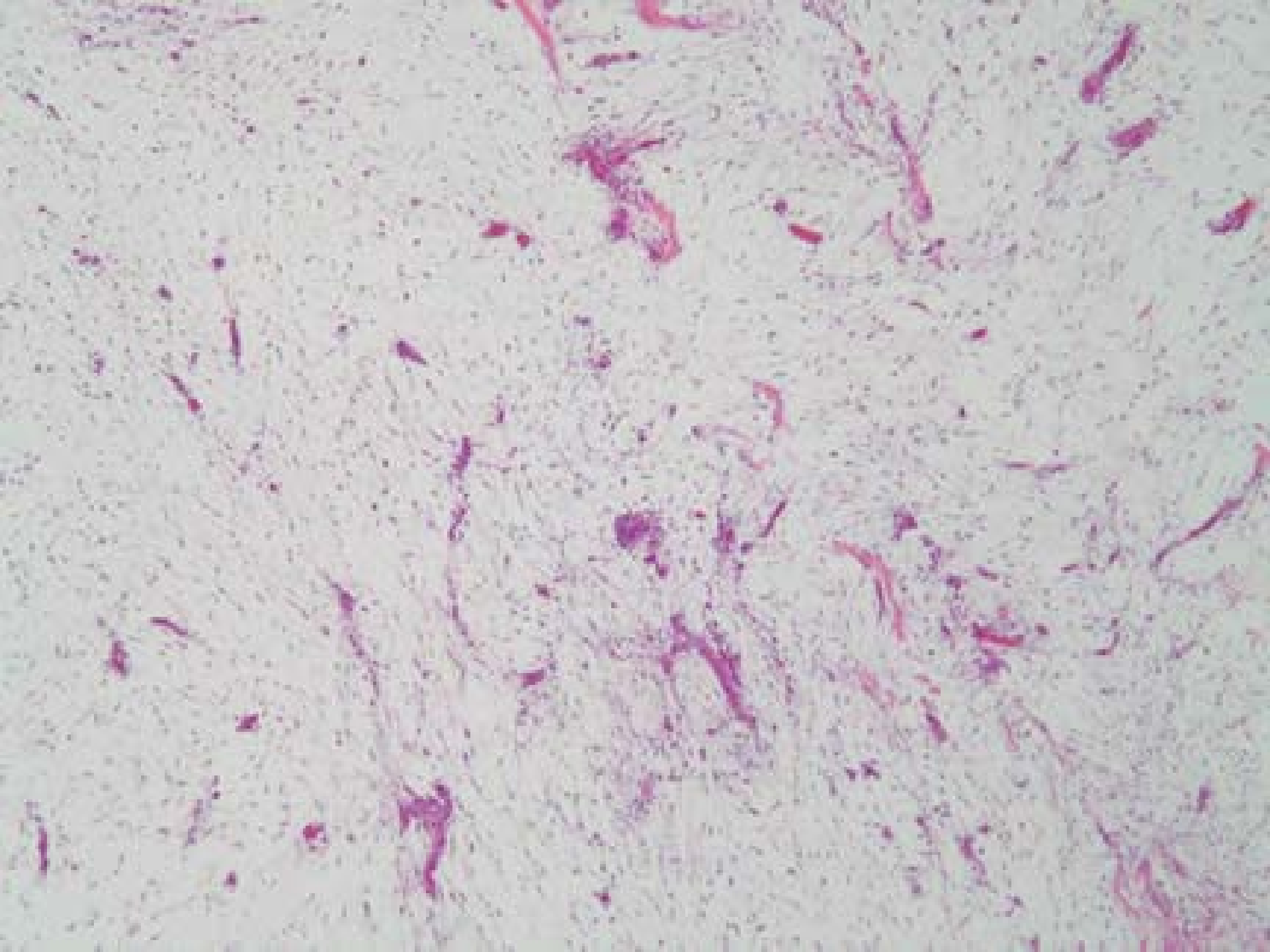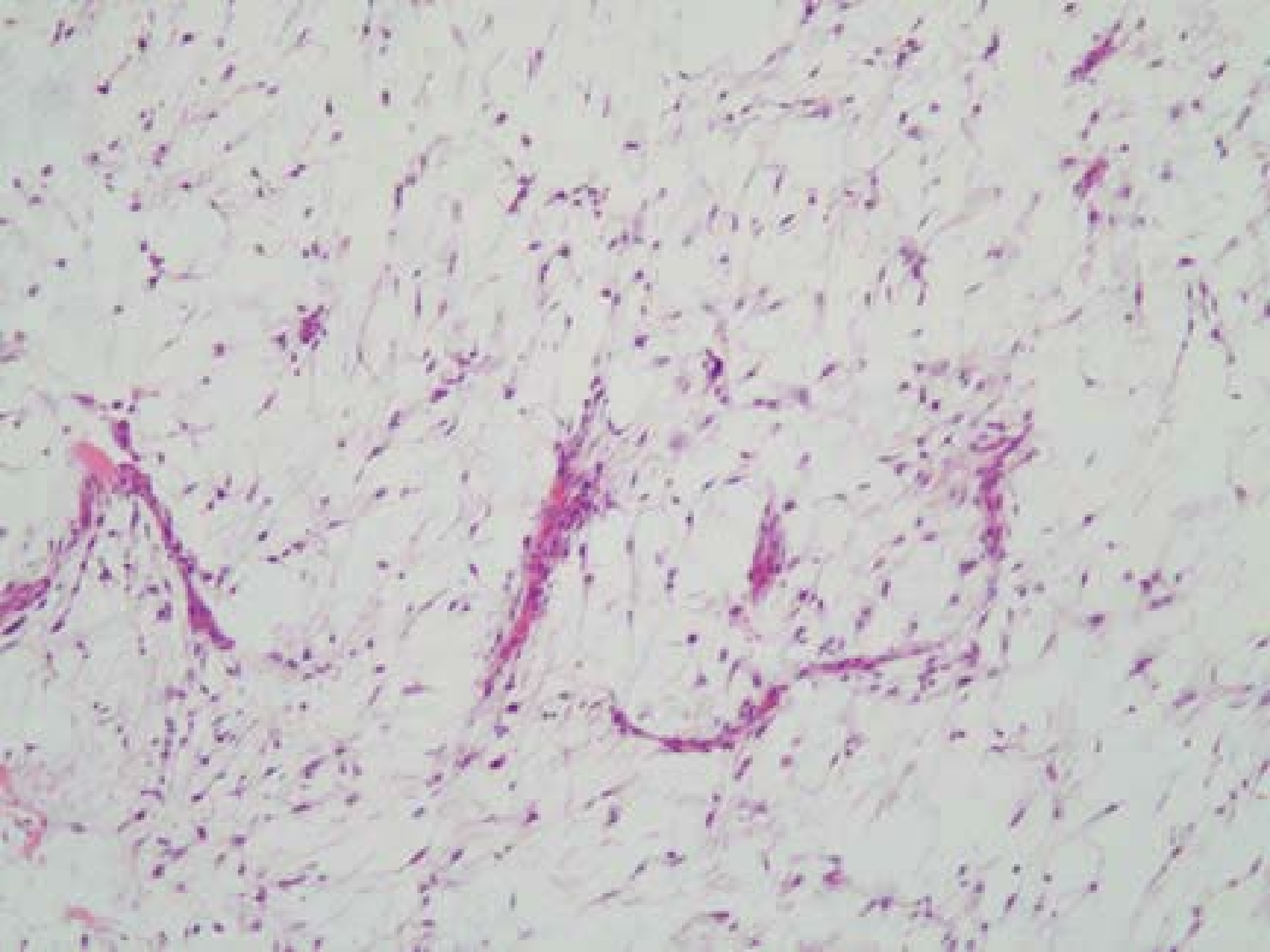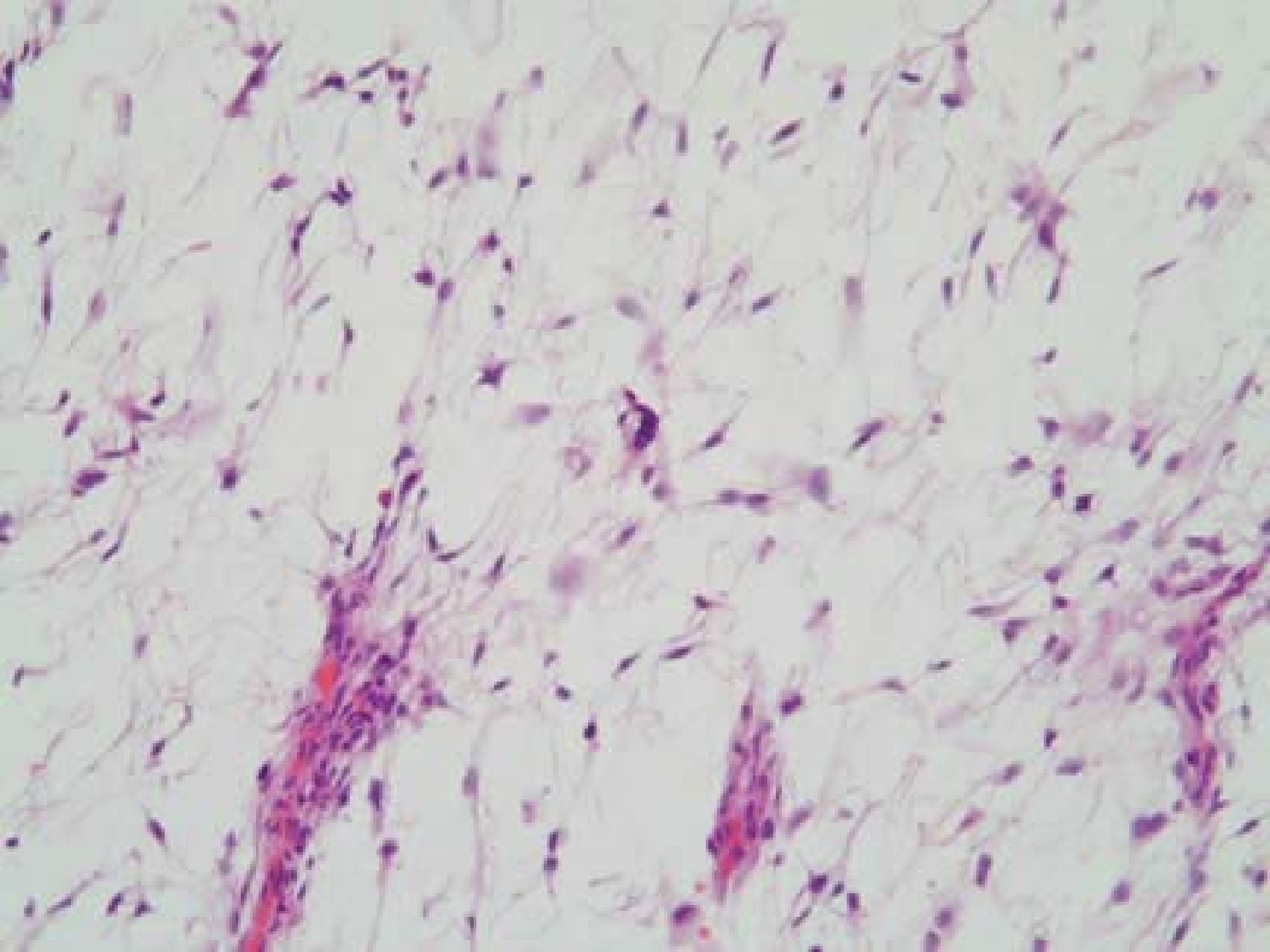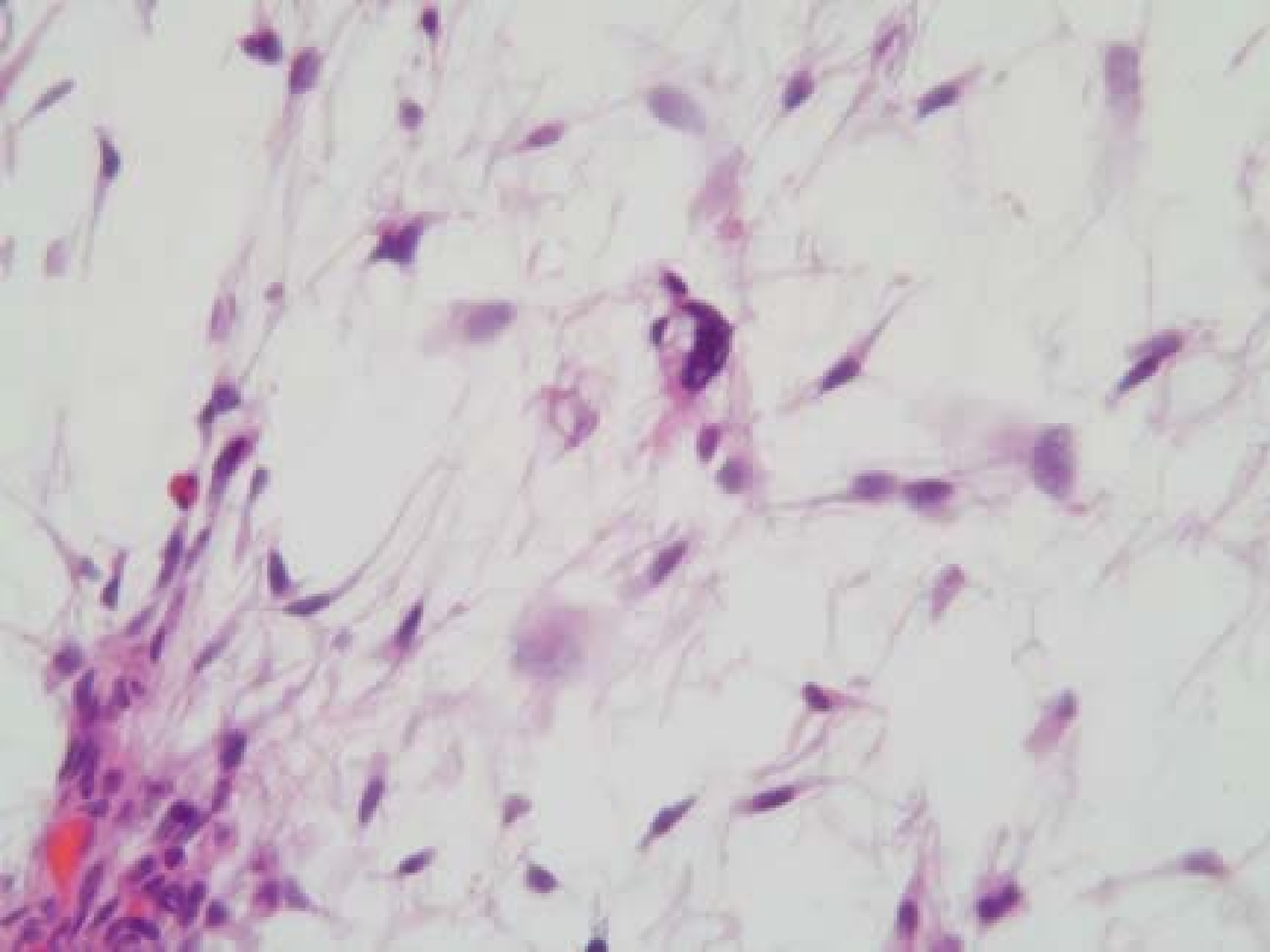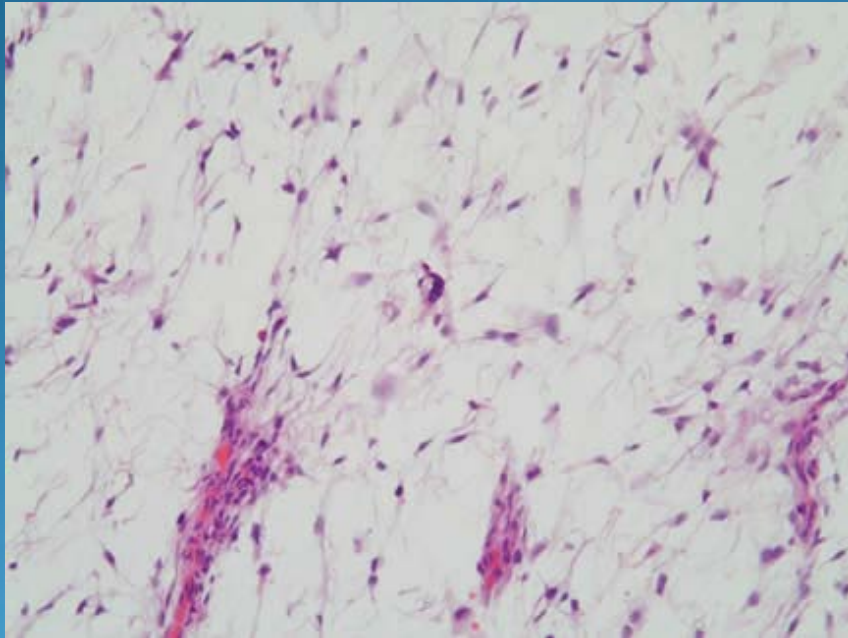


Liposarcoma, Myxoid Type

Pearls



- Deep myxoid tumor
- Network of collapsed vessels
- Dark lines that form a chicken-wire pattern
- Rare lipoblasts