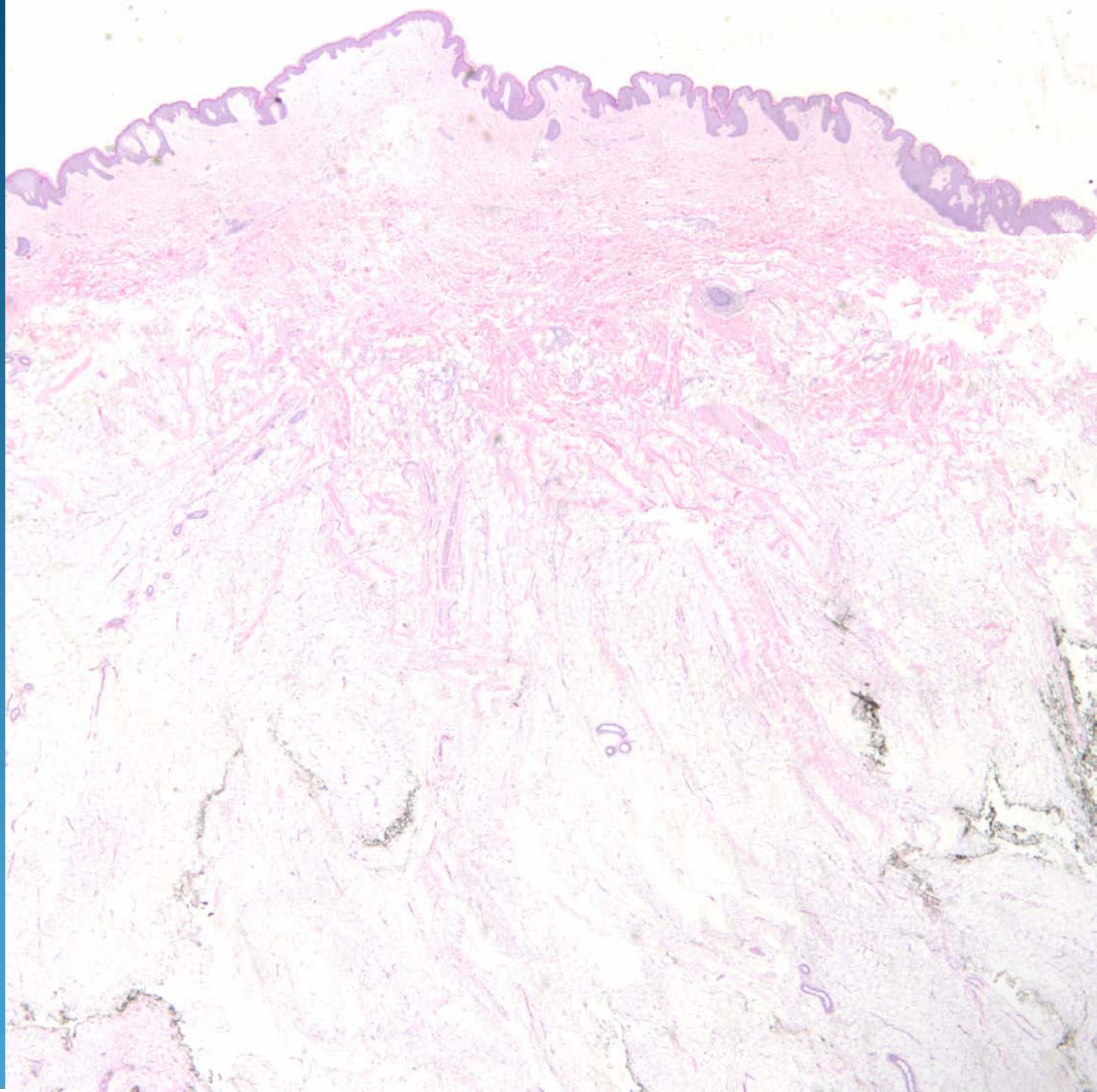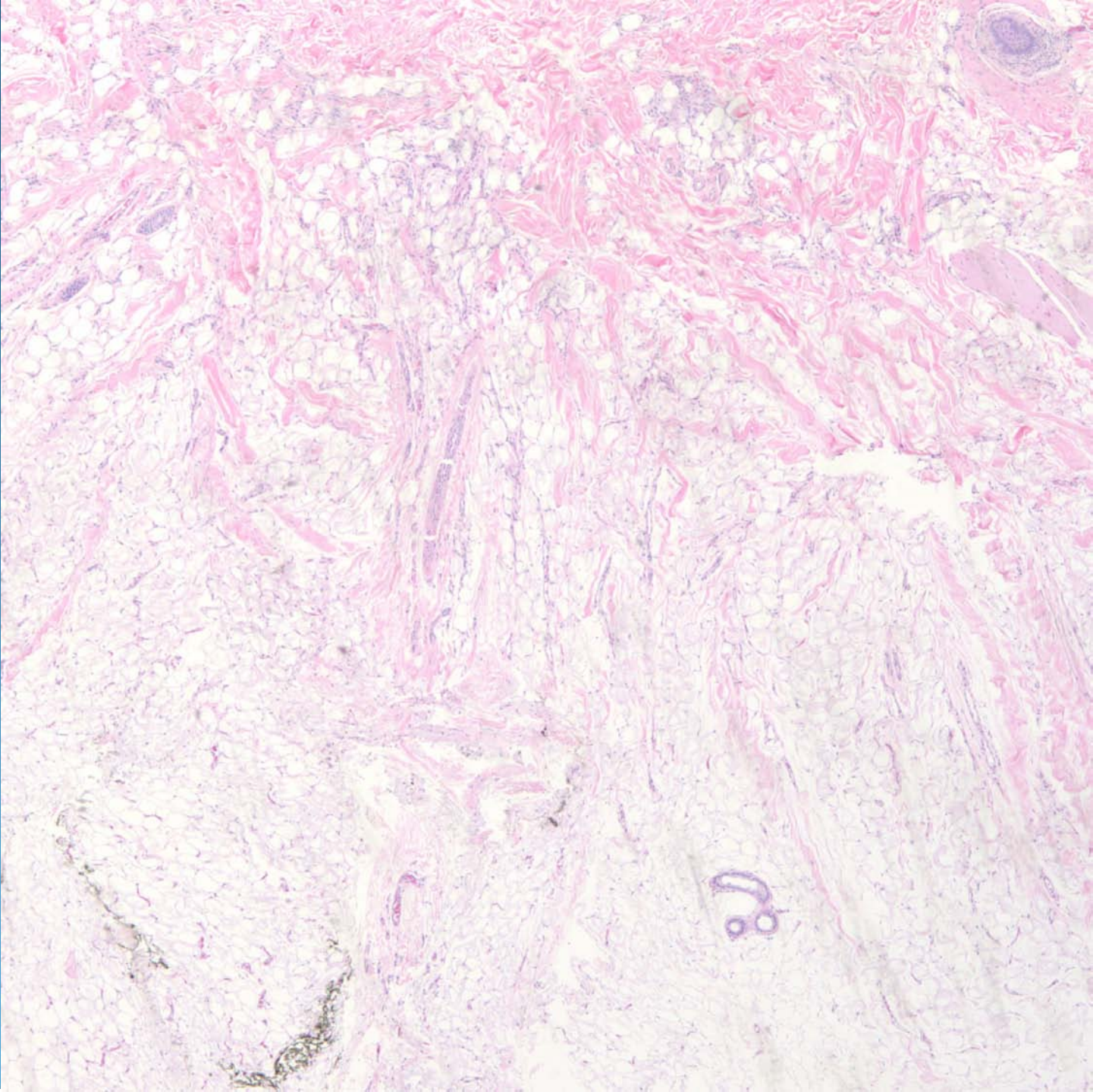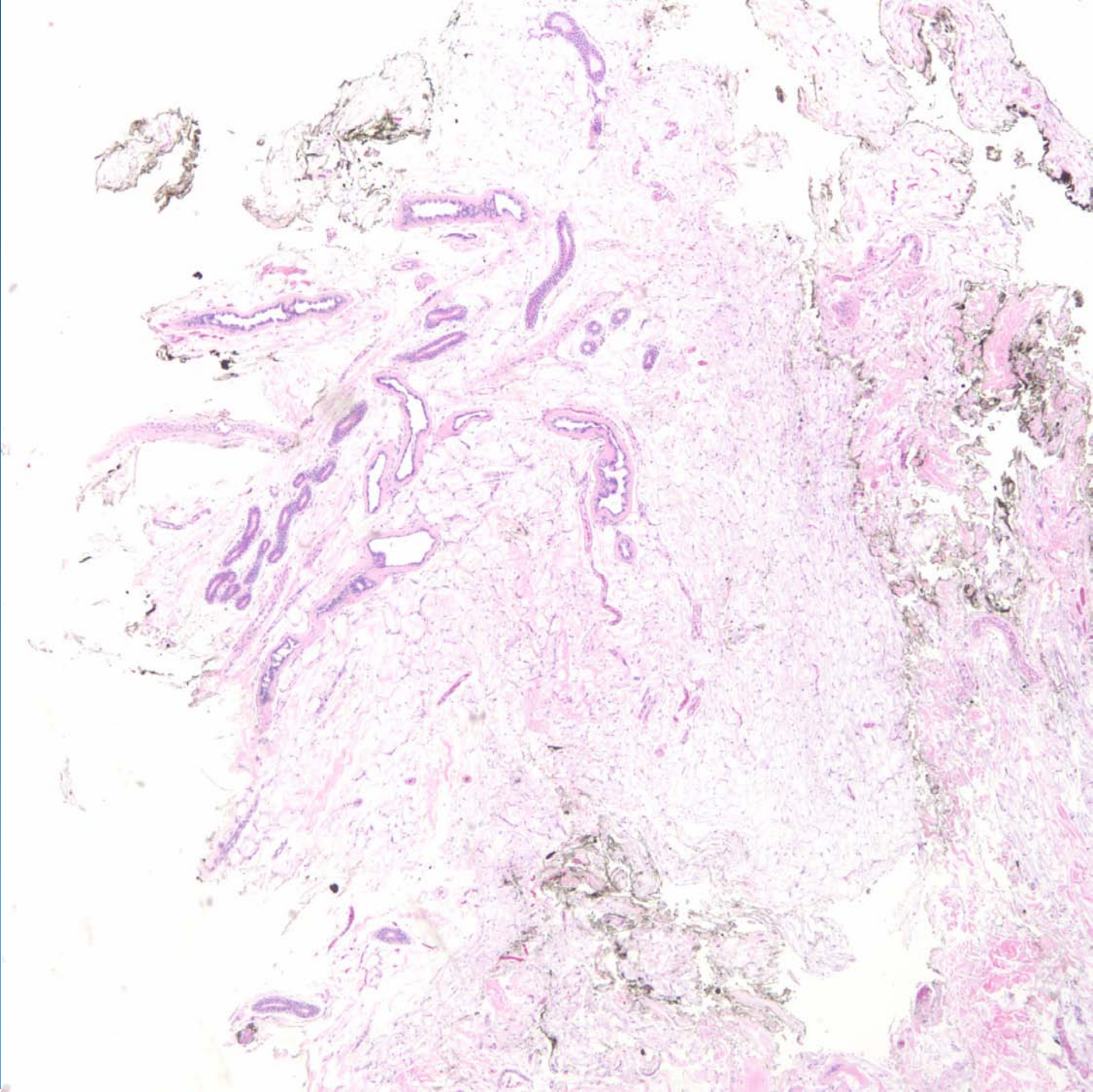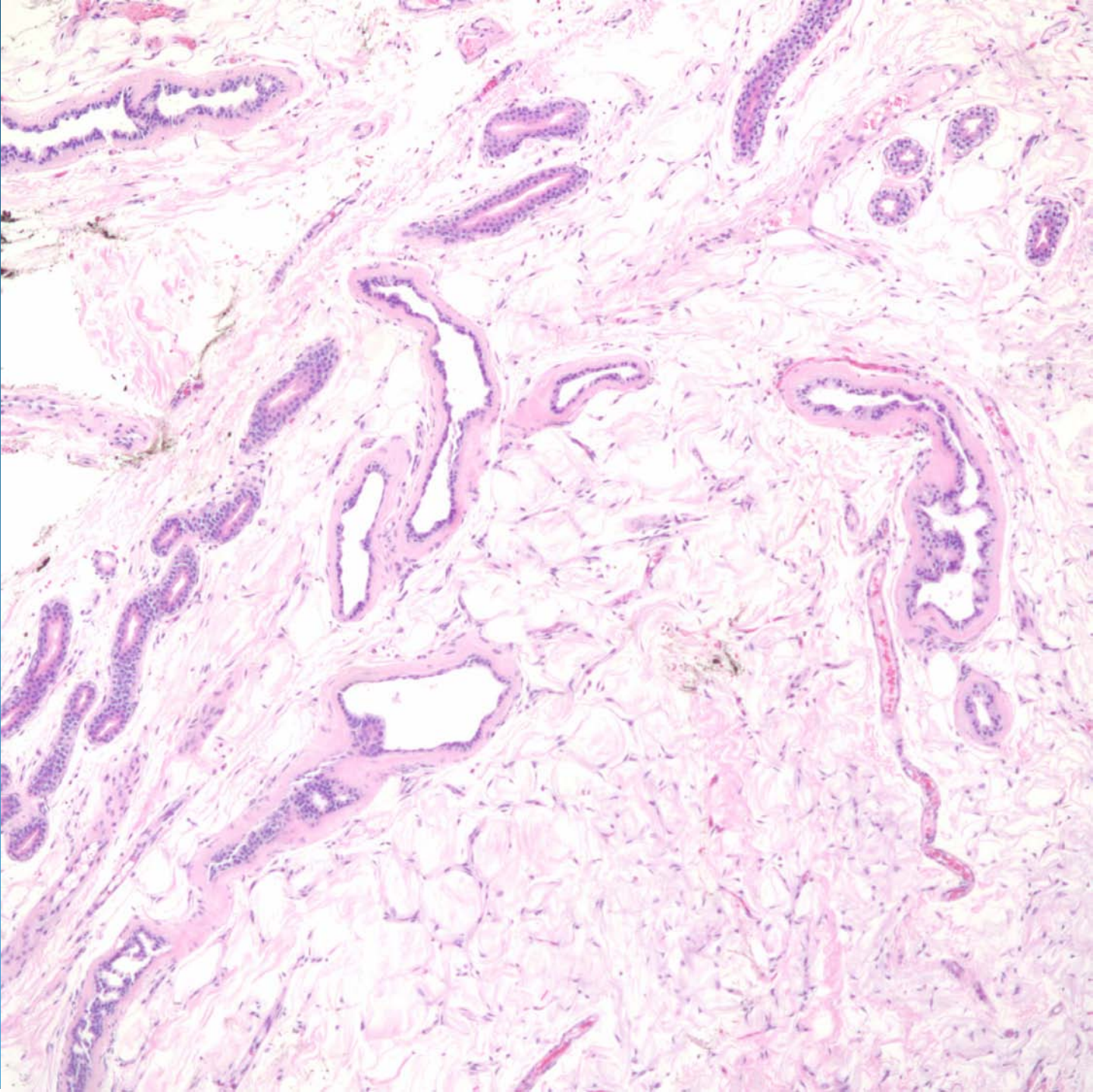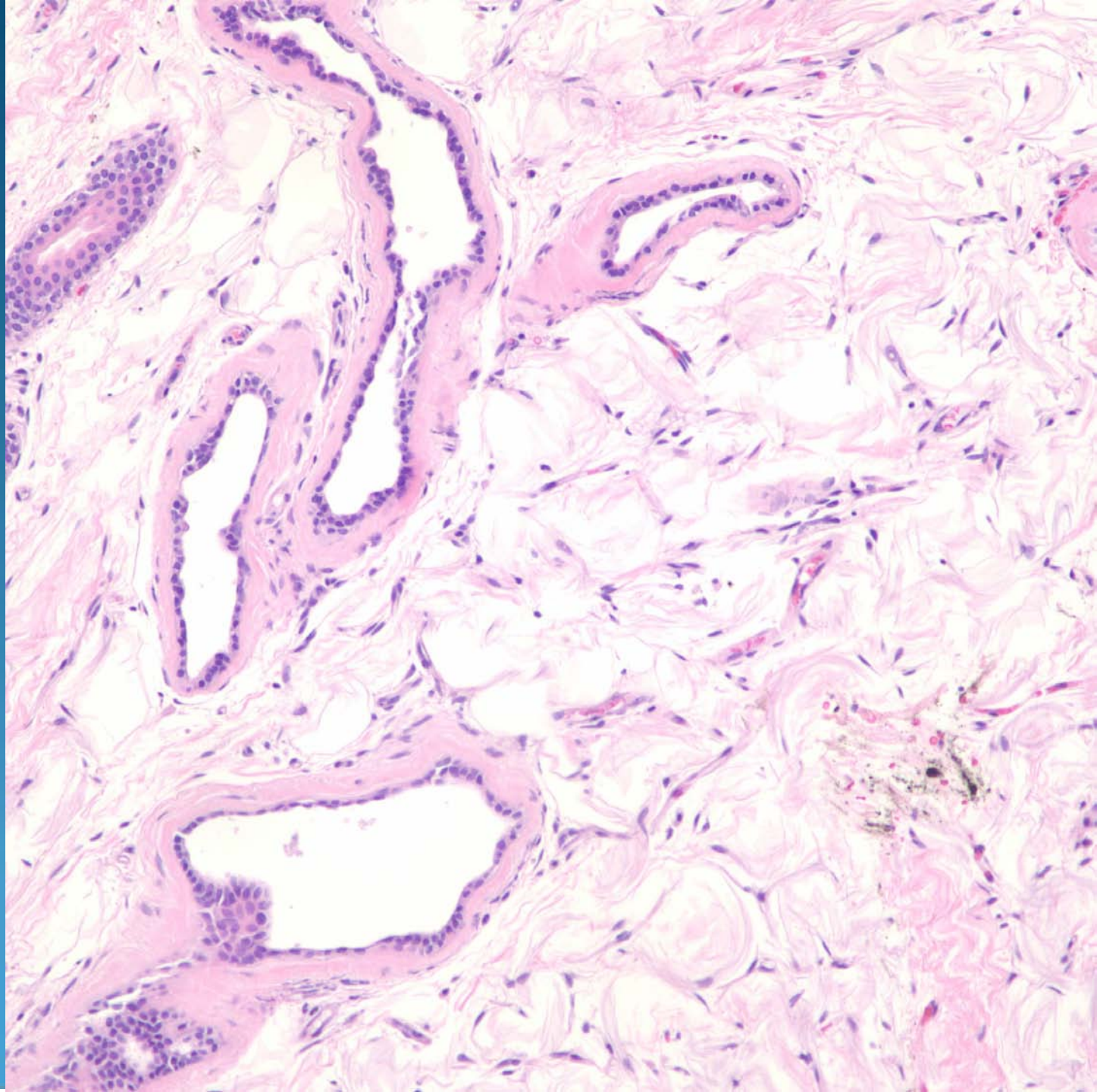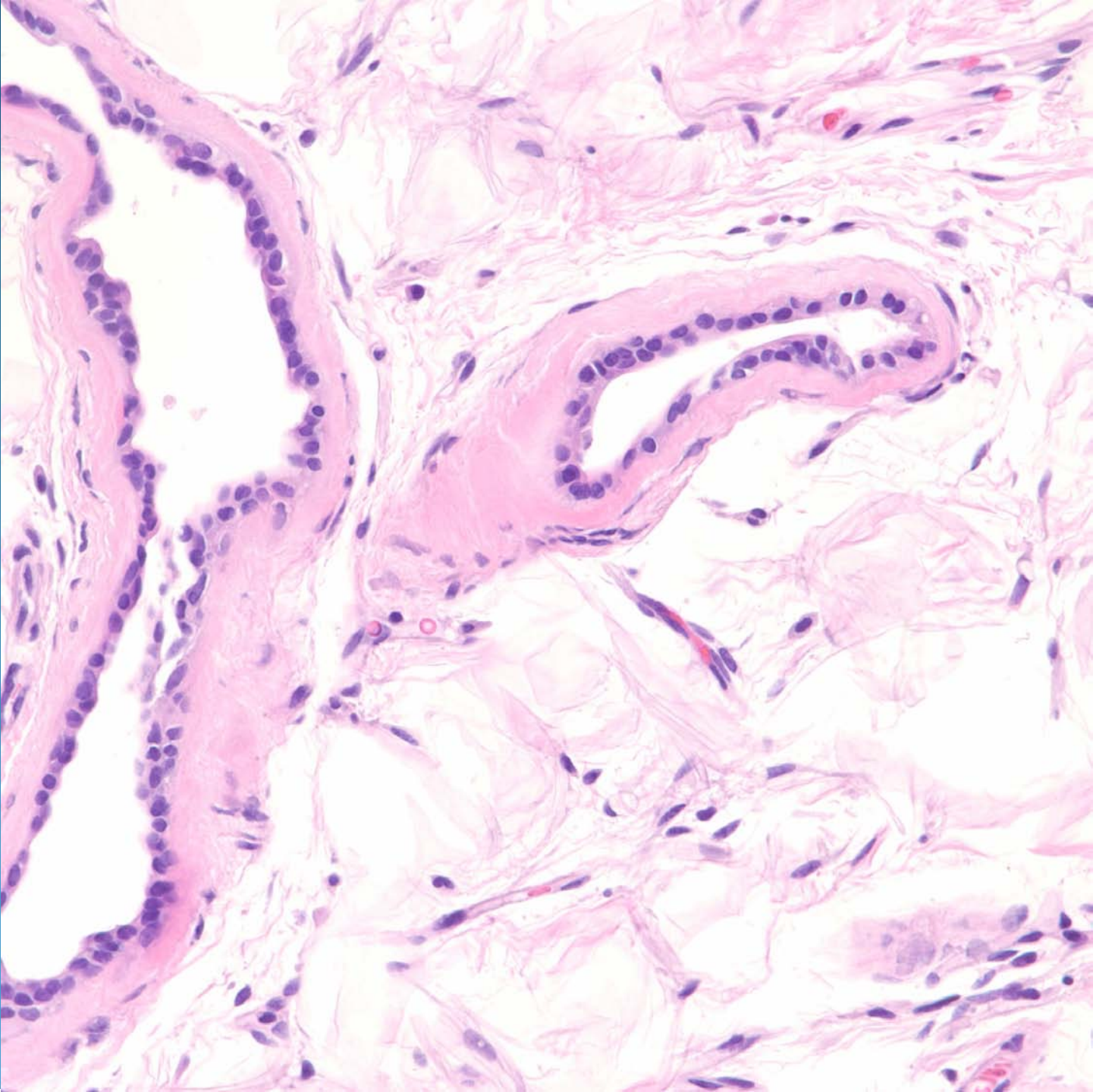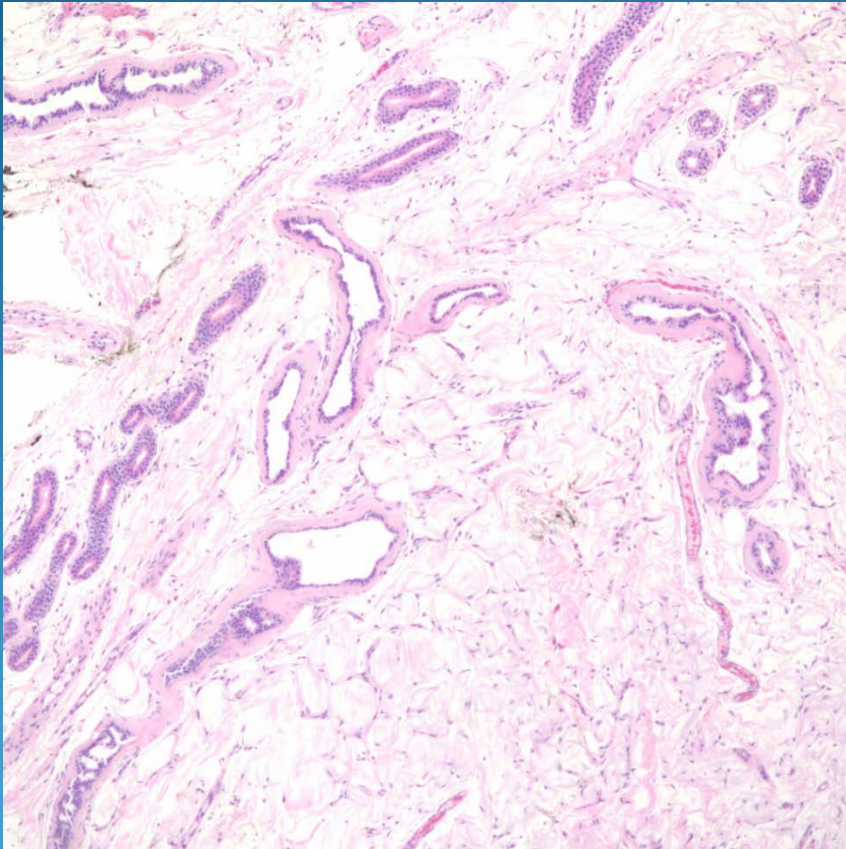


Adenolipoma

Pearls



- Conventional lipoma
- Admixed benign apocrine ducts within the fat
- No prognostic significance