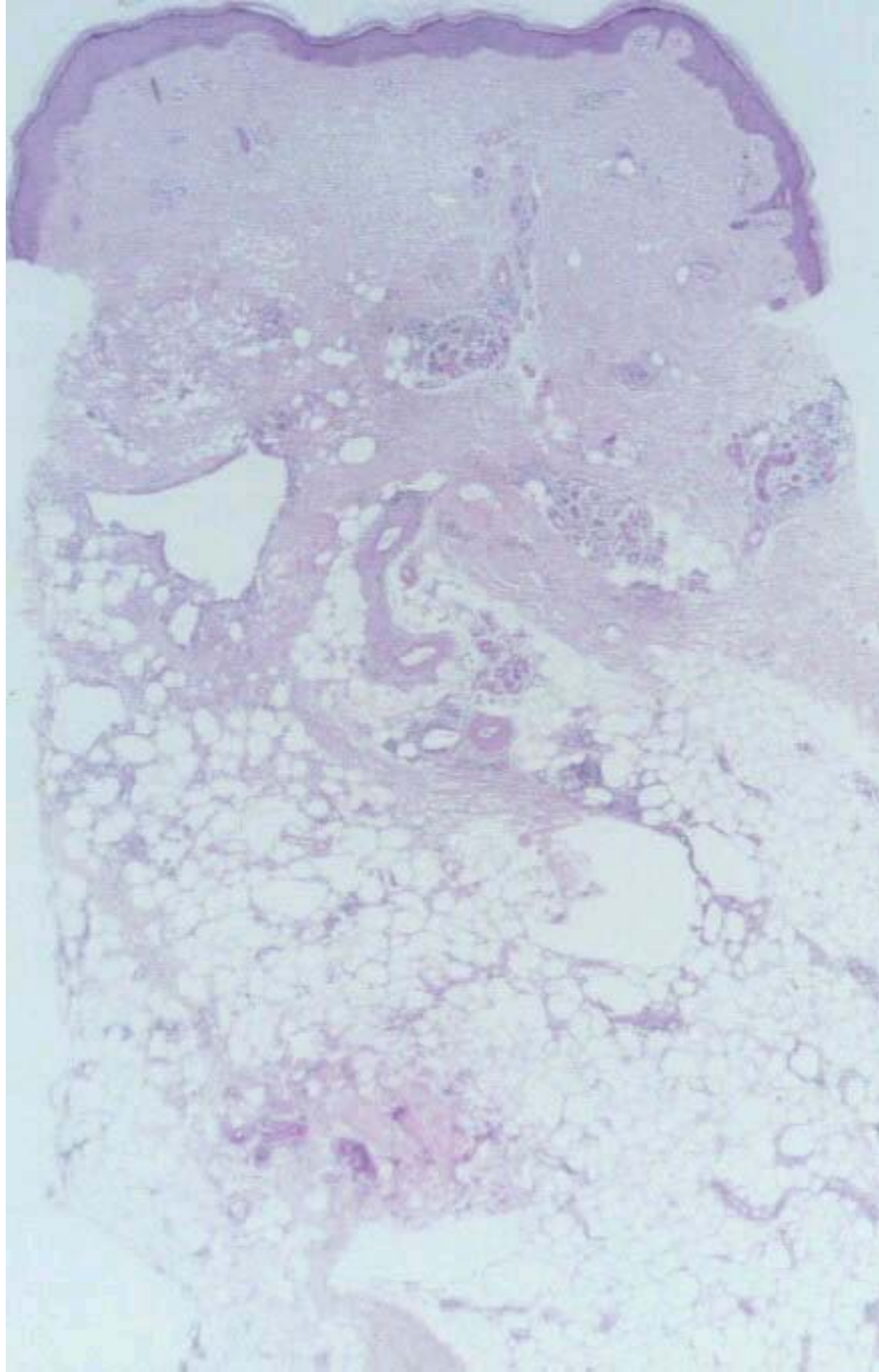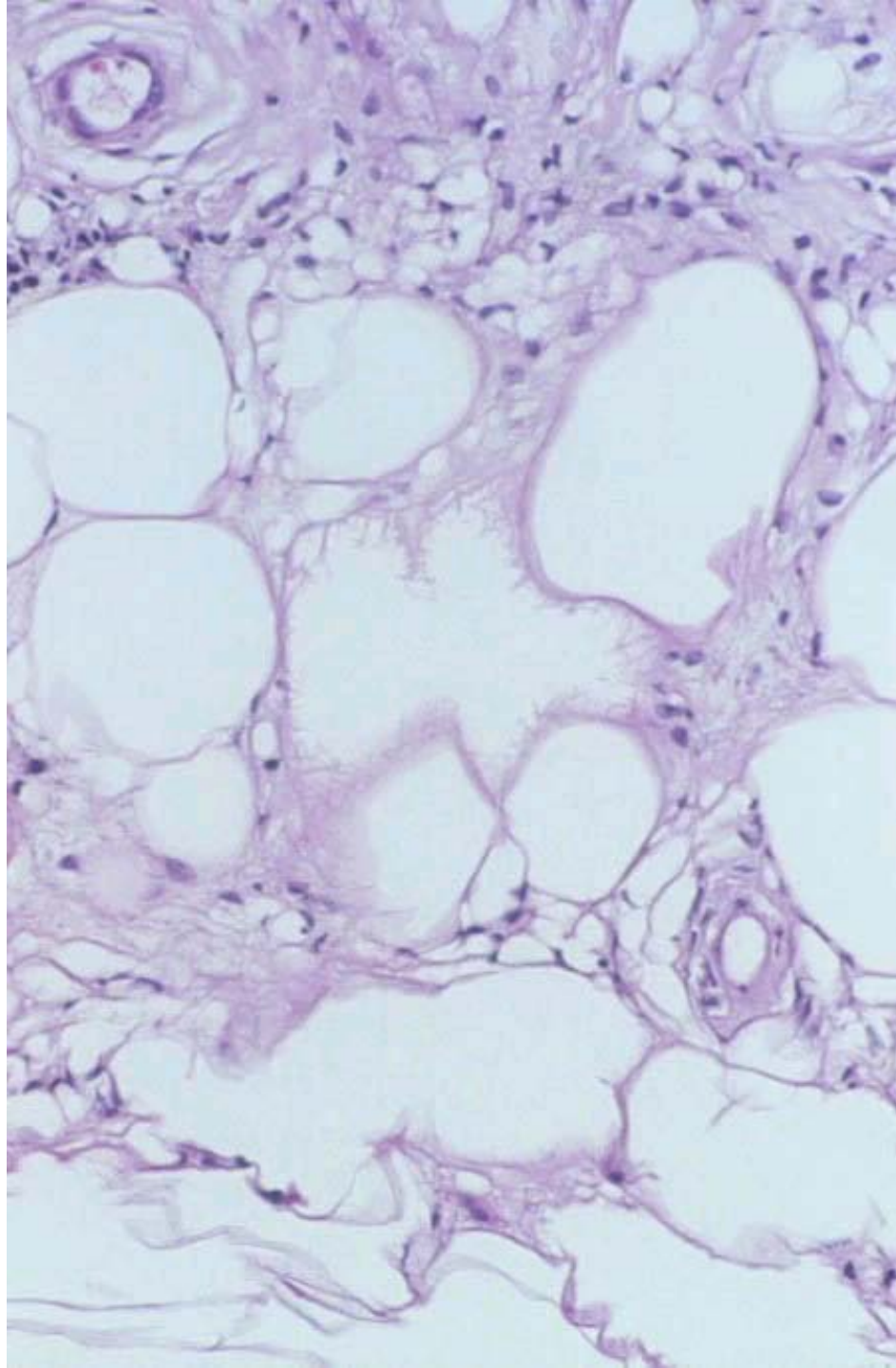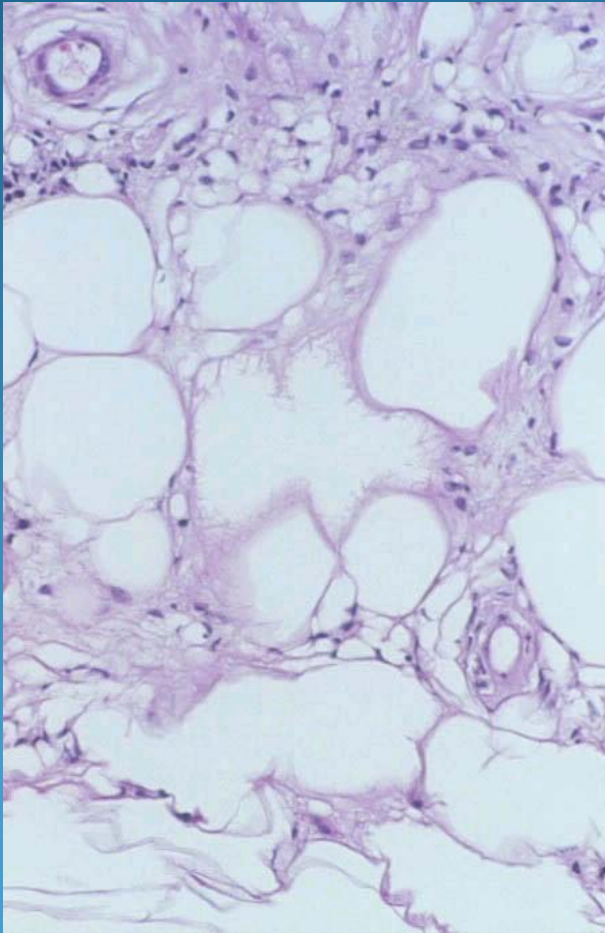


Lipodermatosclerosis/ Sclerosing Panniculitis

Pearls



- Cystic degeneration of fat with lipomembranous changes
- Lipophages common
- Sclerotic stroma
- Feathery cuticle lining cystic spaces