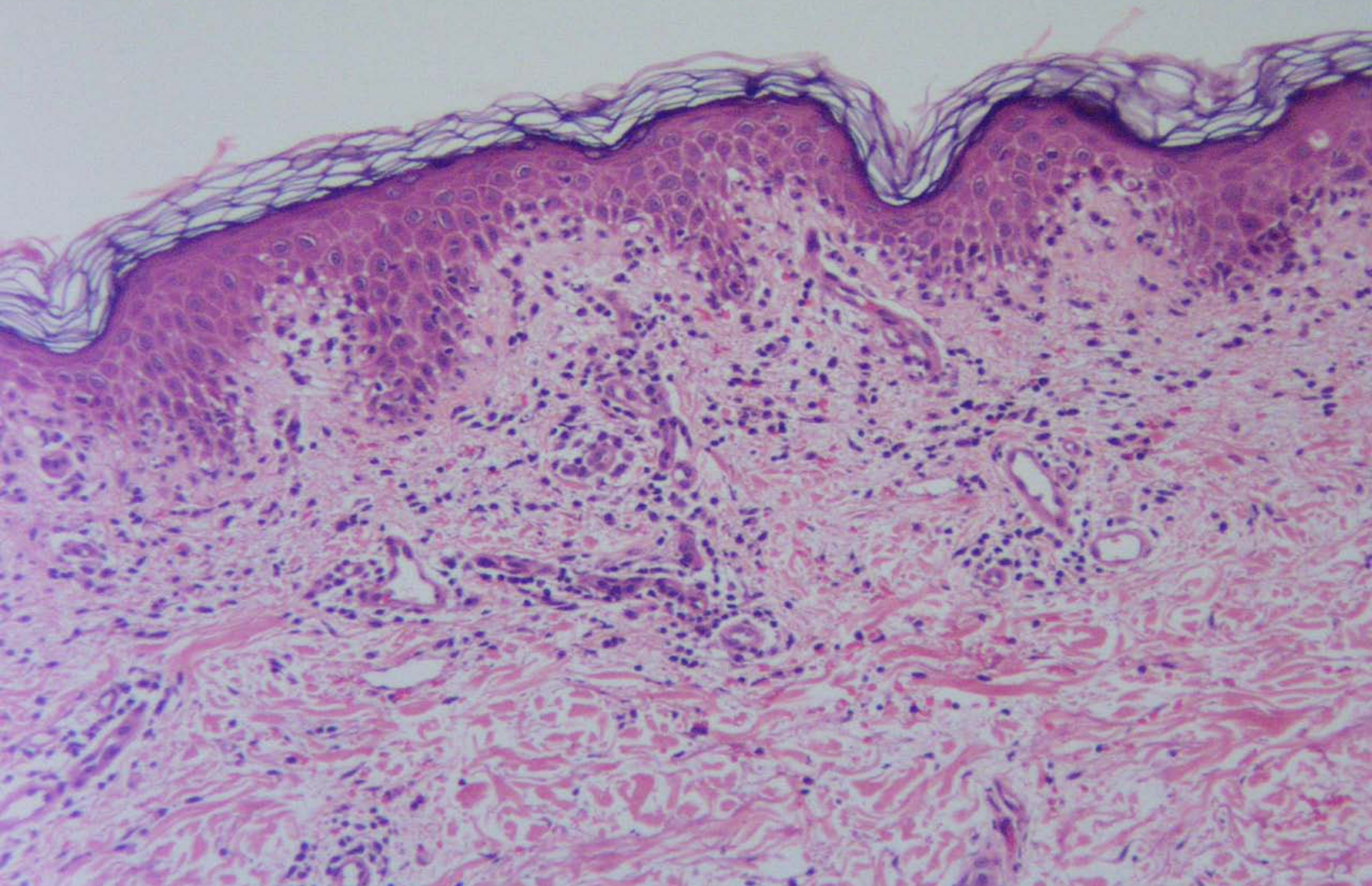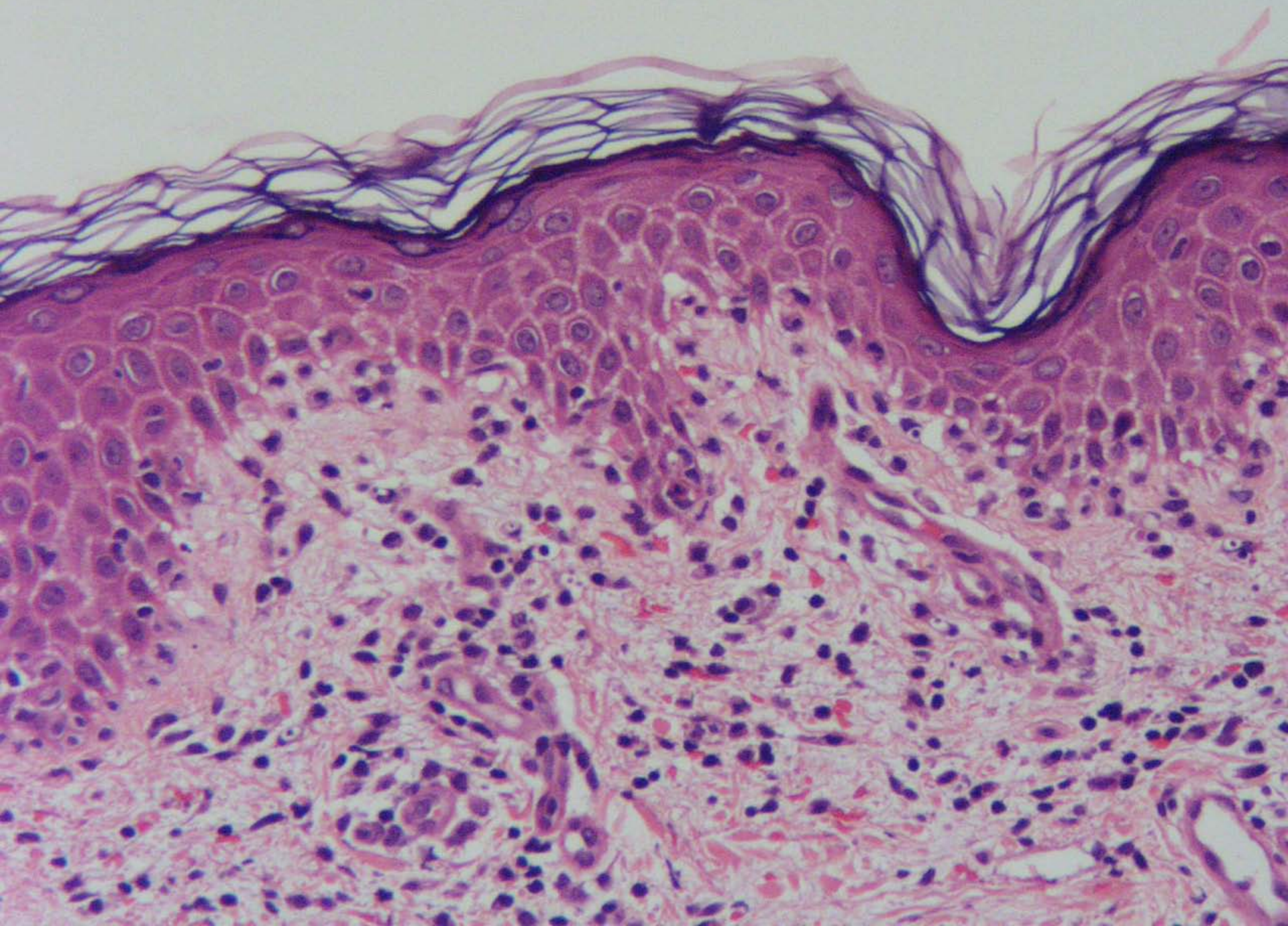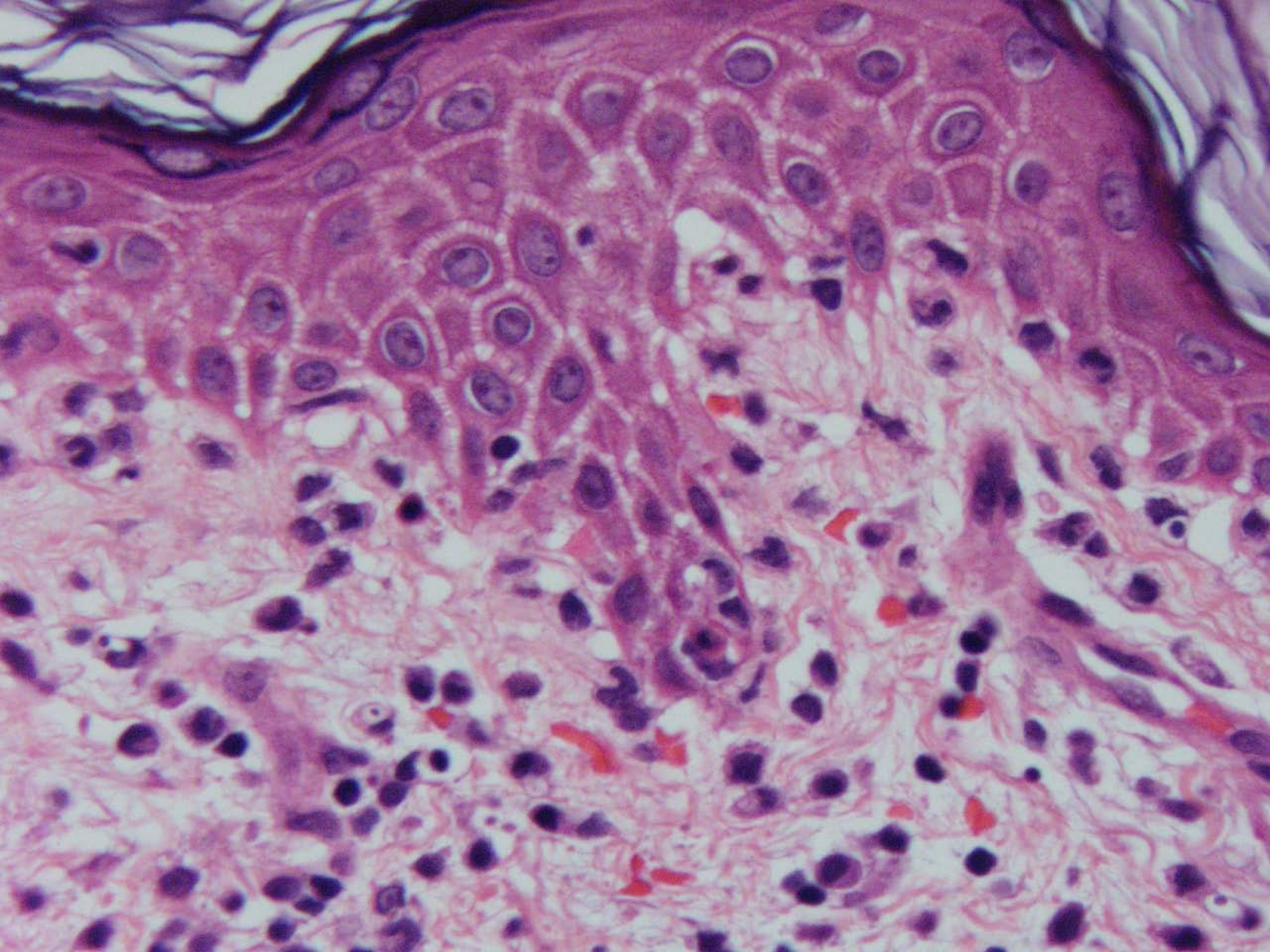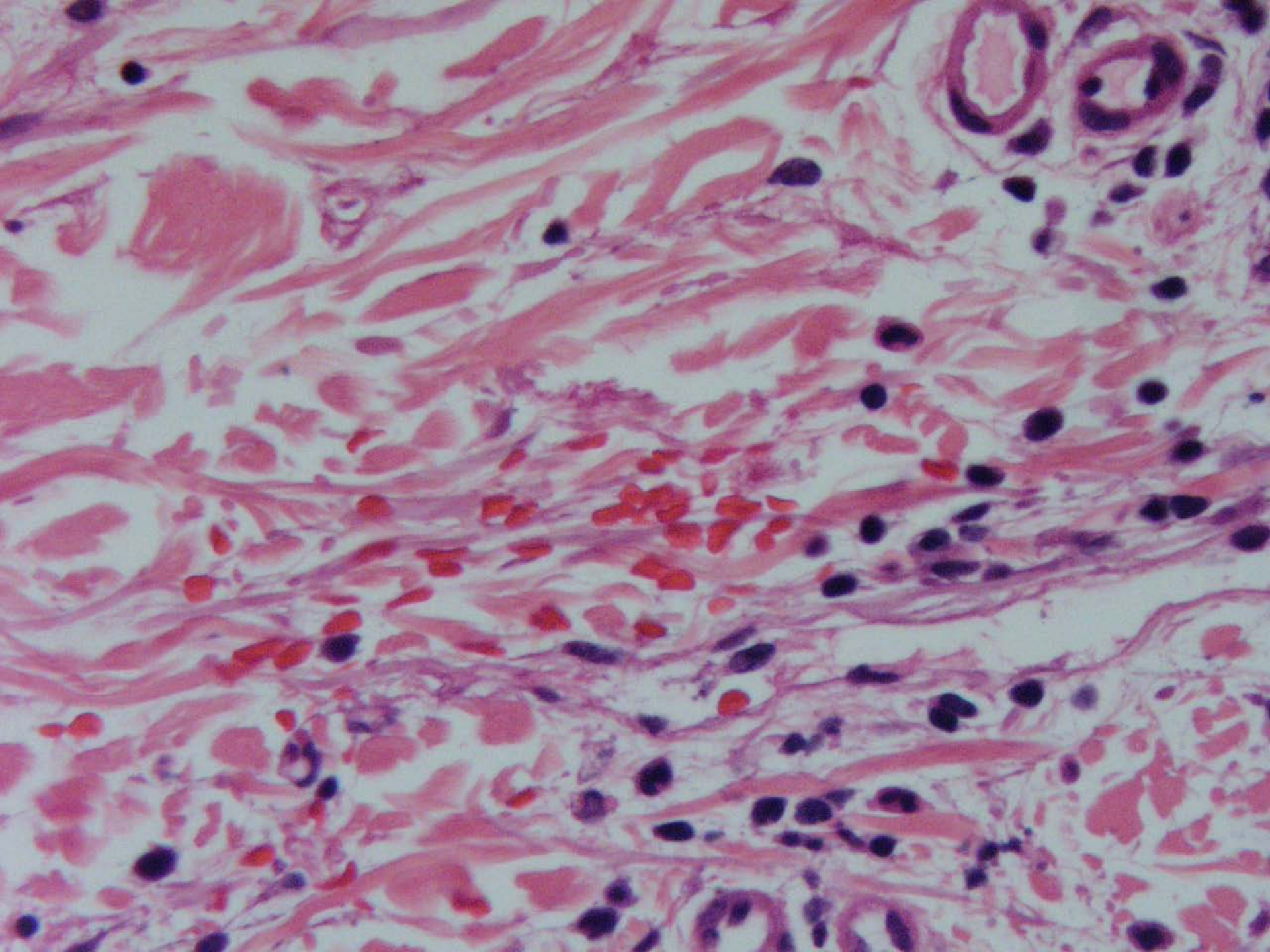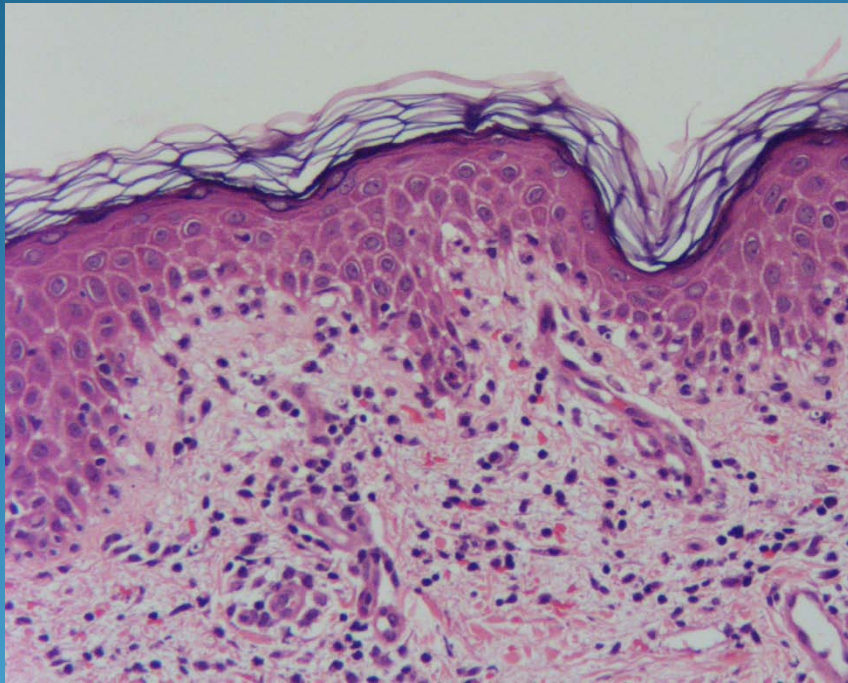


# Lichenoid Drug Reaction

# Pearls



- Mild spongiosis
- Occasional parakeratosis
- Colloid bodies in basal layer
- Lichenoid infiltrate not as well developed as LP
- Usually eosinophils, if plasma cells, think syphilis