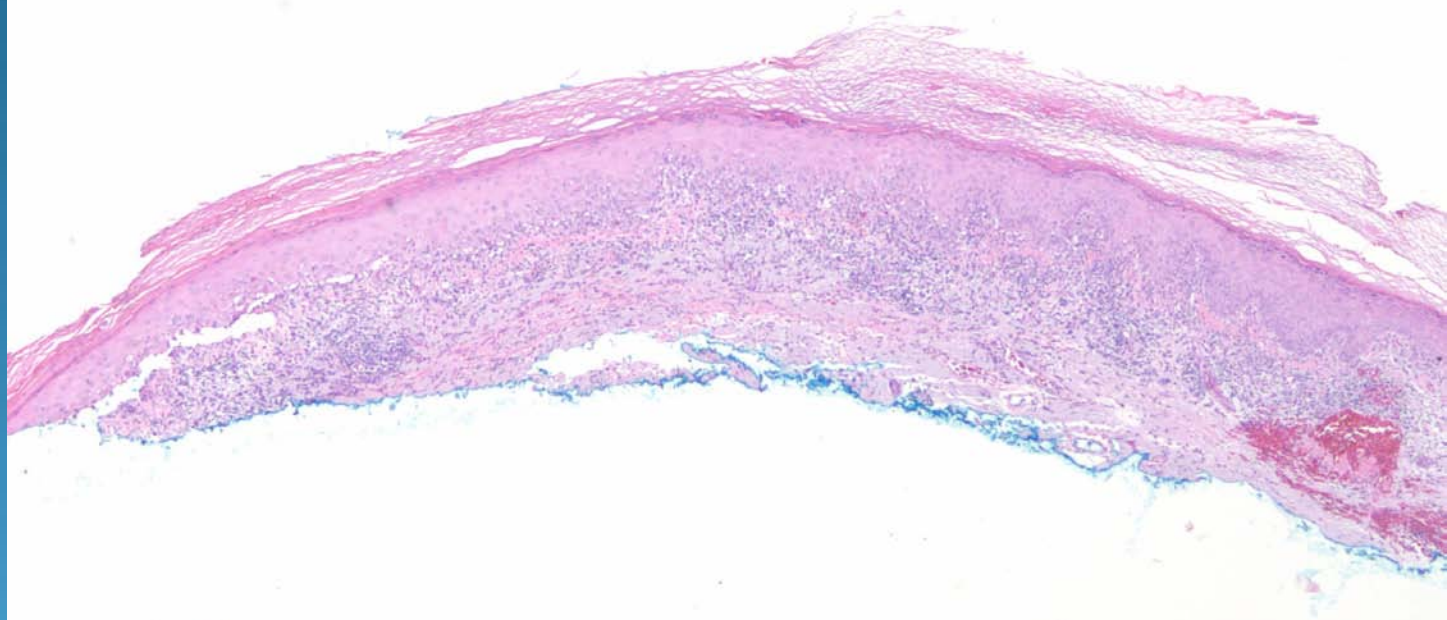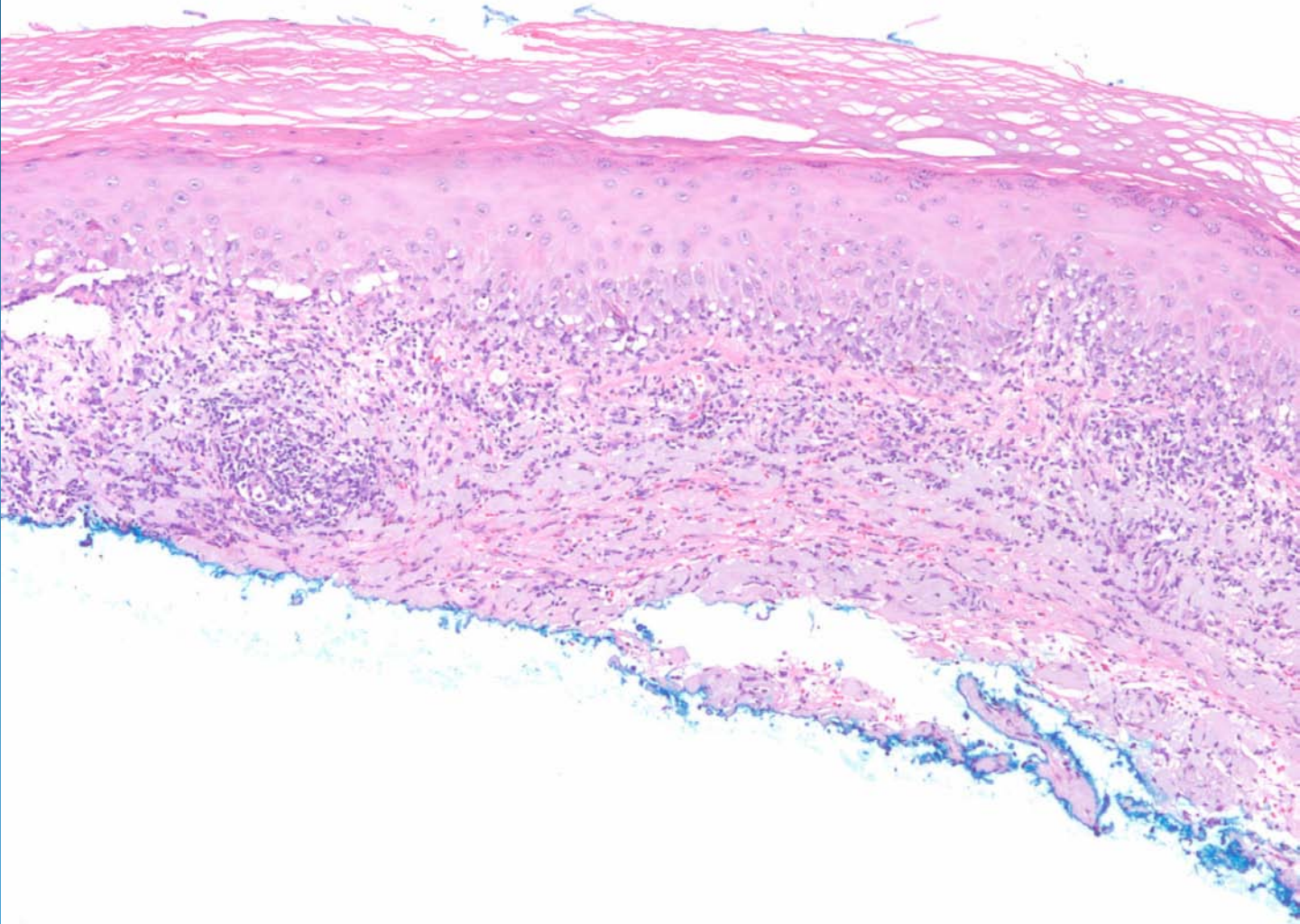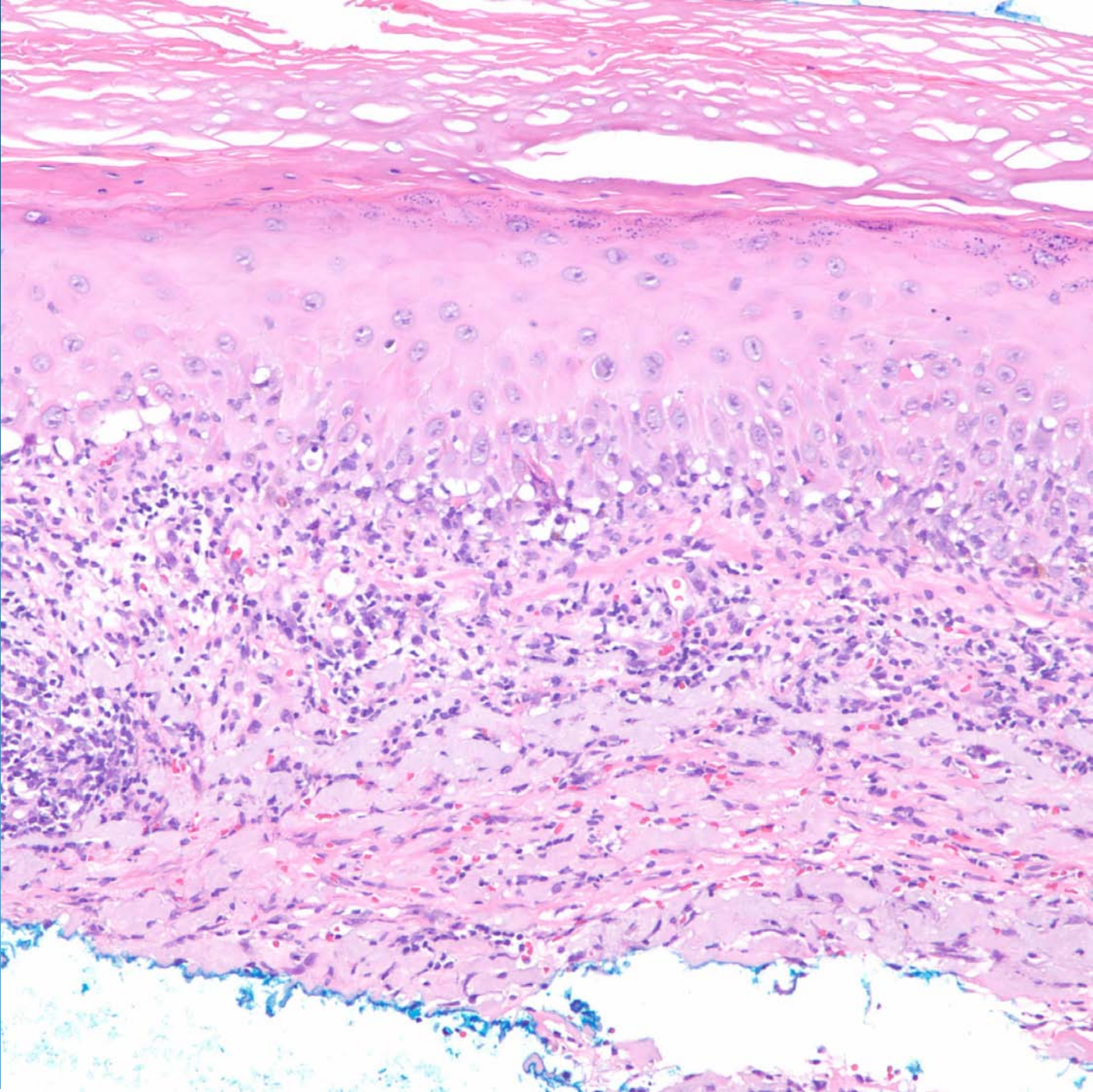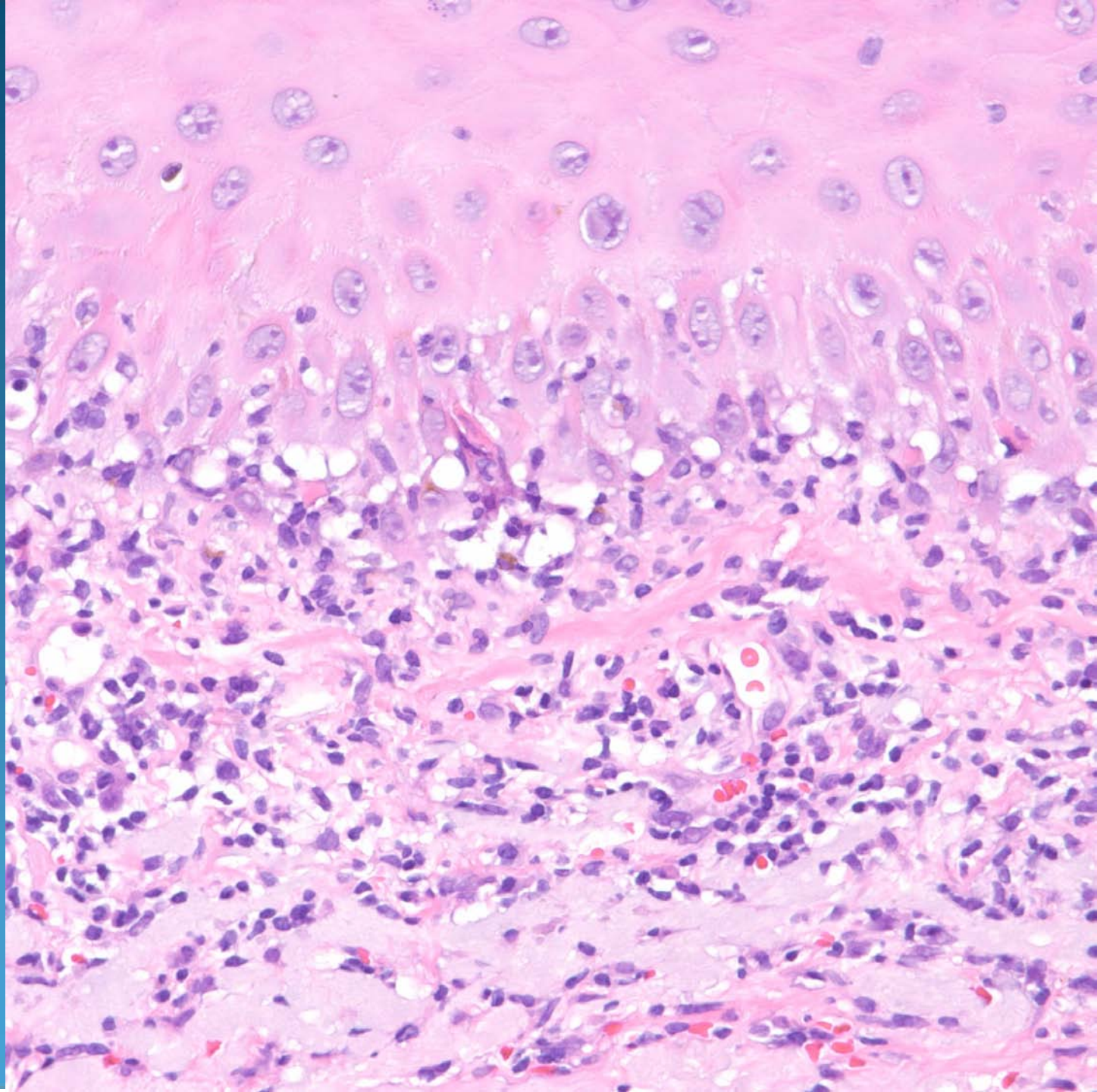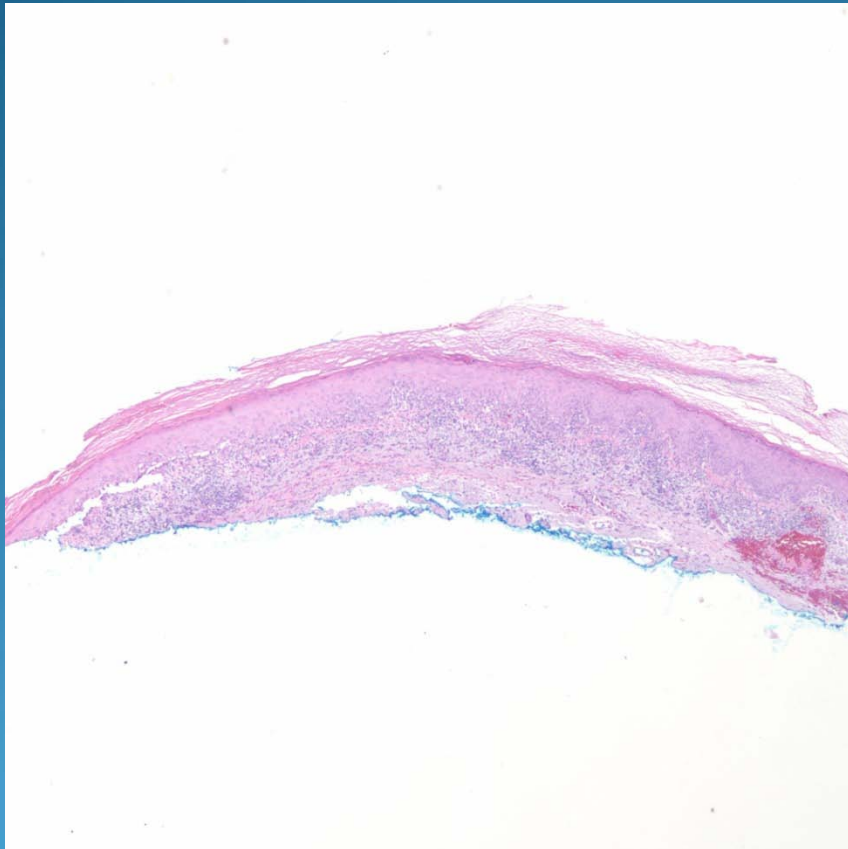


# Lichen Planus-Like Keratosis

# Pearls



- Low power lichenoid dermatitis, histologically similar to lichen planus
- May show Max-Joseph-like spaces with Civatte bodies
- May show parakeratosis
- May have adjacent lentigo or seborrheic keratosis