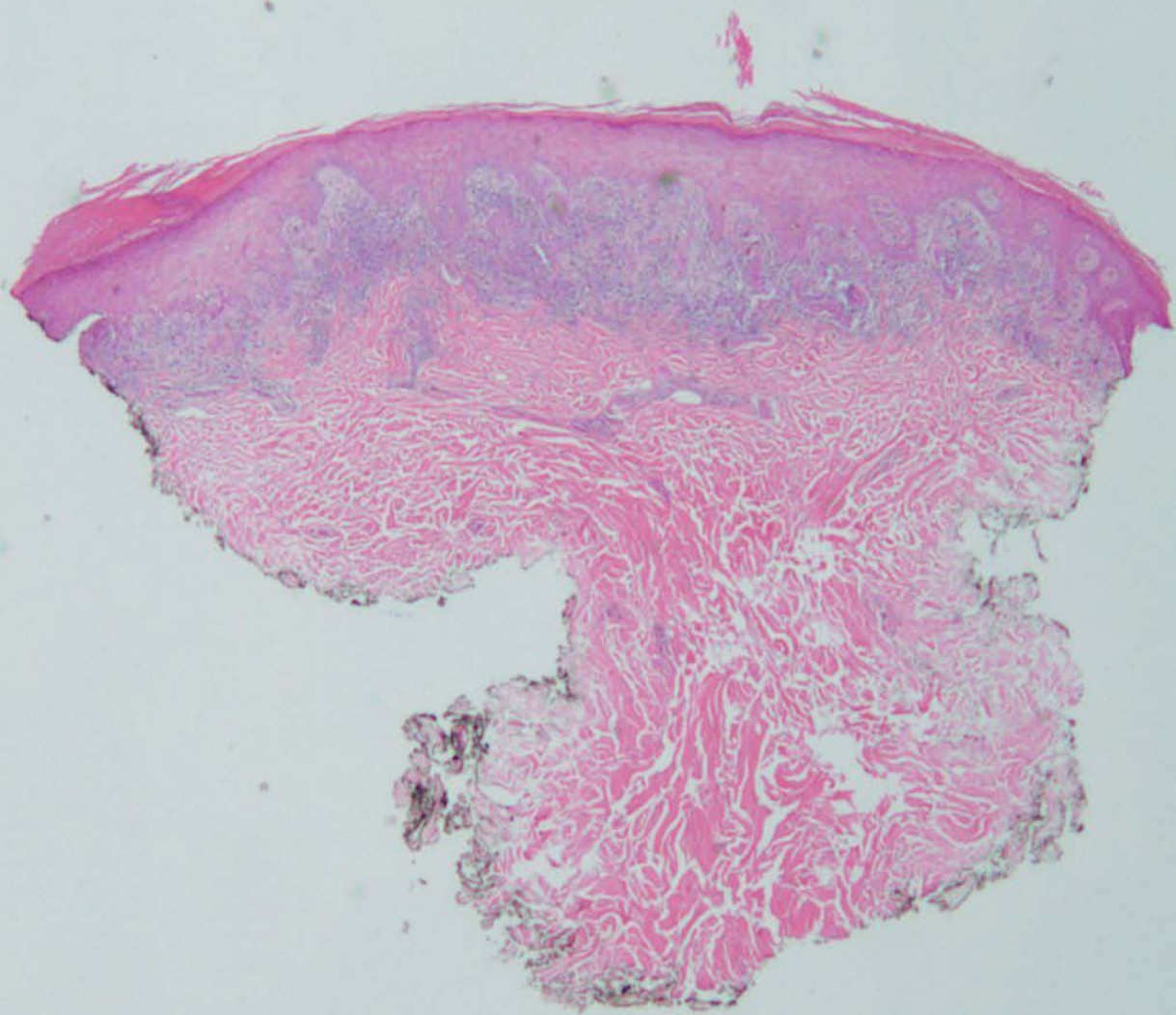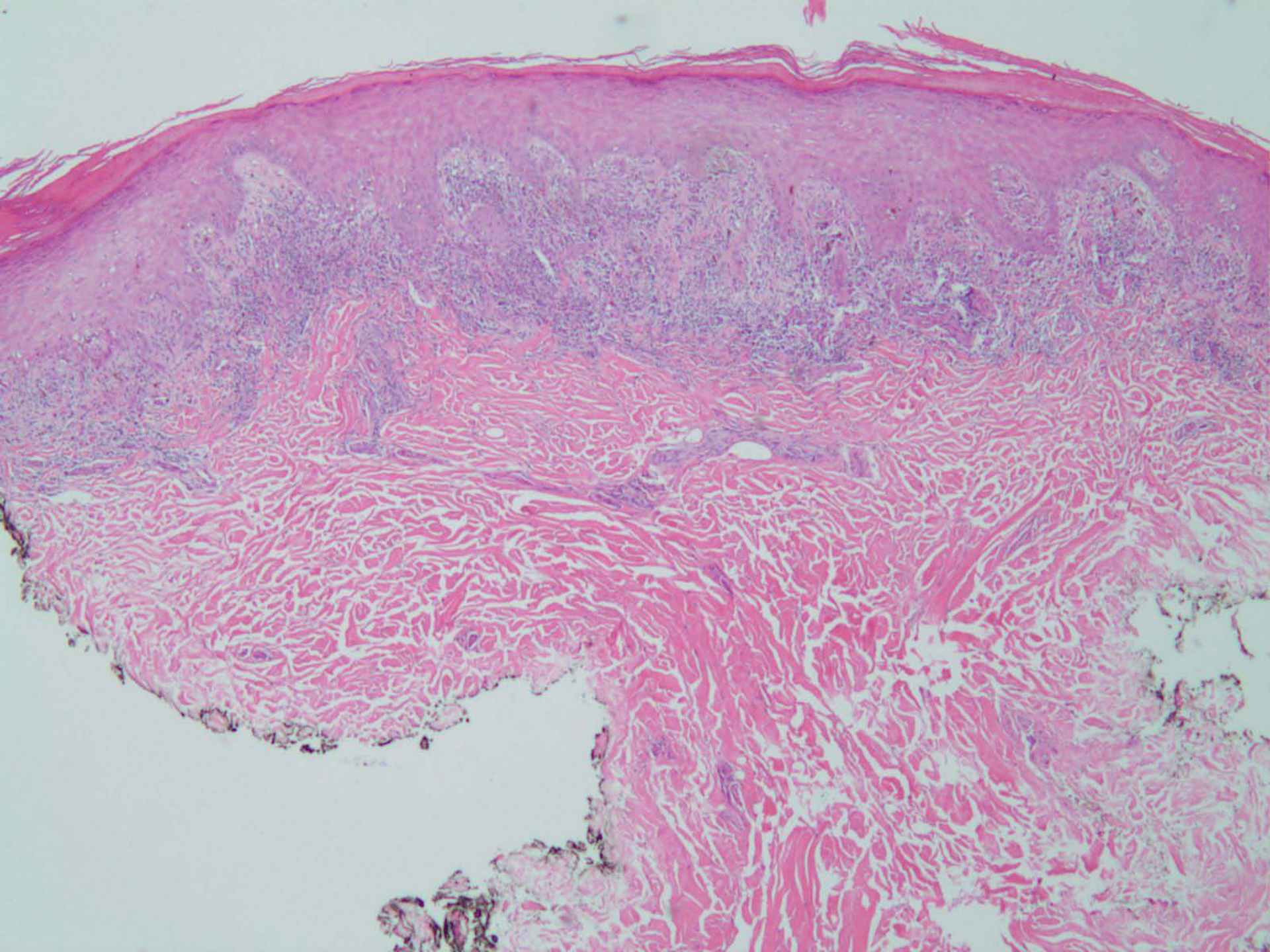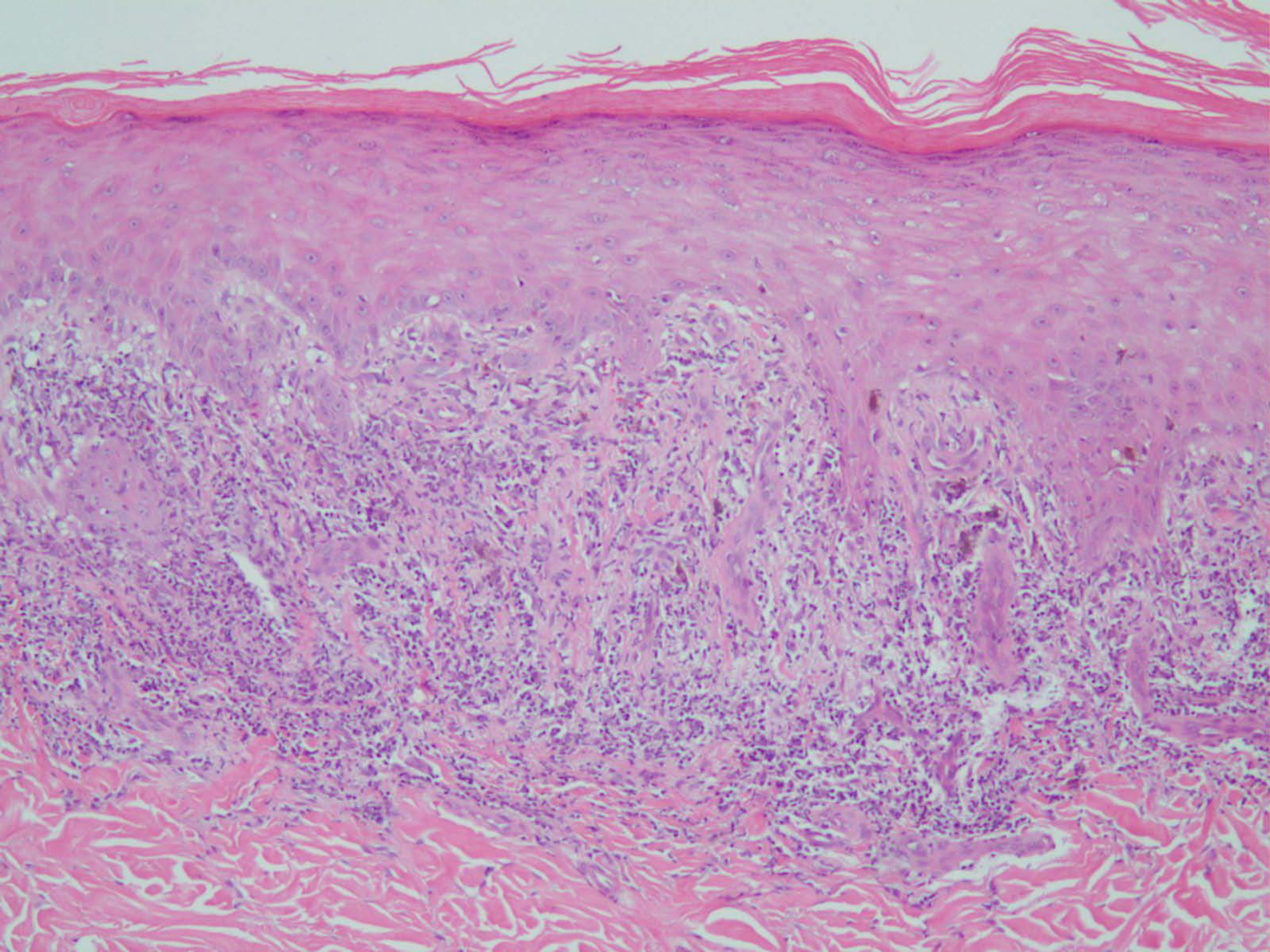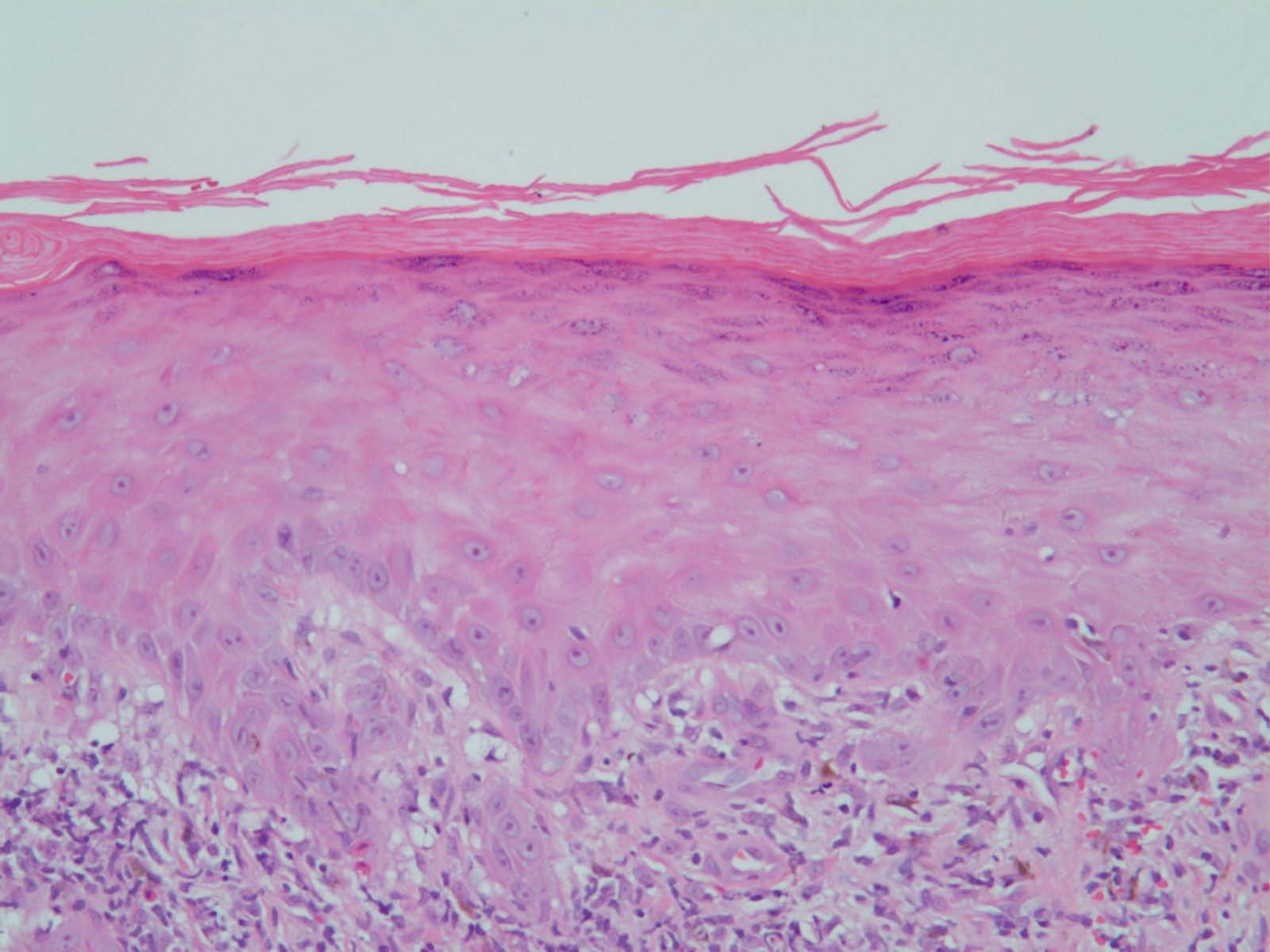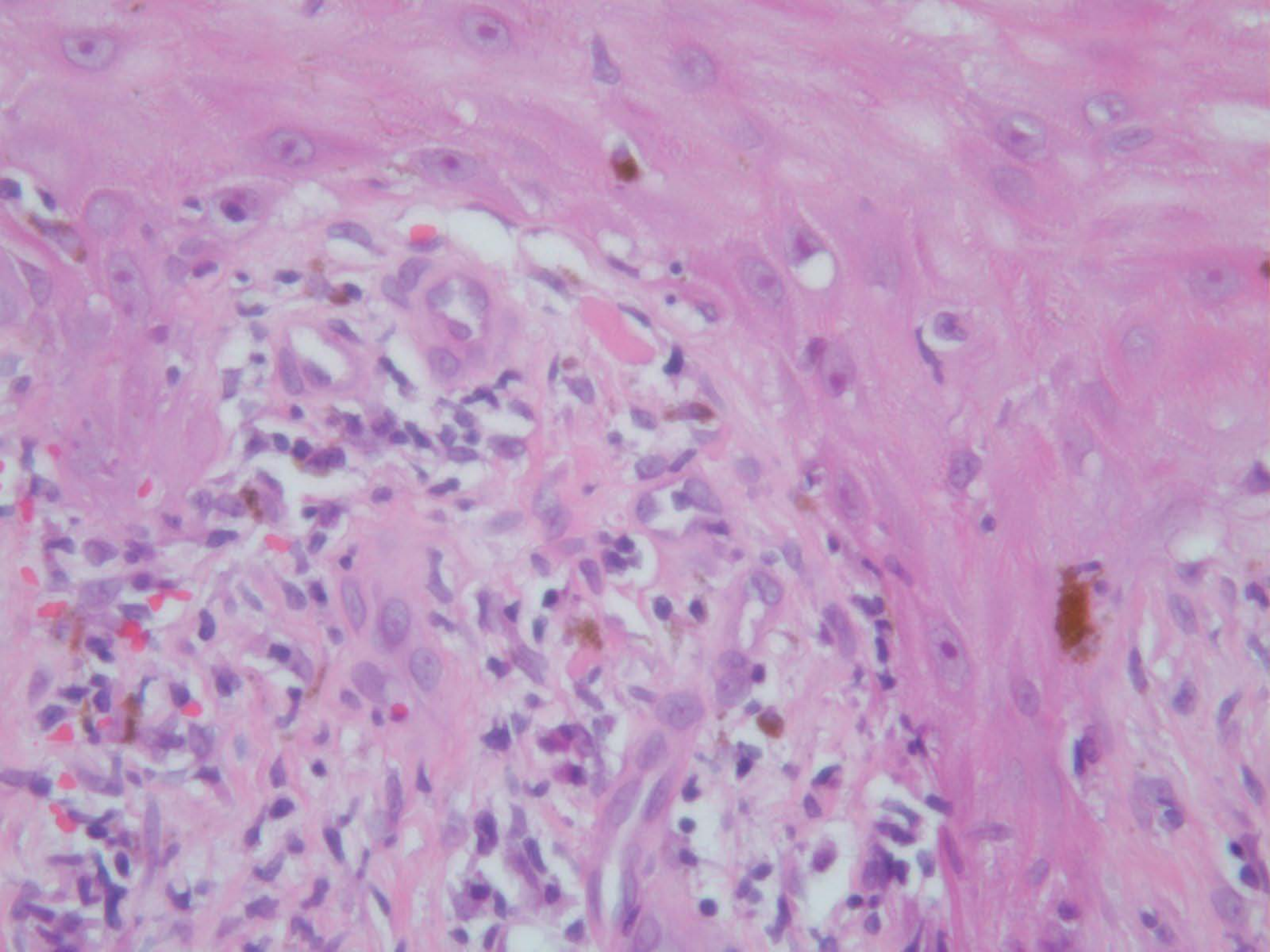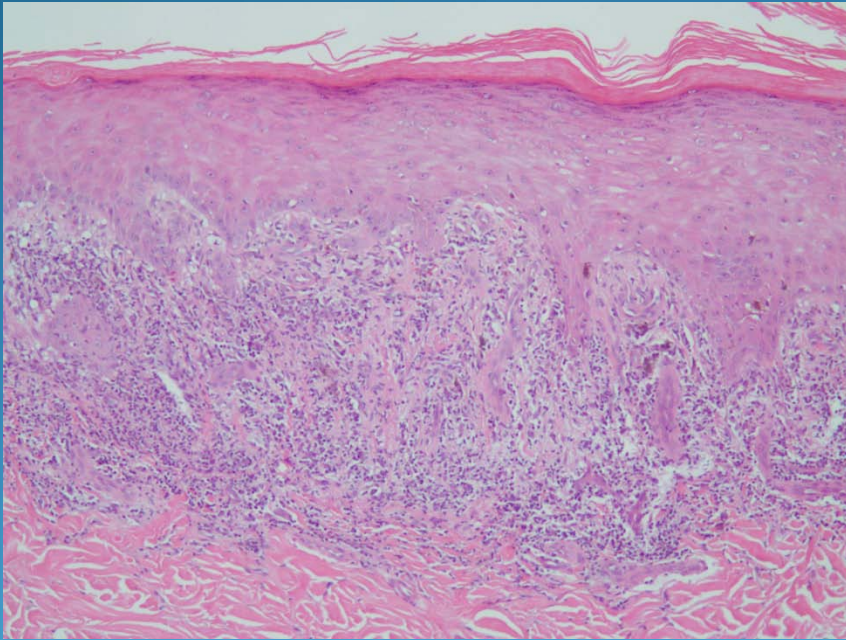


# Lichen Planus

# Pearls



- Lichenoid infiltrate
- Colloid bodies at basal layer
- Wedge shaped hypergranulosis
- Plasma cells in mucosal lesions