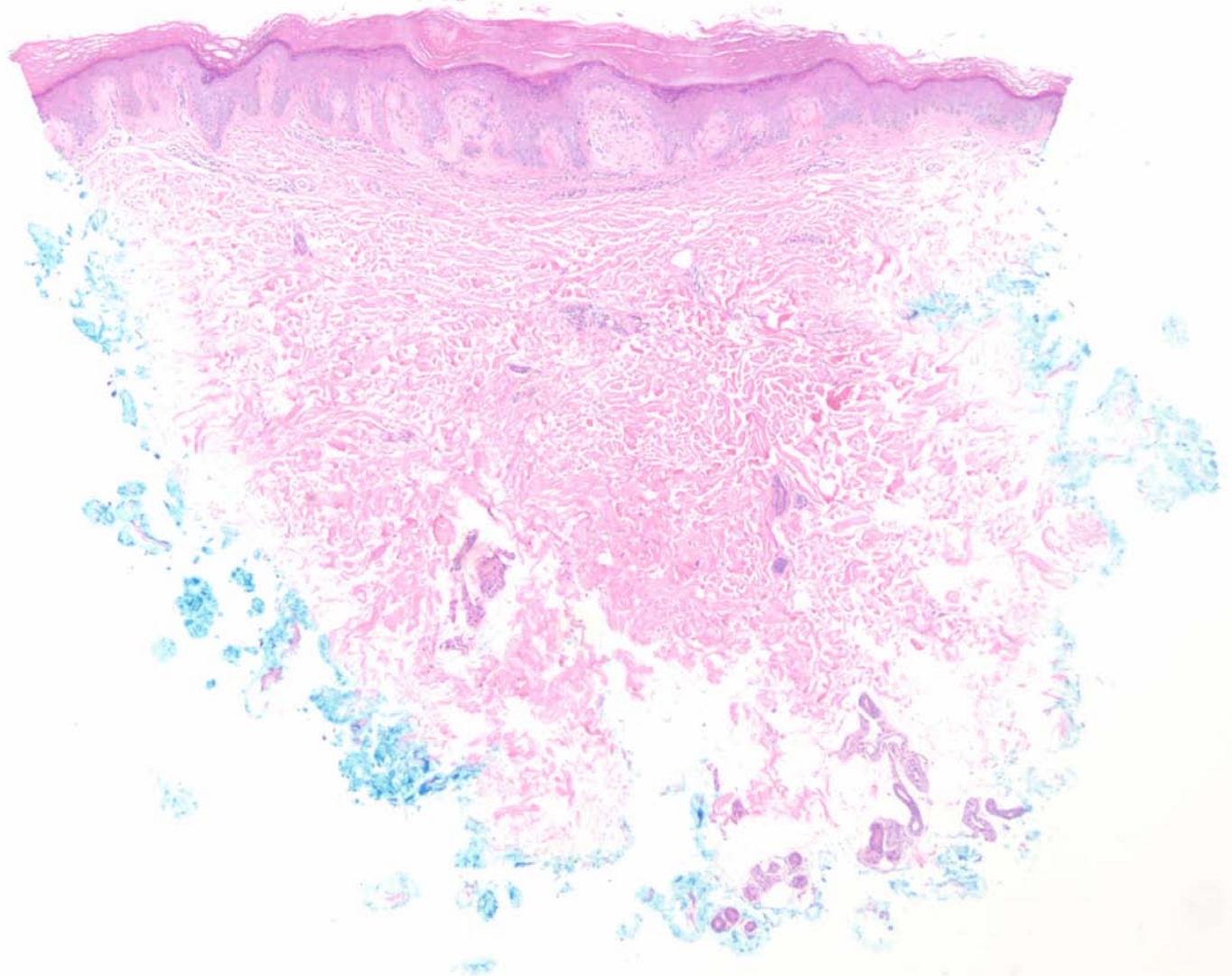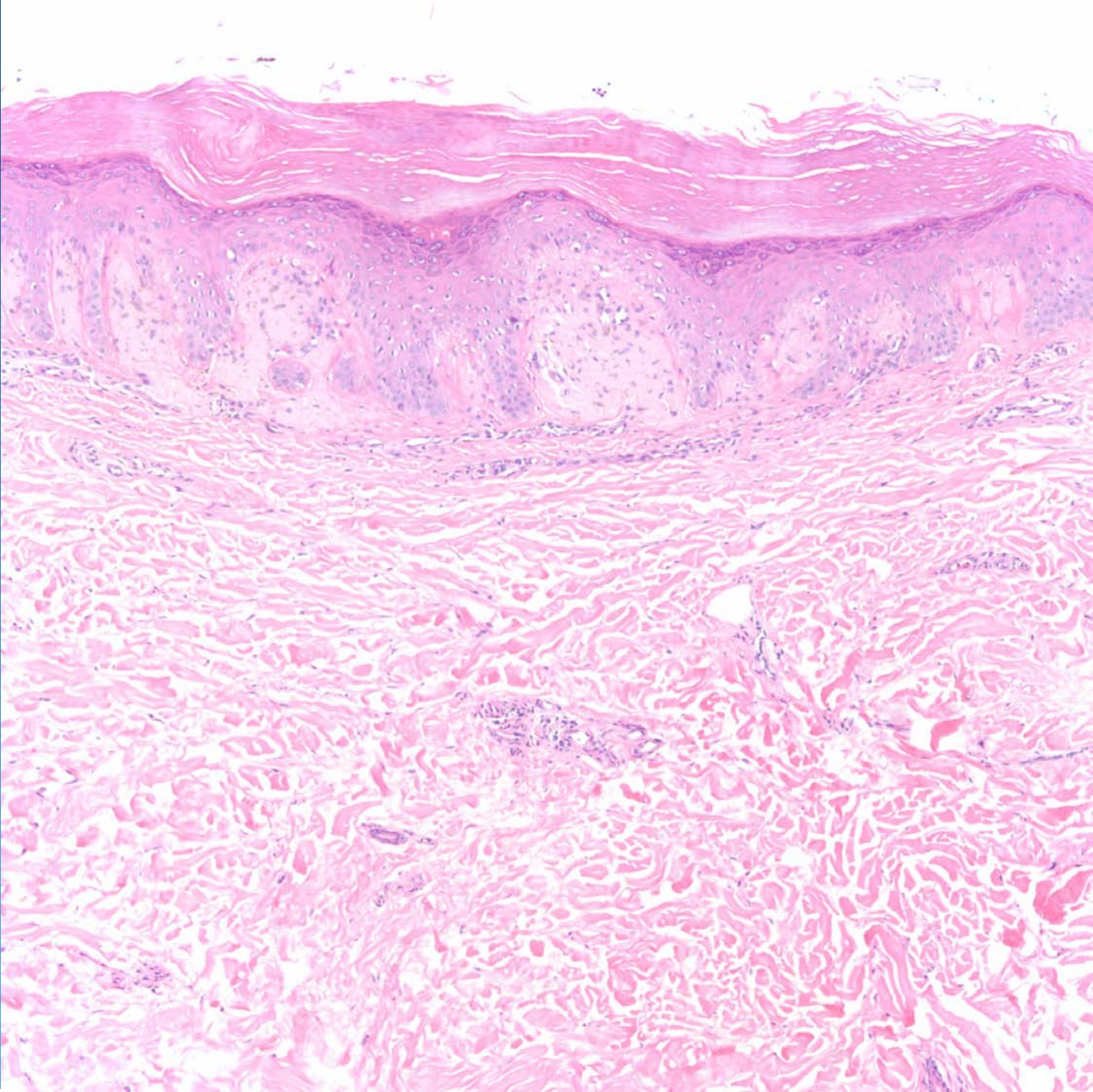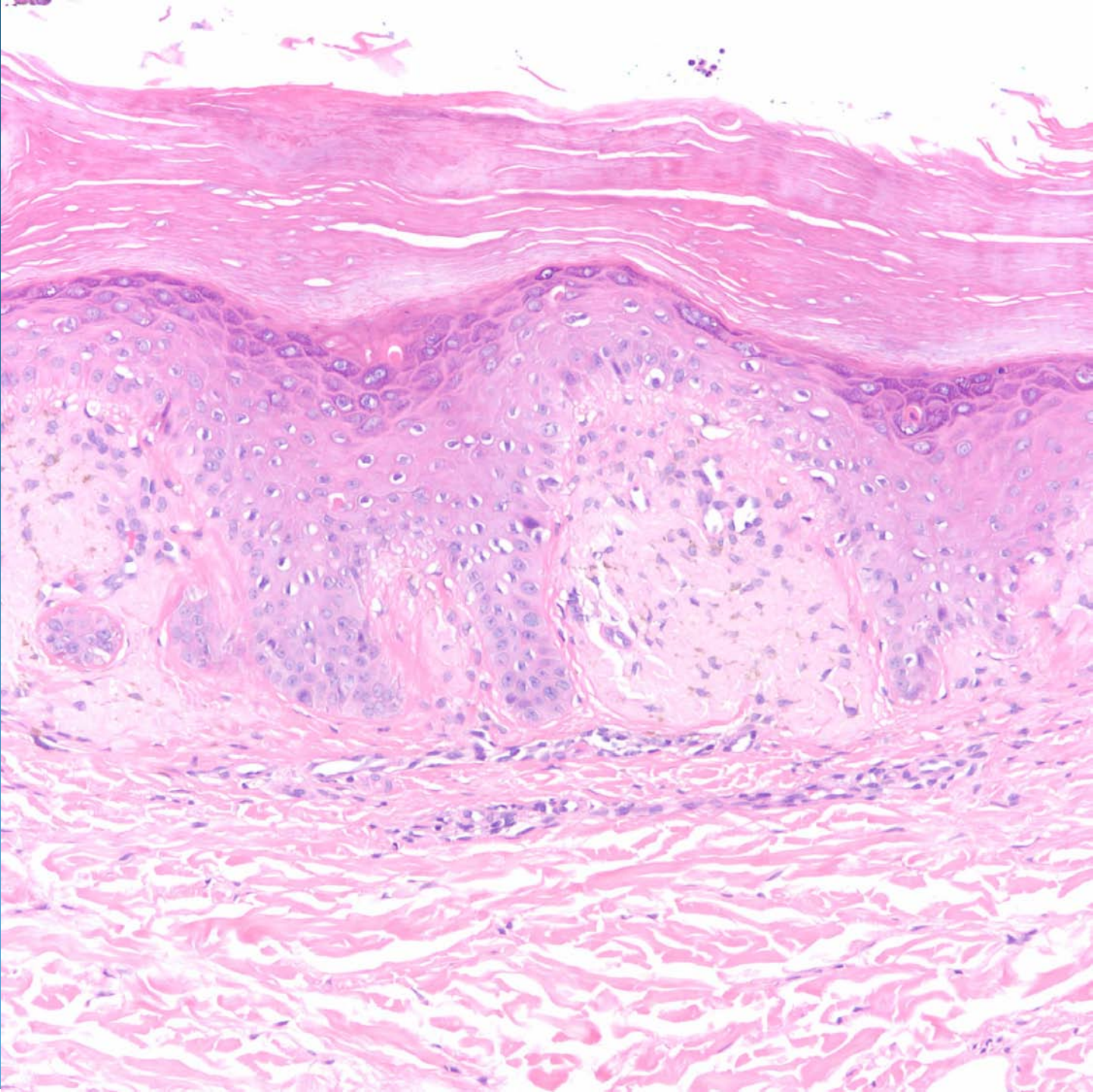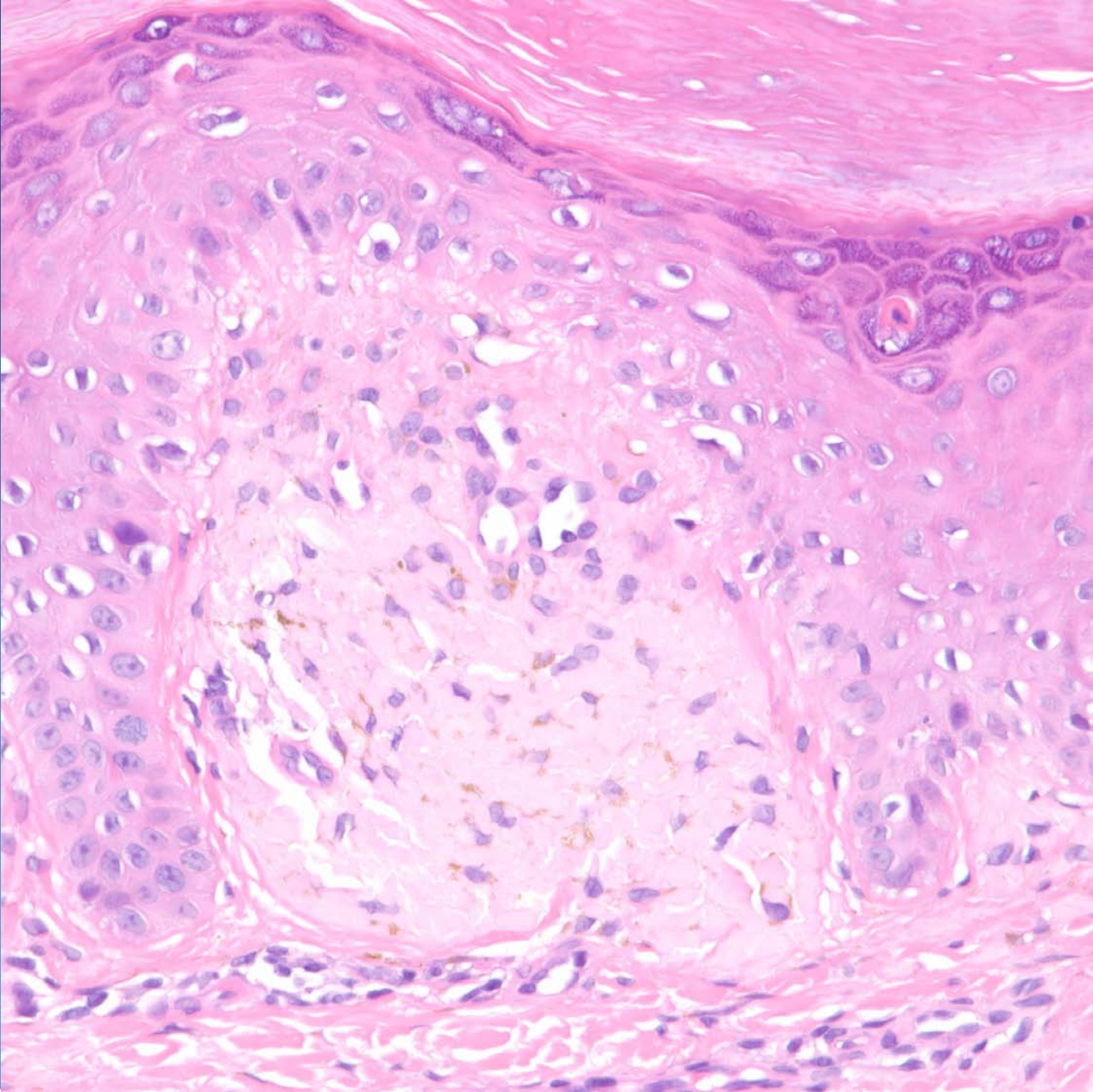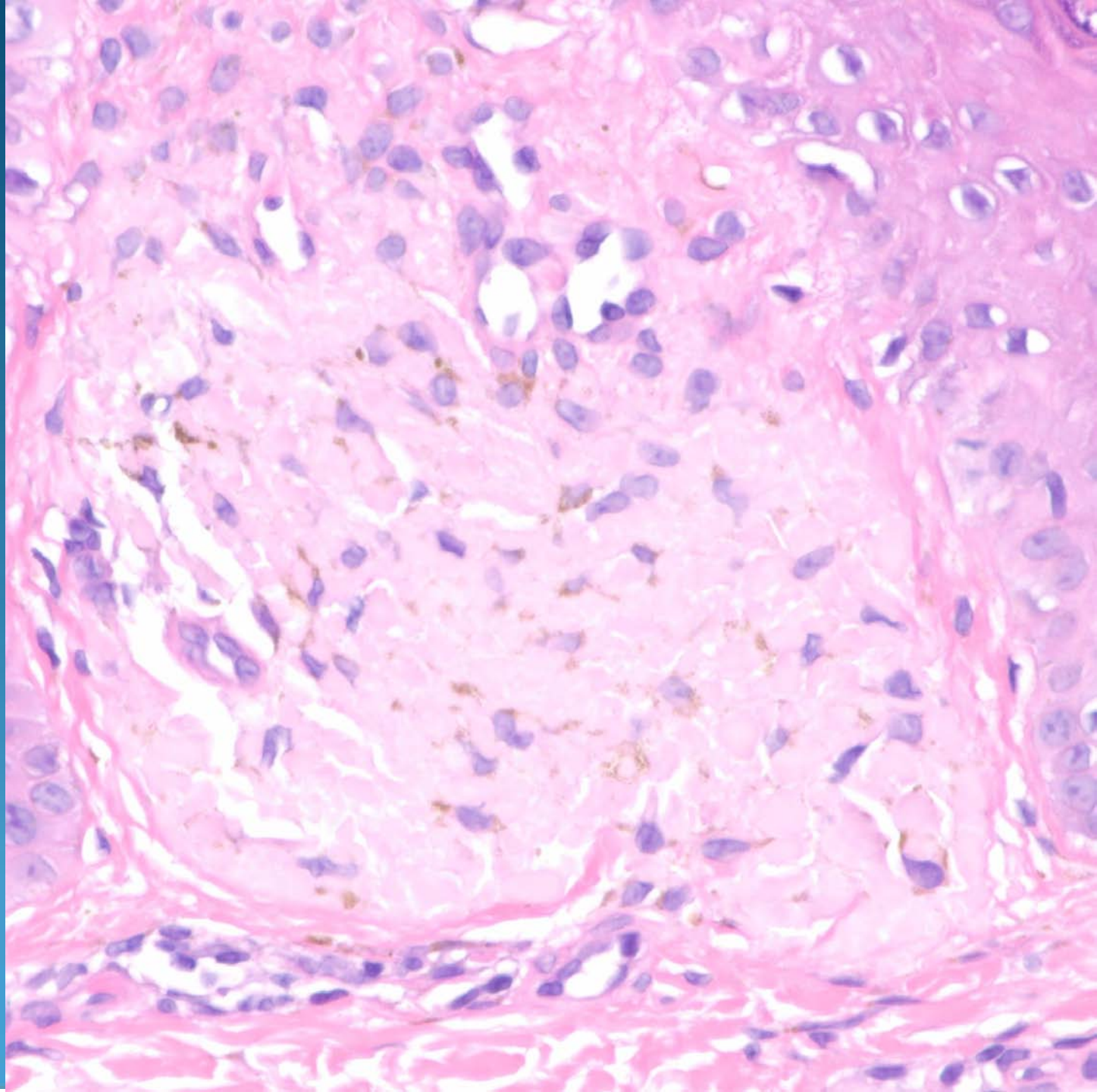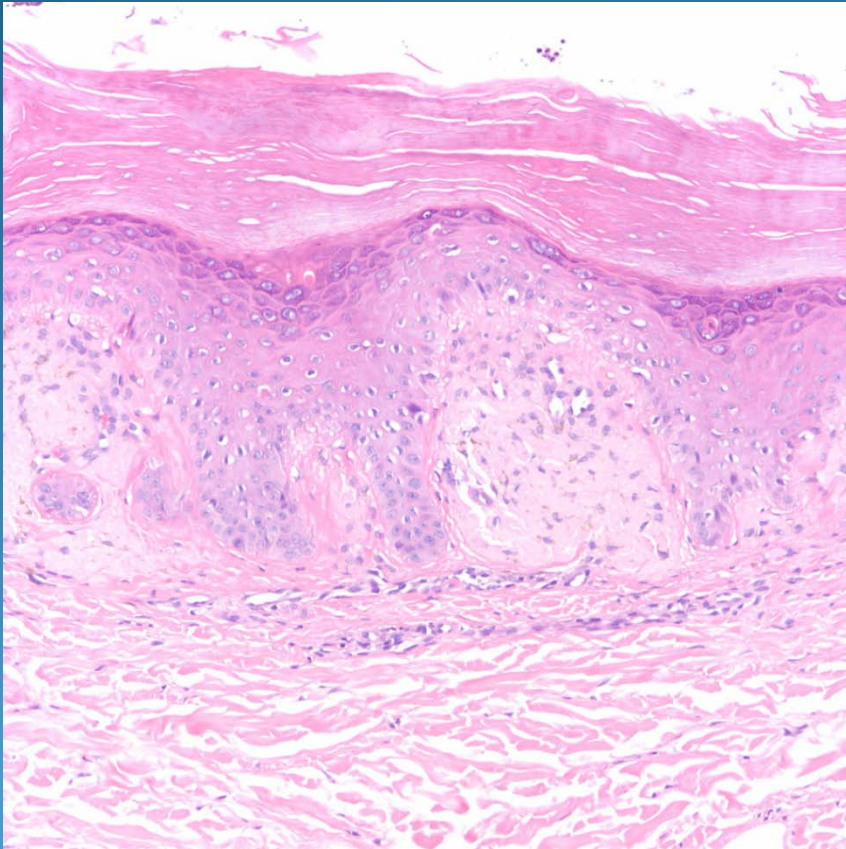


Lichen Amyloidosis

Pearls



- Hyperplastic epidermis overlying dermal papillary collections of hyalinized material
- Associated with melanophages
- Usually Congo red negative, typical for pre-keratin derived amyloid
- DDX: Macular amyloidosis less epidermal hyperplasia