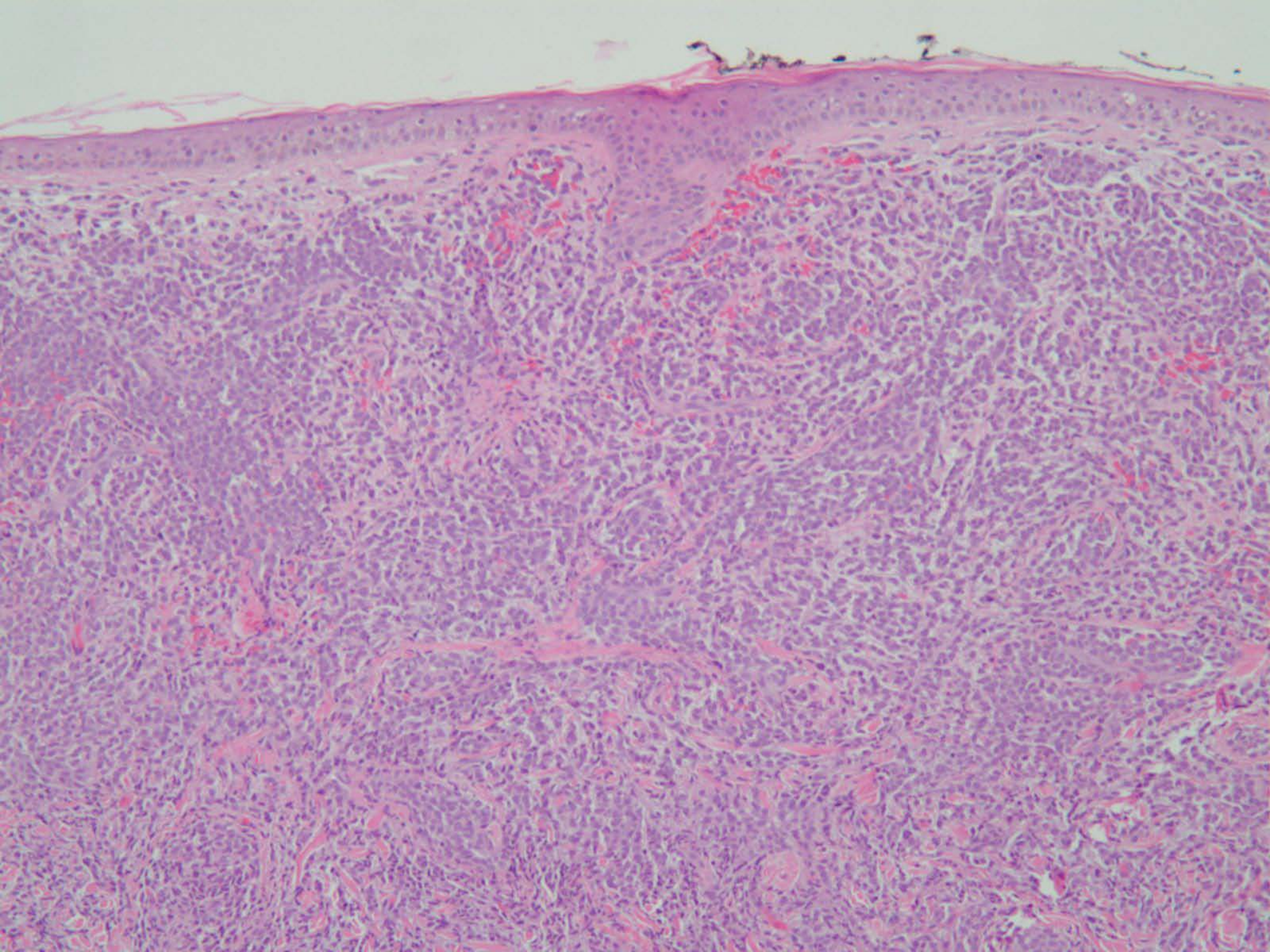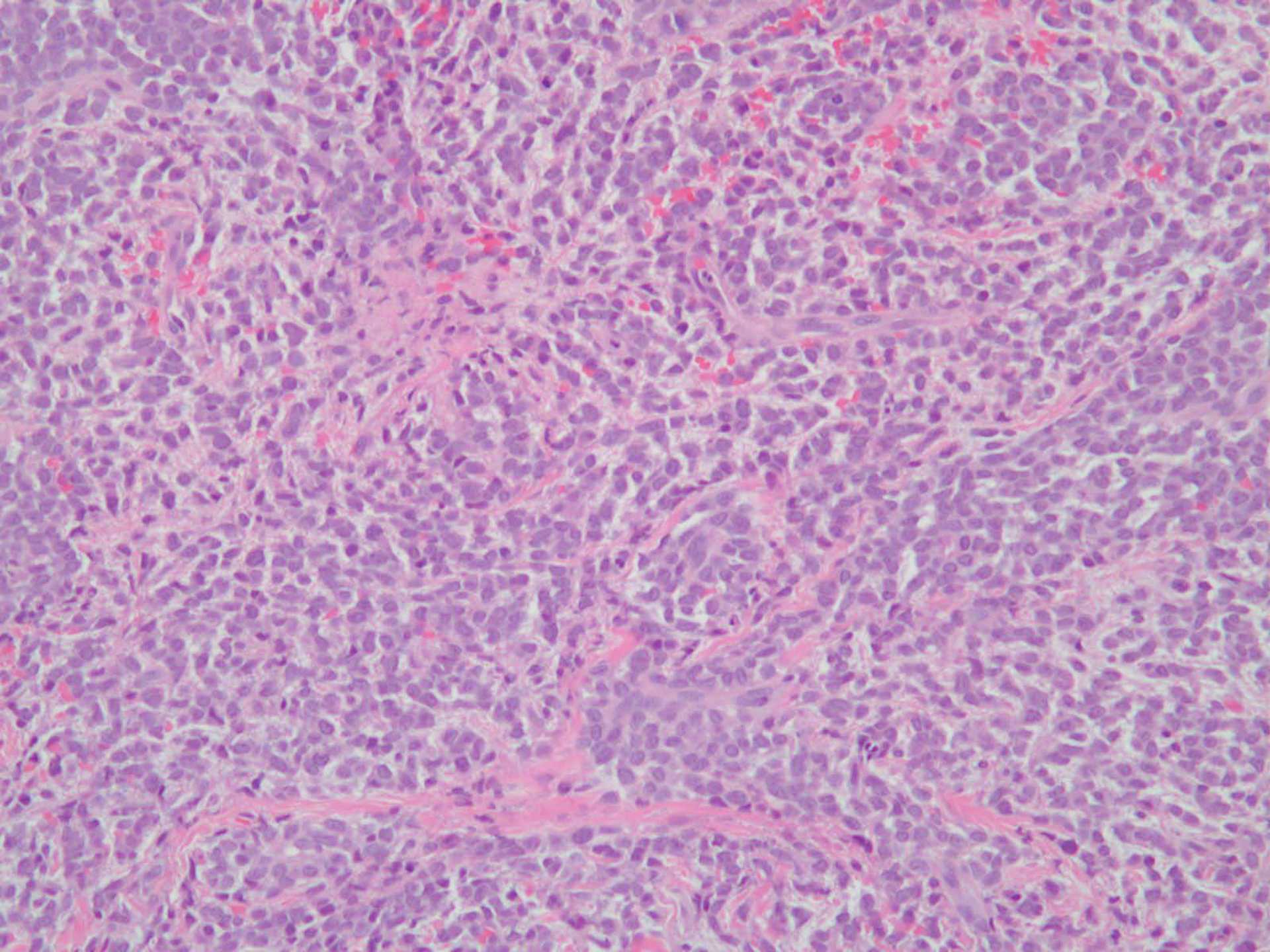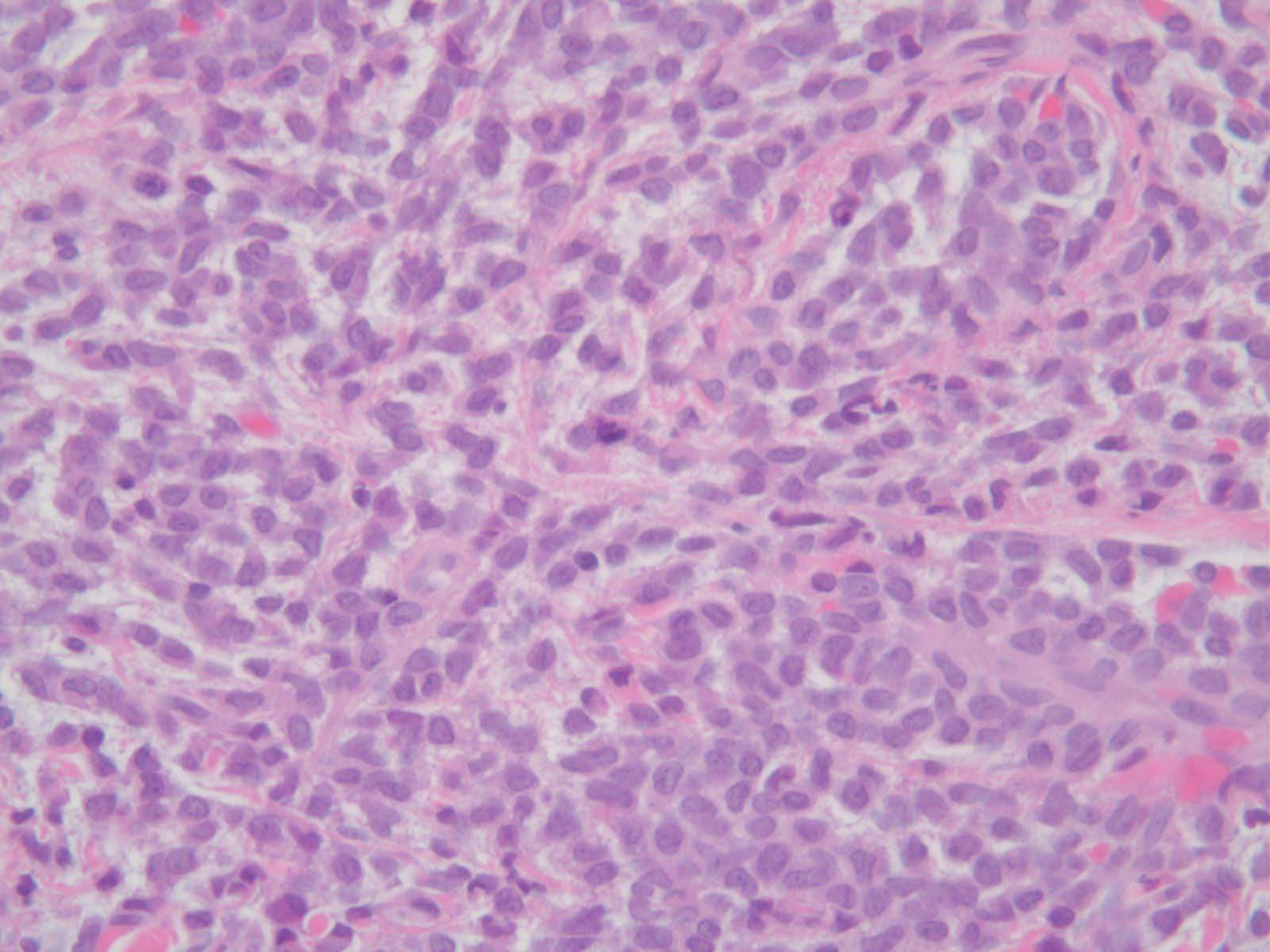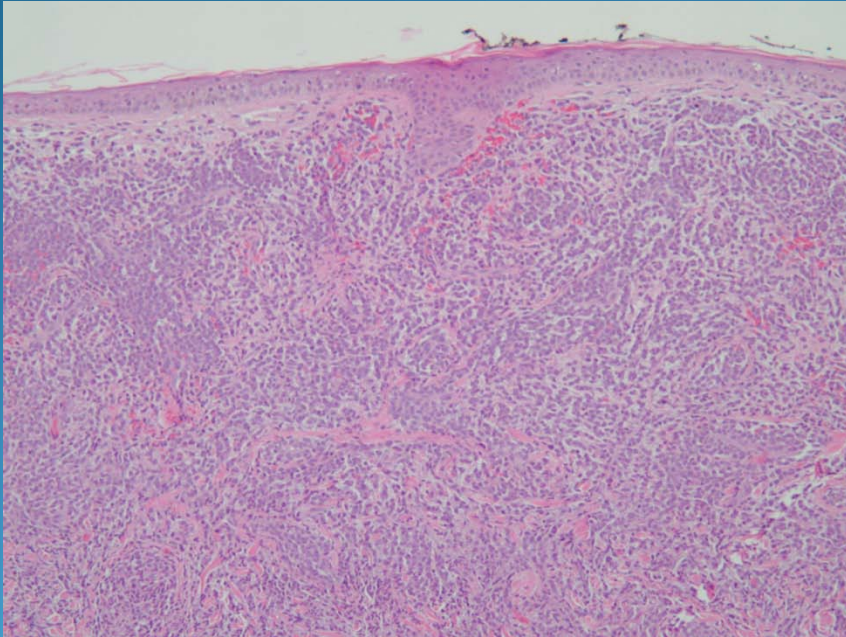


# Leukemia Cutis- Acute Myelogenous Leukemia

# Pearls



- Grenz Zone
- Monomorphic cells either dissecting or replacing the dermis
- Hyperchromatic atypical cells usually with prominent nucleoli
- Rarely see eosinophilic granules