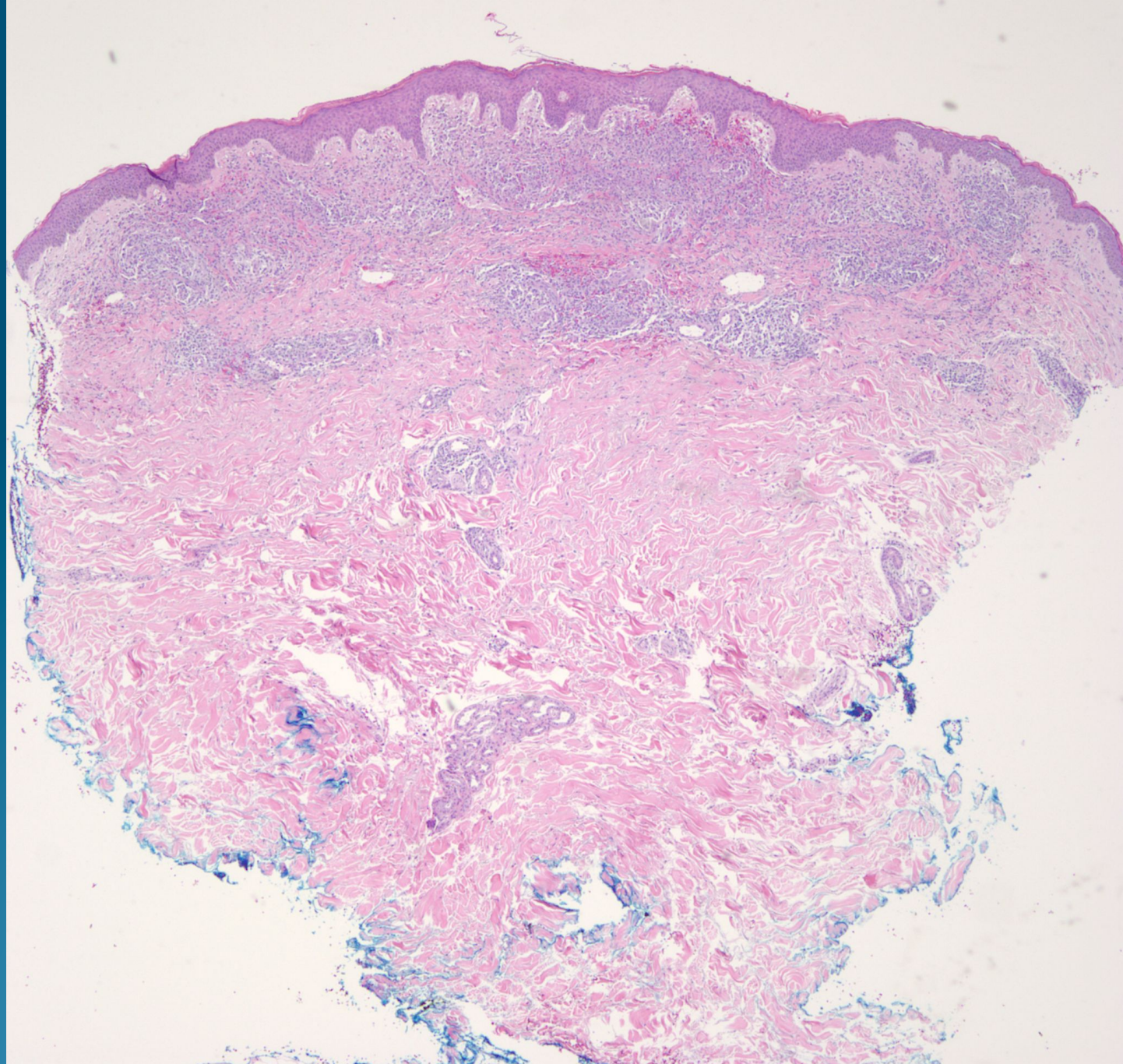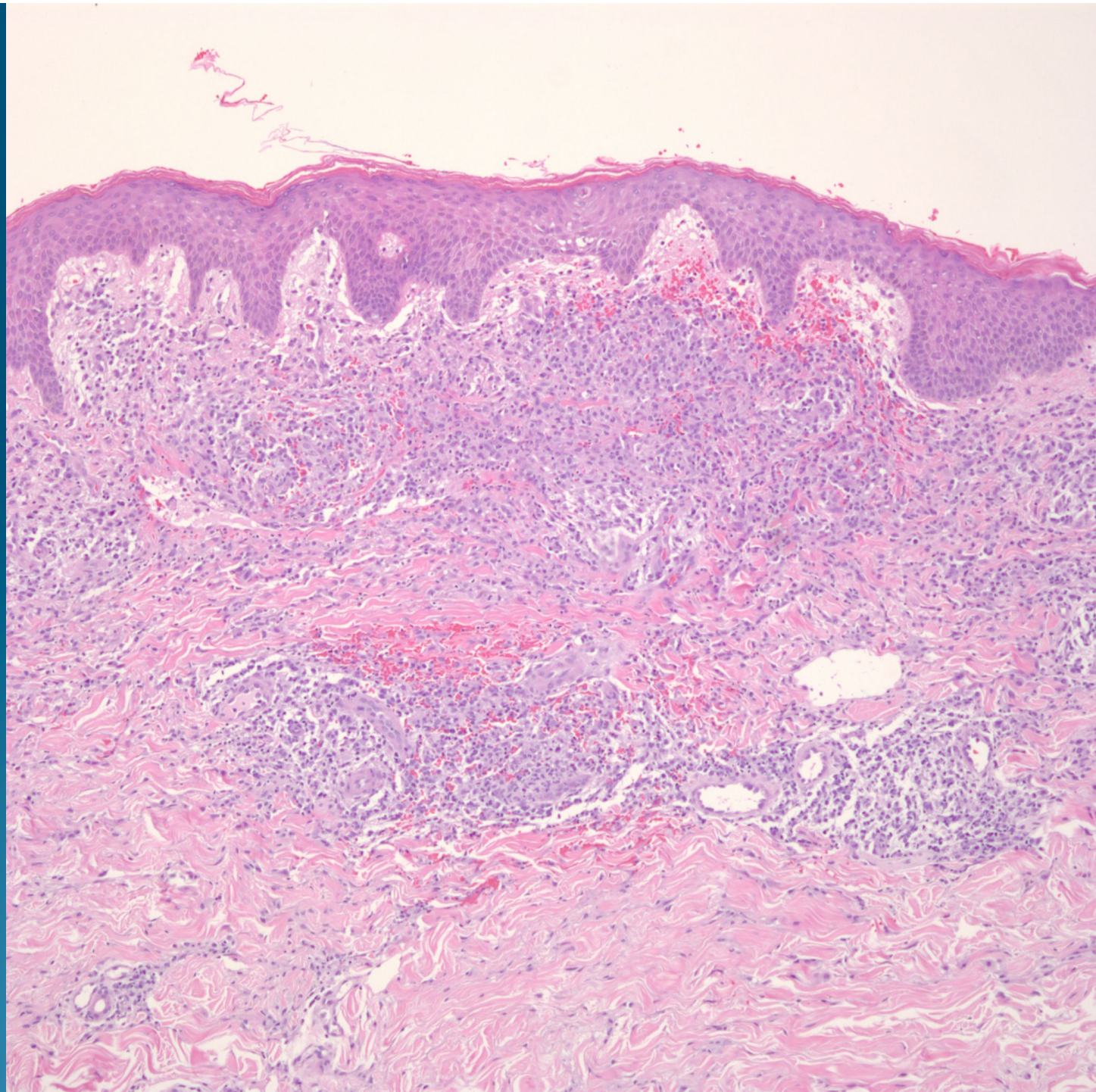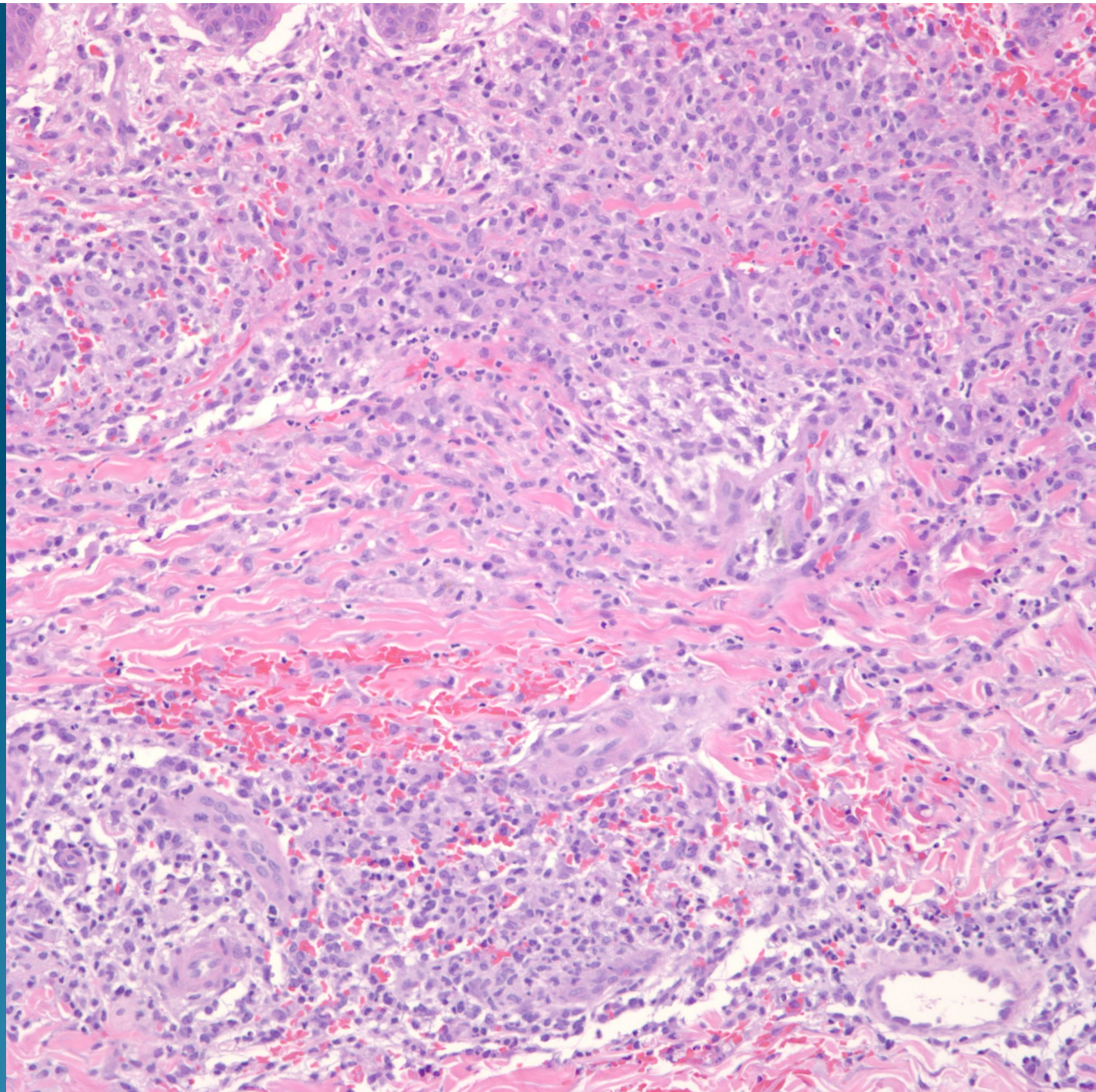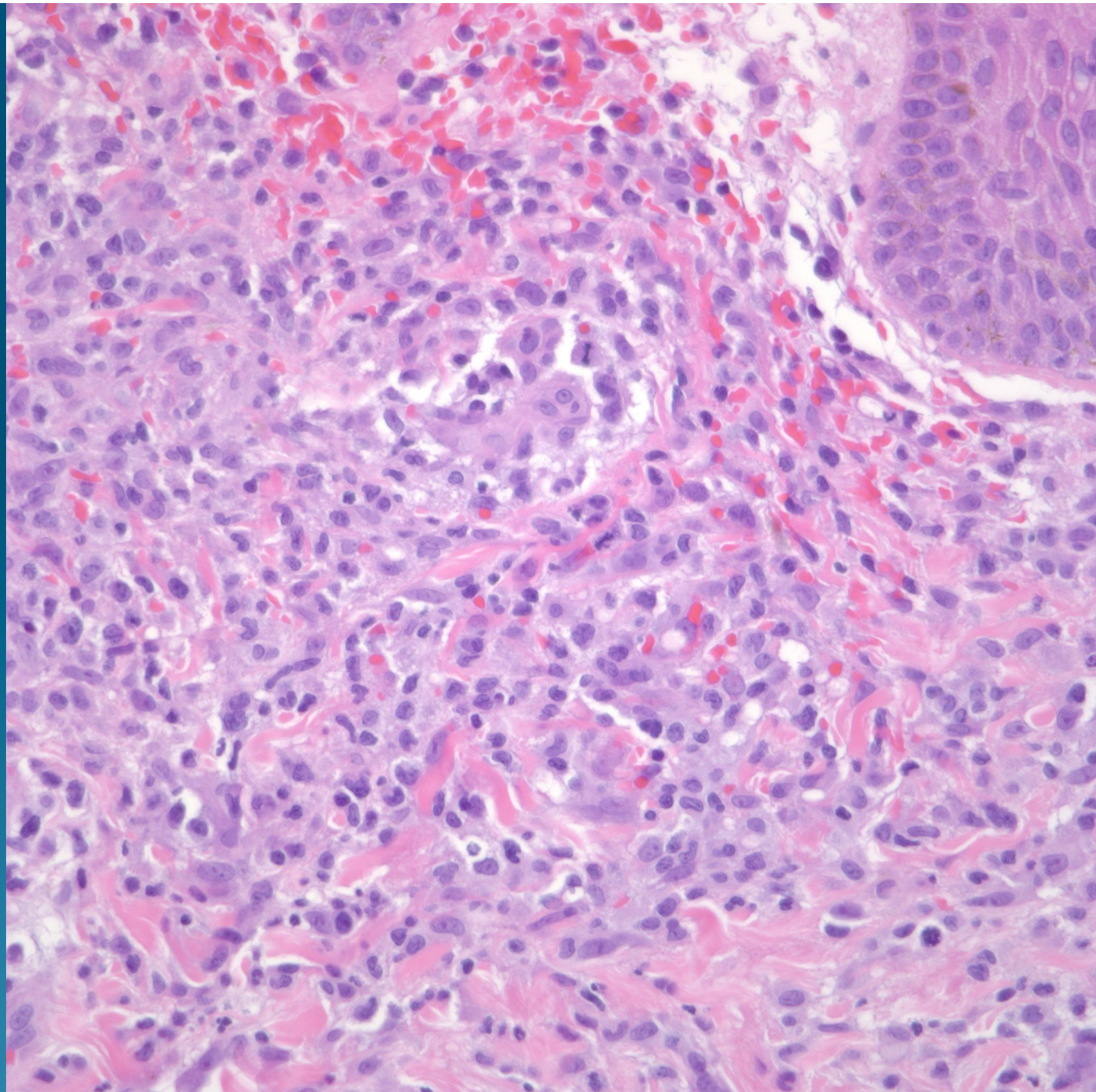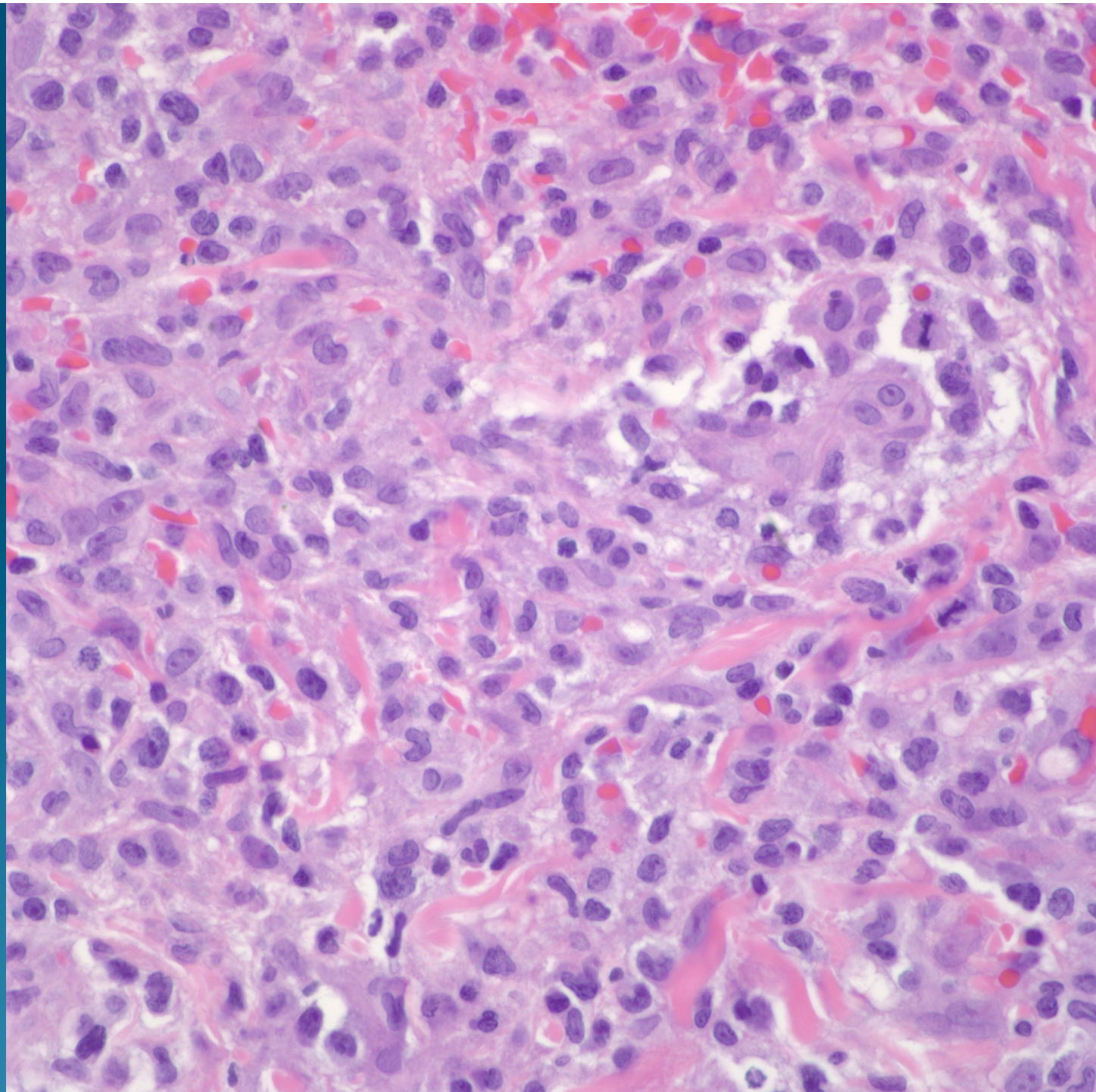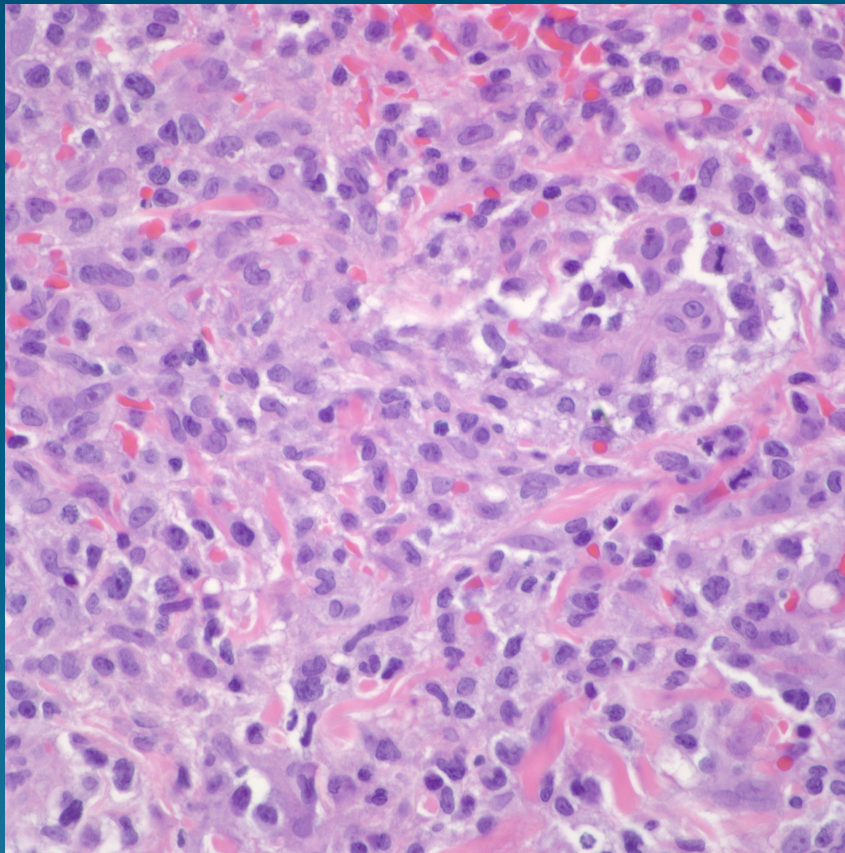


Leukemia Cutis

(Acute myelogenous leukemia)

Pearls



- Diffuse proliferation of atypical lymphoid cells, many with blast morphology
- May see myeloid precursors with eosinophilic granules
- Rule out Peripheral T-cell lymphoma, lymphomatoid papulosis, anaplastic lymphoma
- IHC stains and clinical history helpful but beware aleukemic leukemia cutis