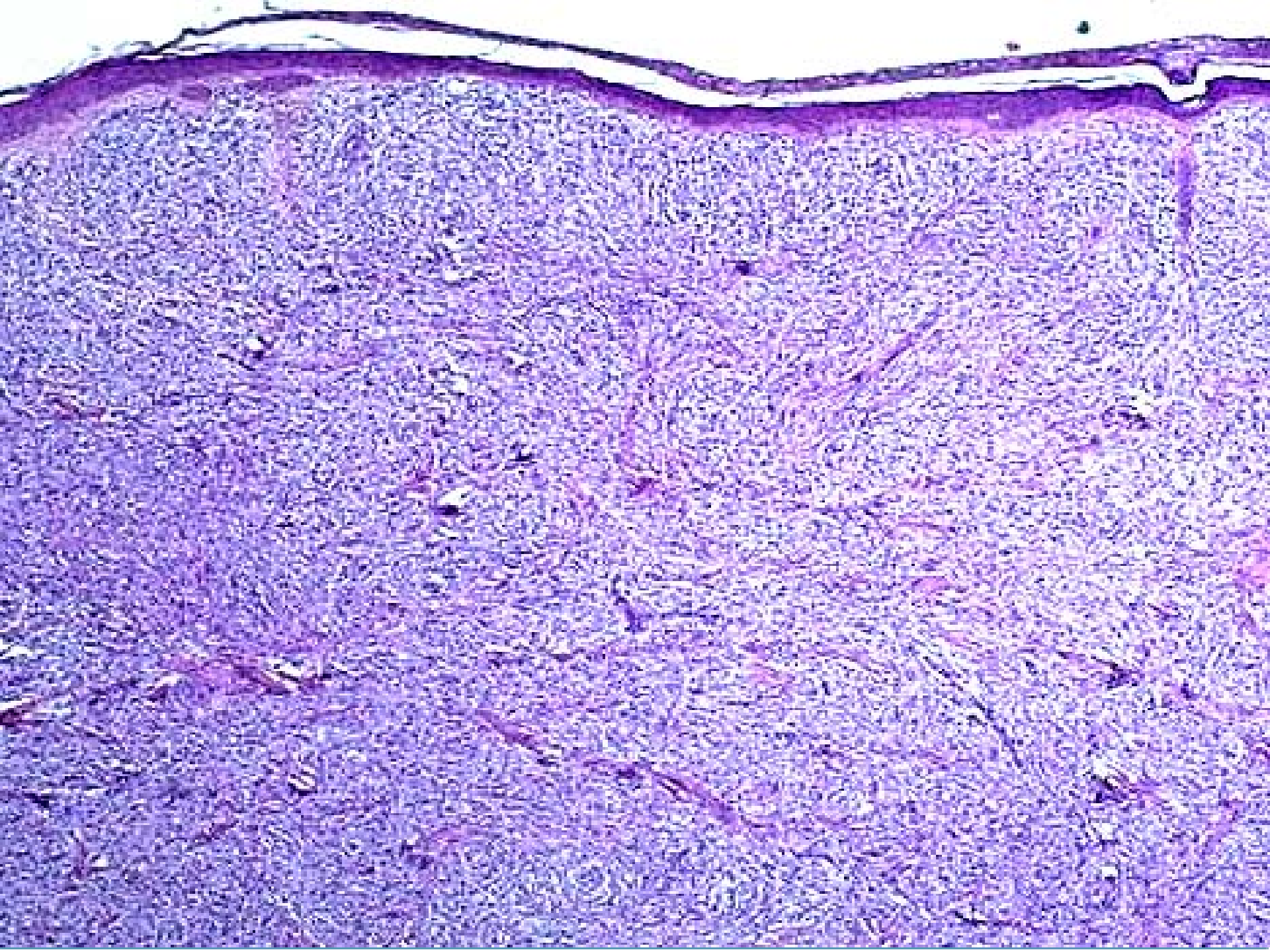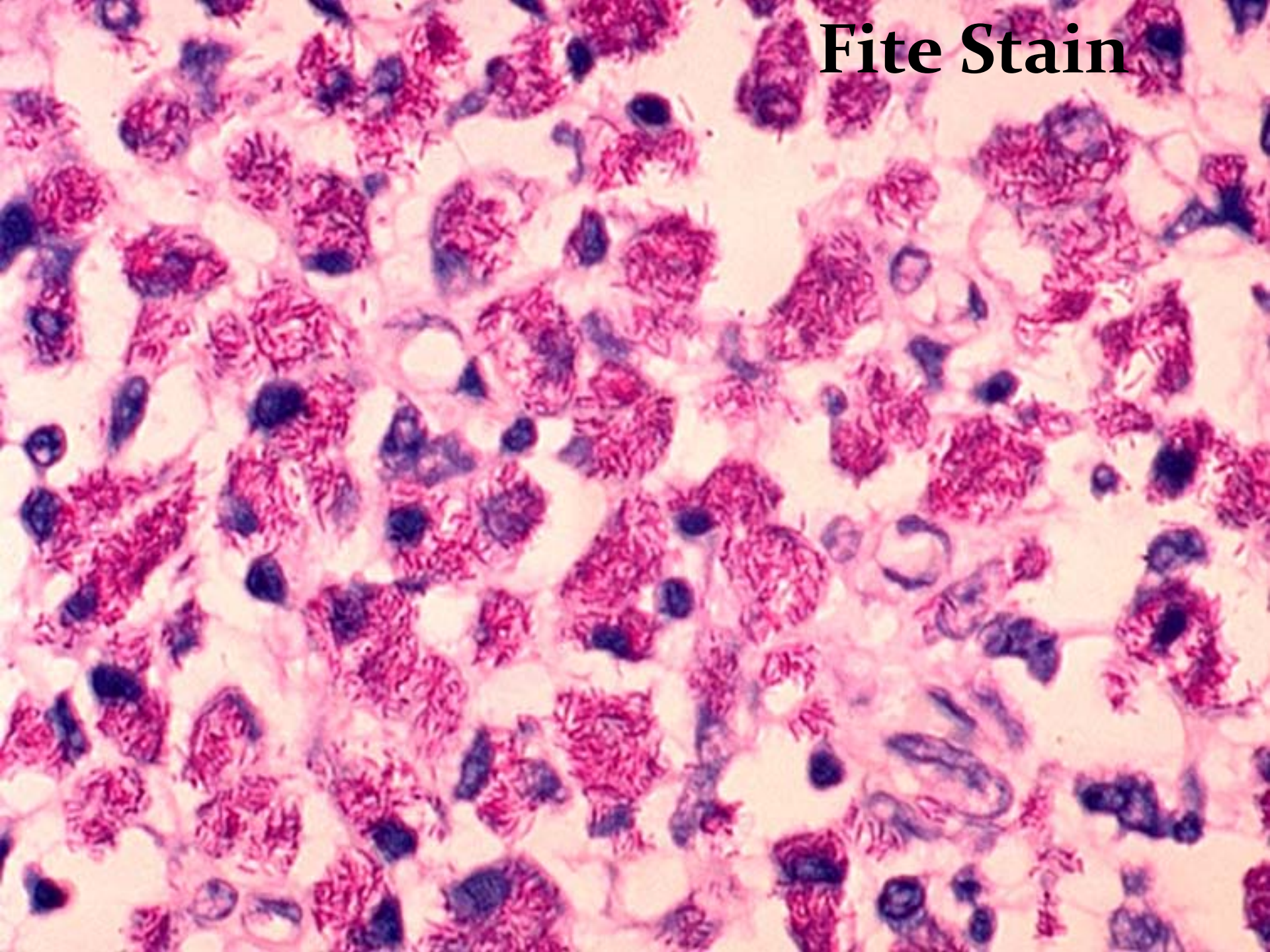
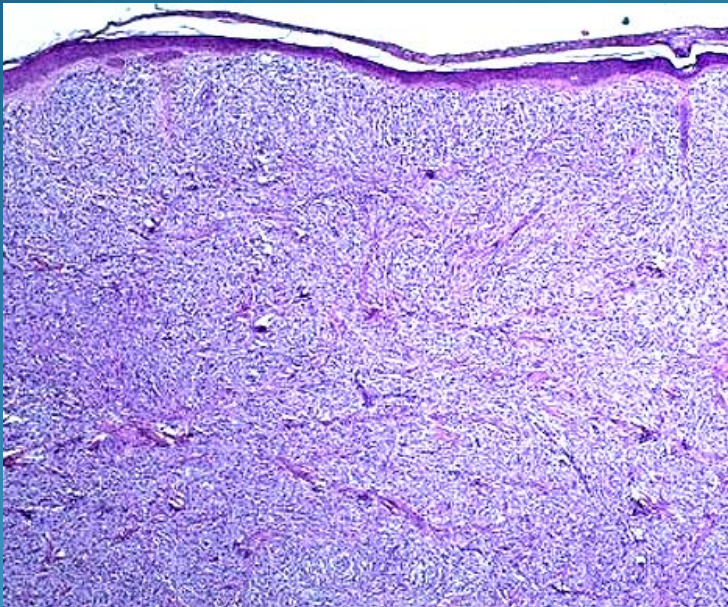


Fite Stain



Lepromatous Leprosy

Pearls



- Grenz zone
- Diffuse replacement of dermis with foamy histiocytes
- Confirm with Fite stain