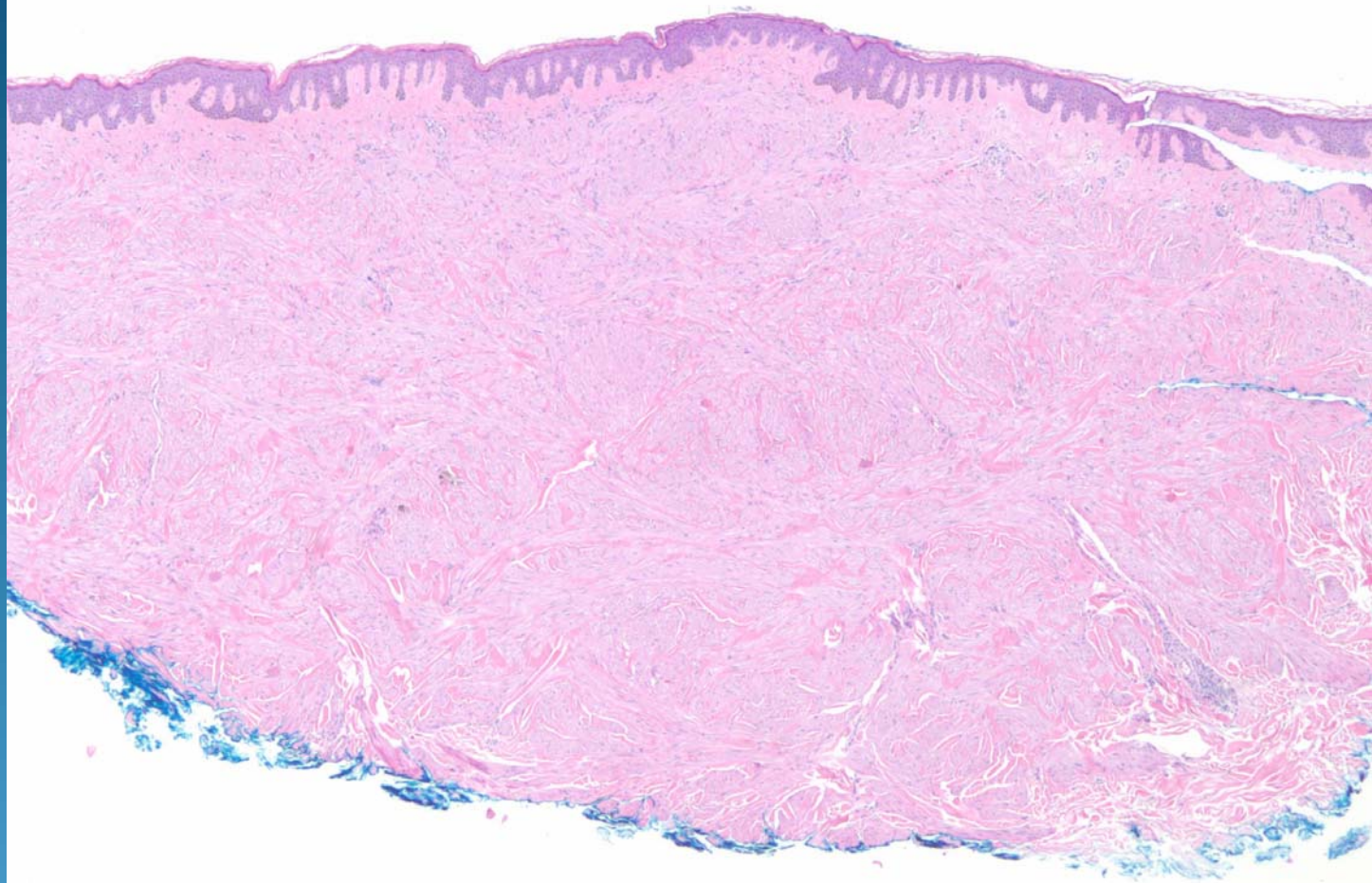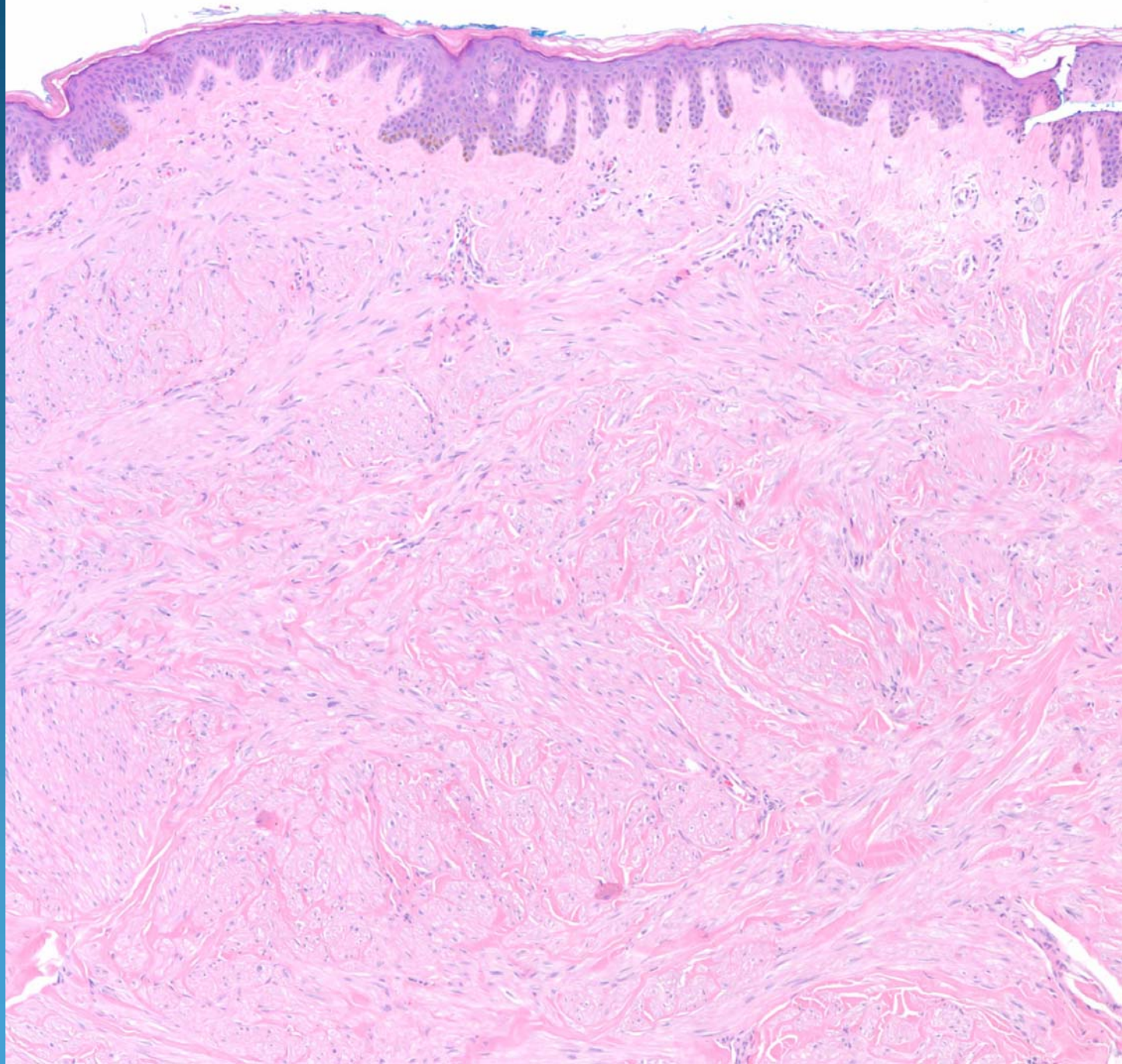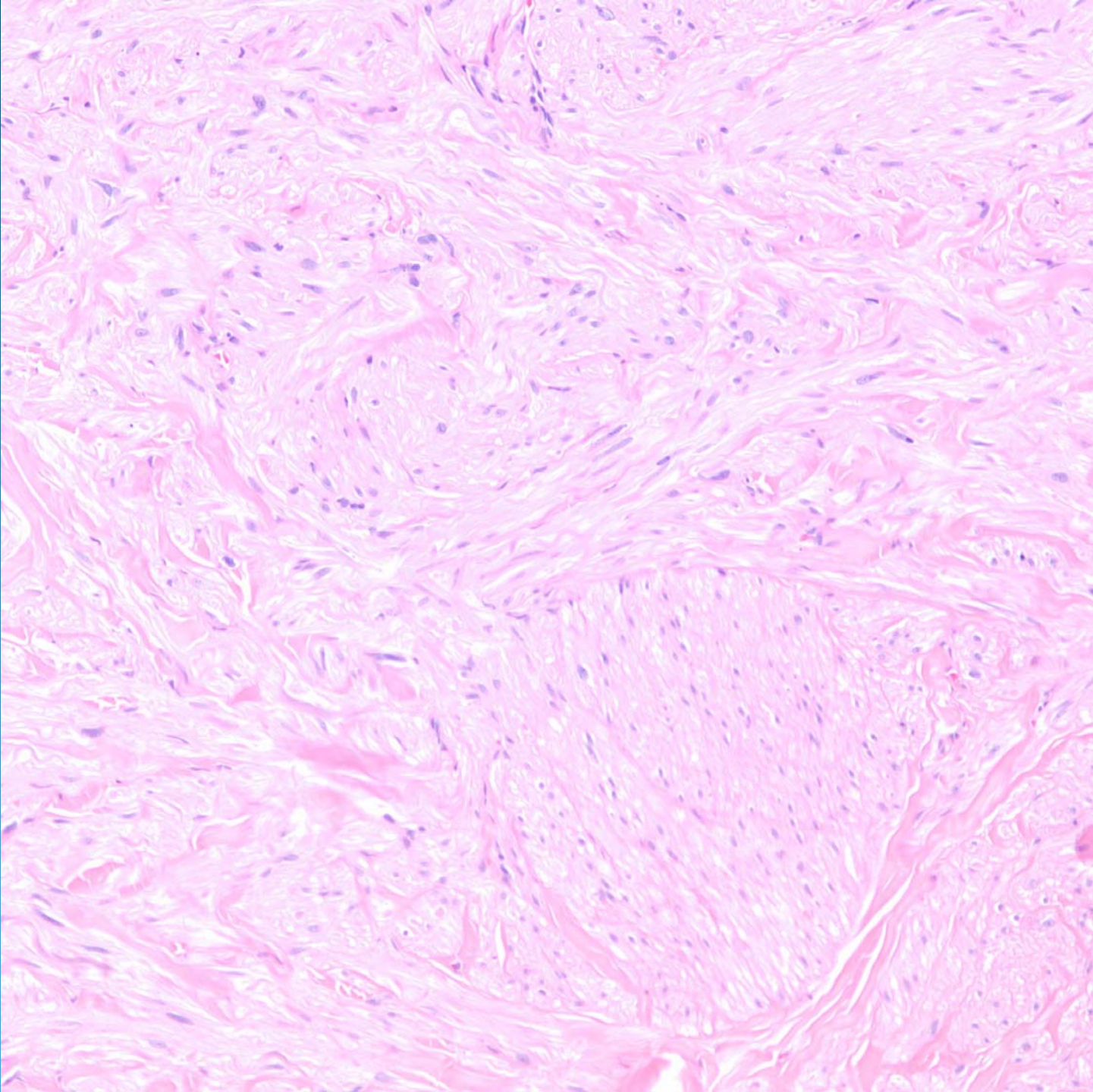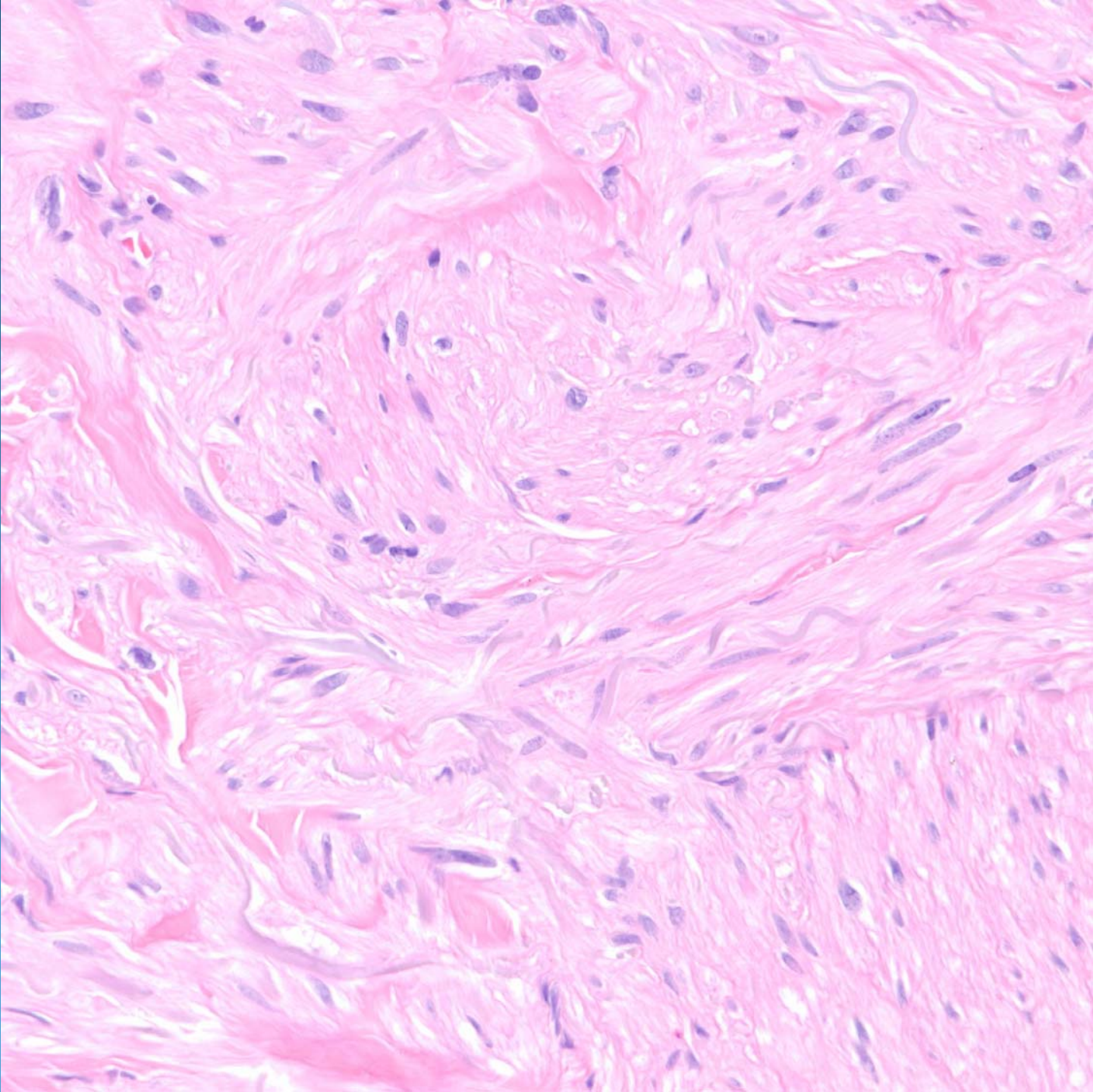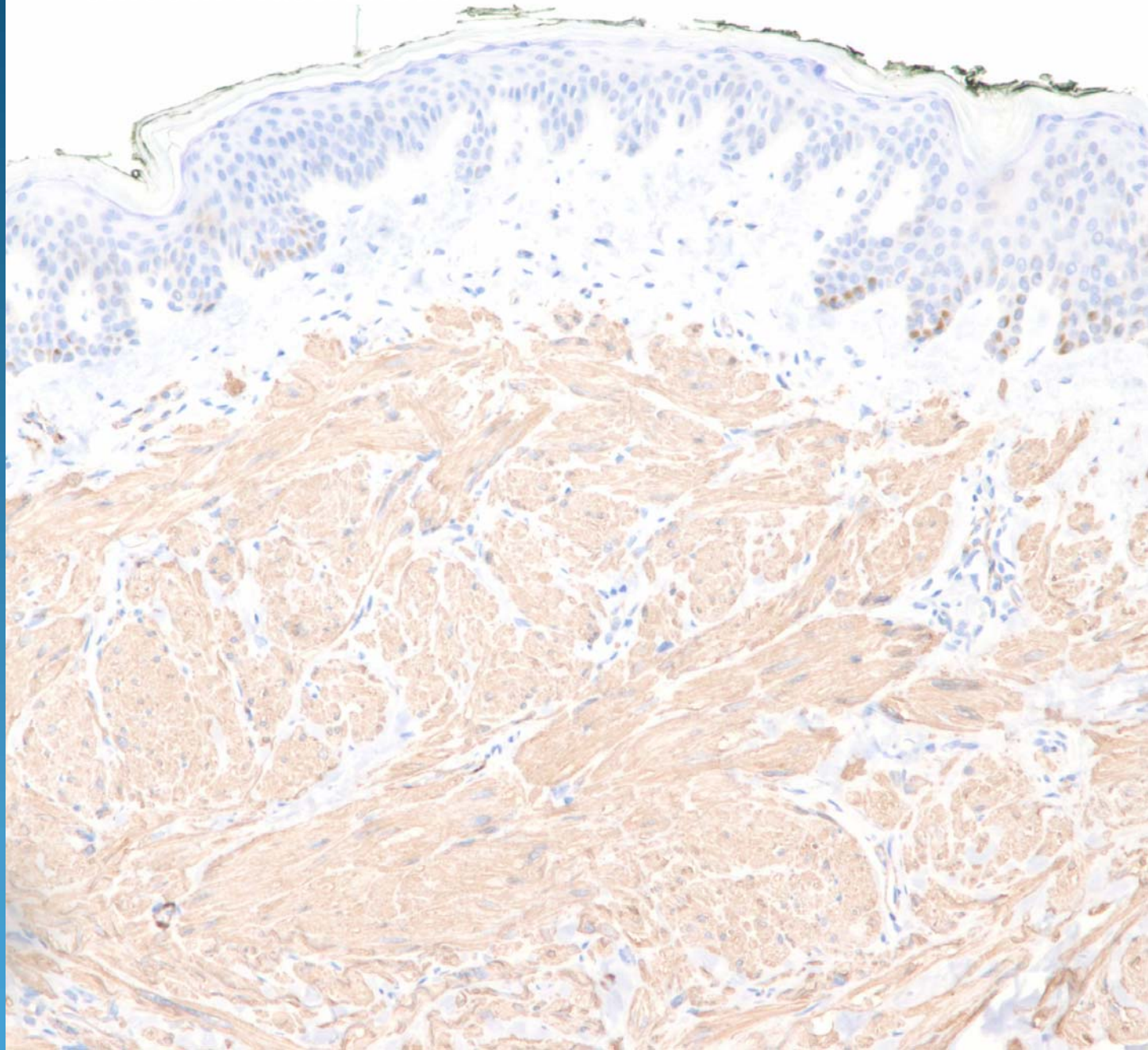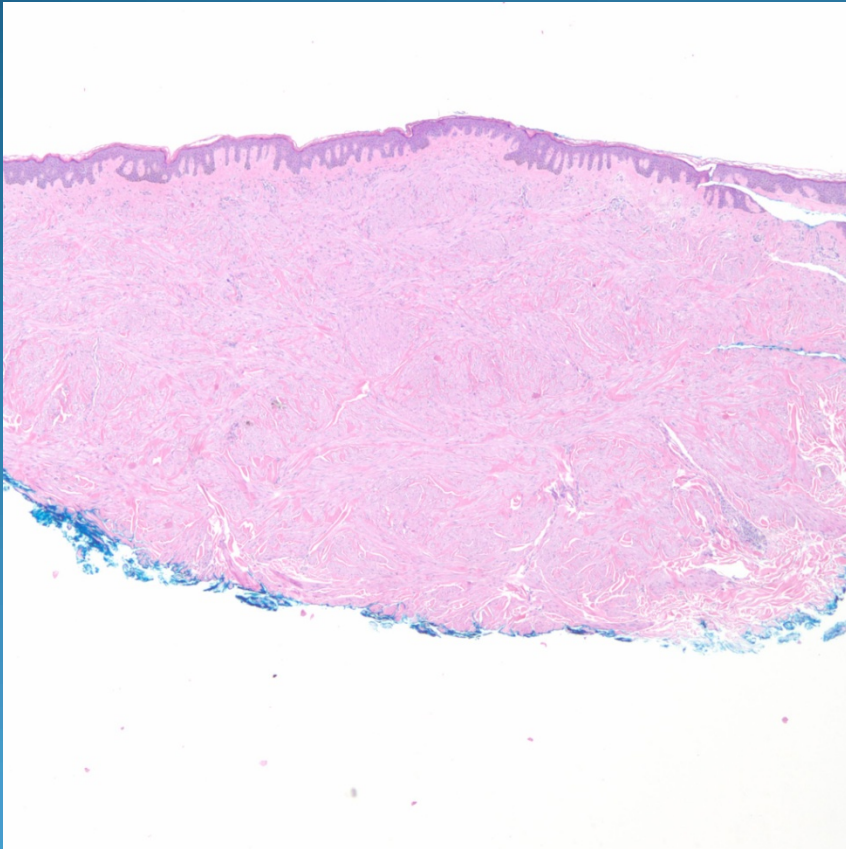


# Cutaneous Leiomyoma

# Pearls



- Partly circumscribed proliferation of bland spindle cells
- Slender nuclei may show perinuclear halo
- Minimal atypia and rare typical mitotic figures
- May confirm with smooth muscle actin IHC