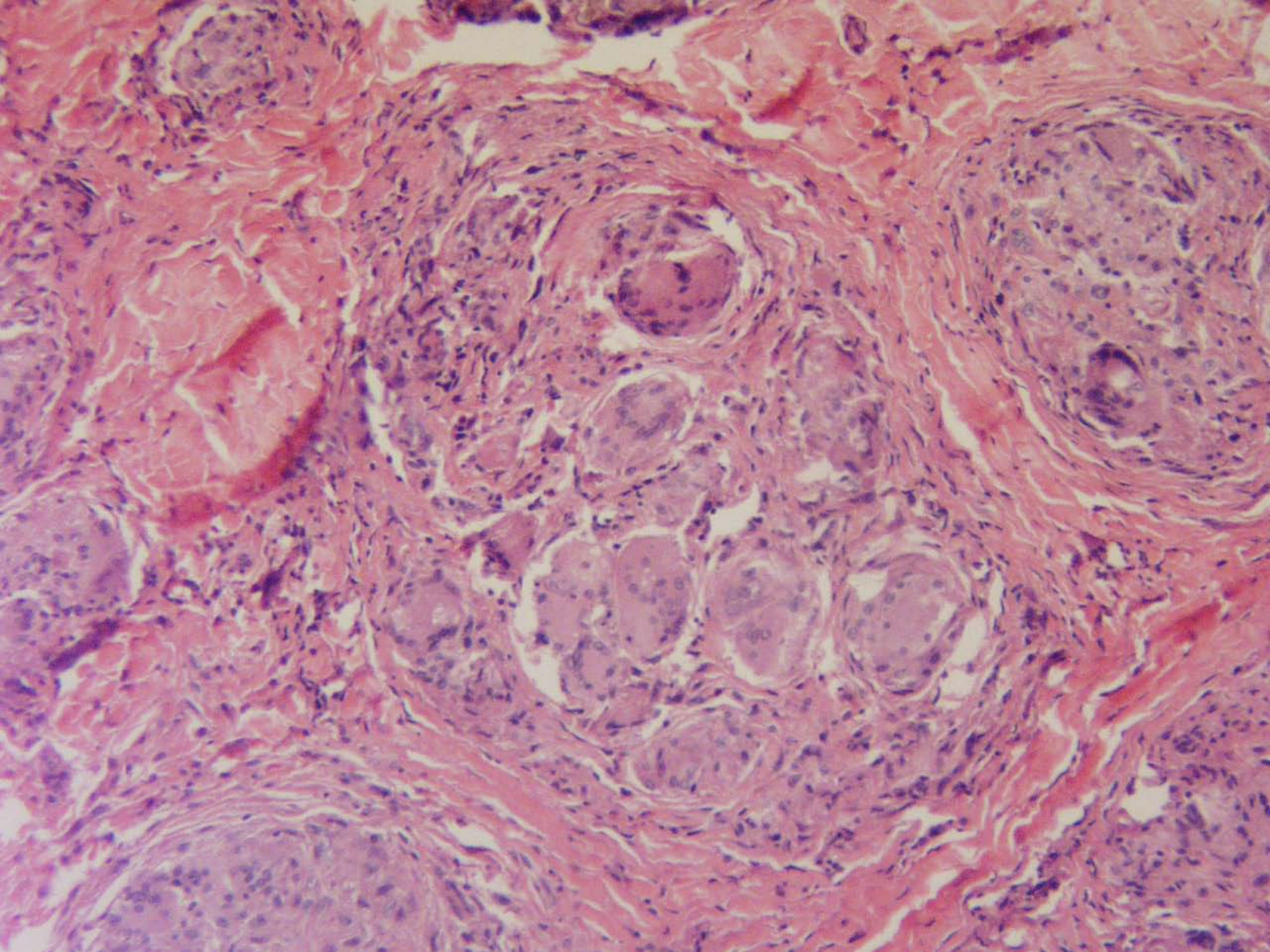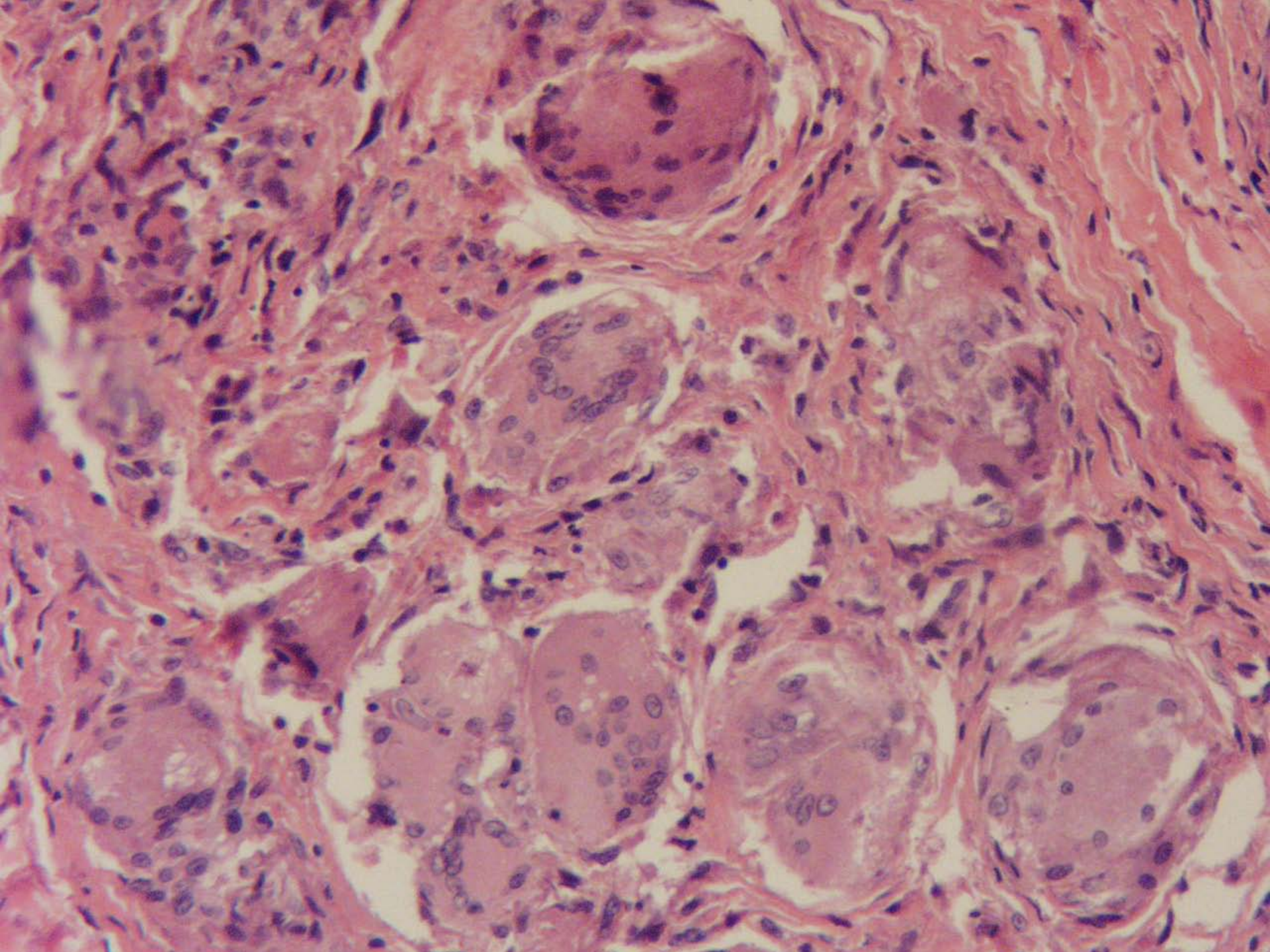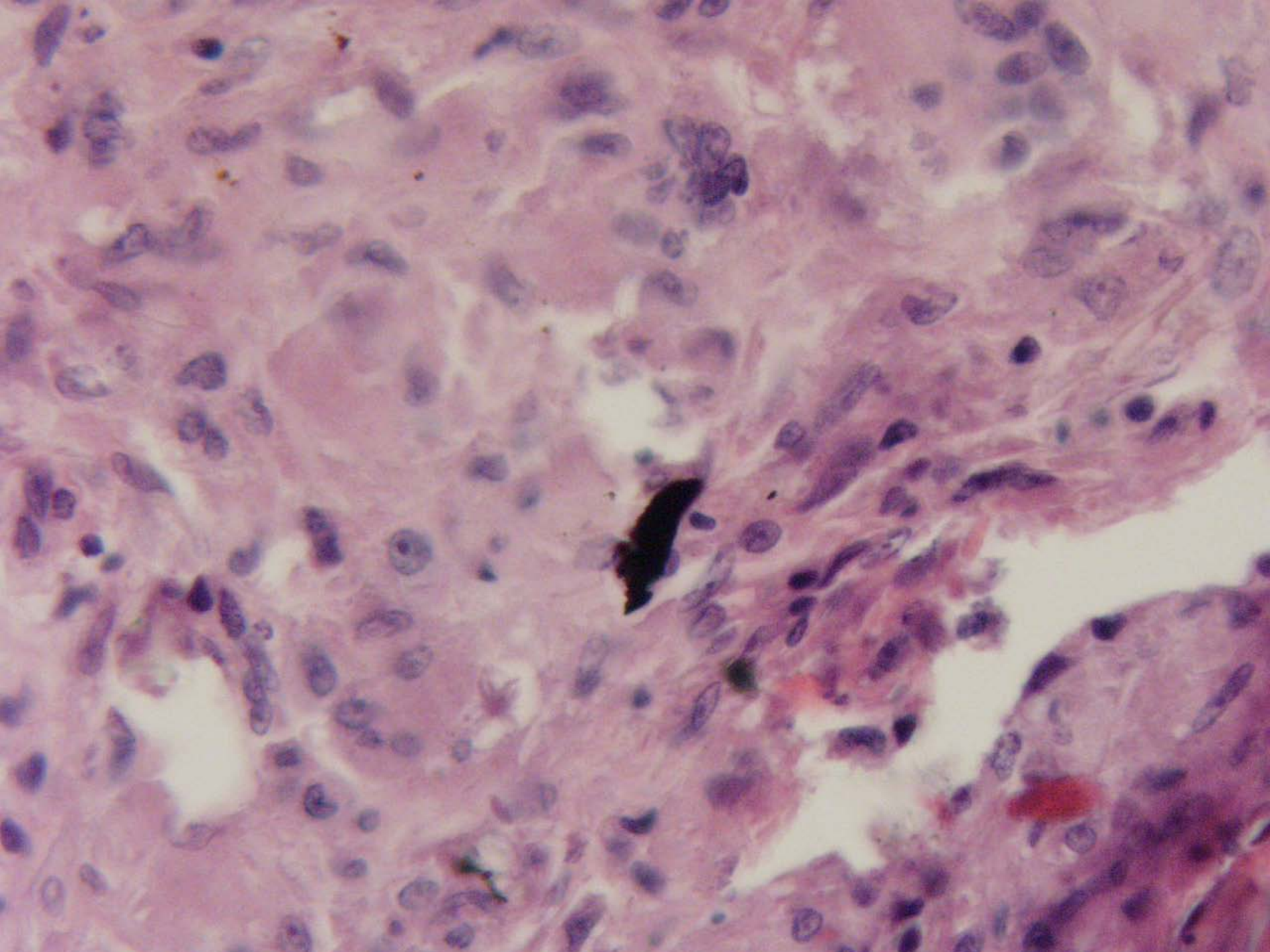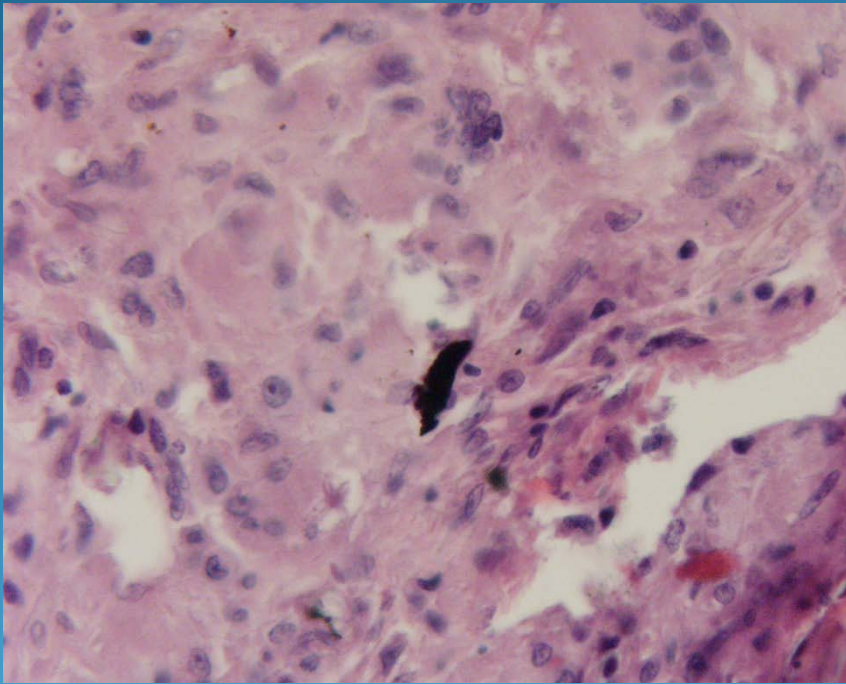


Tattoo, Lead

Pearls



- Jet black amorphous deposit, usually perivascular
- Rule out melanin, argyria, minocycline
- May have sarcoidal granulomatous reaction