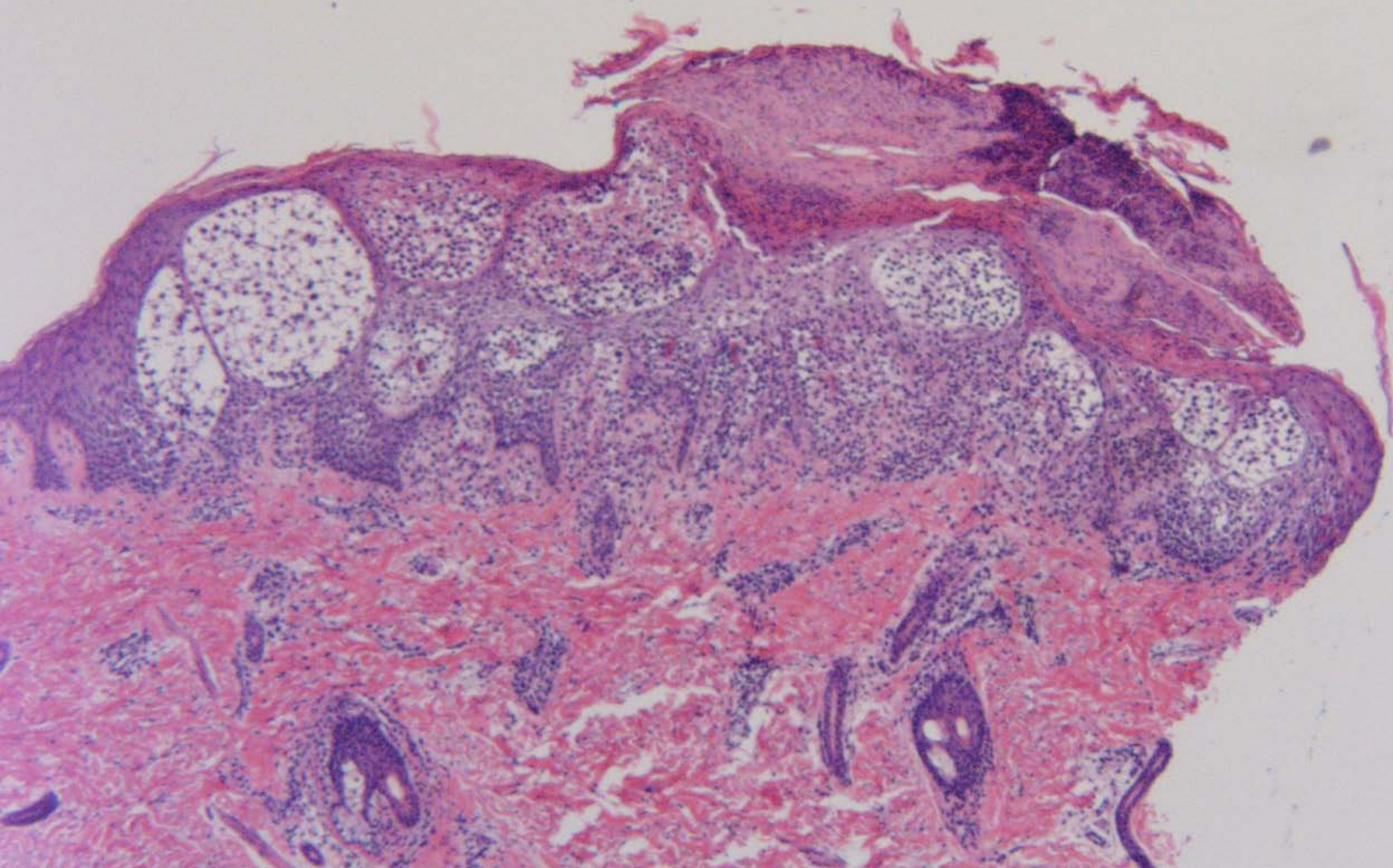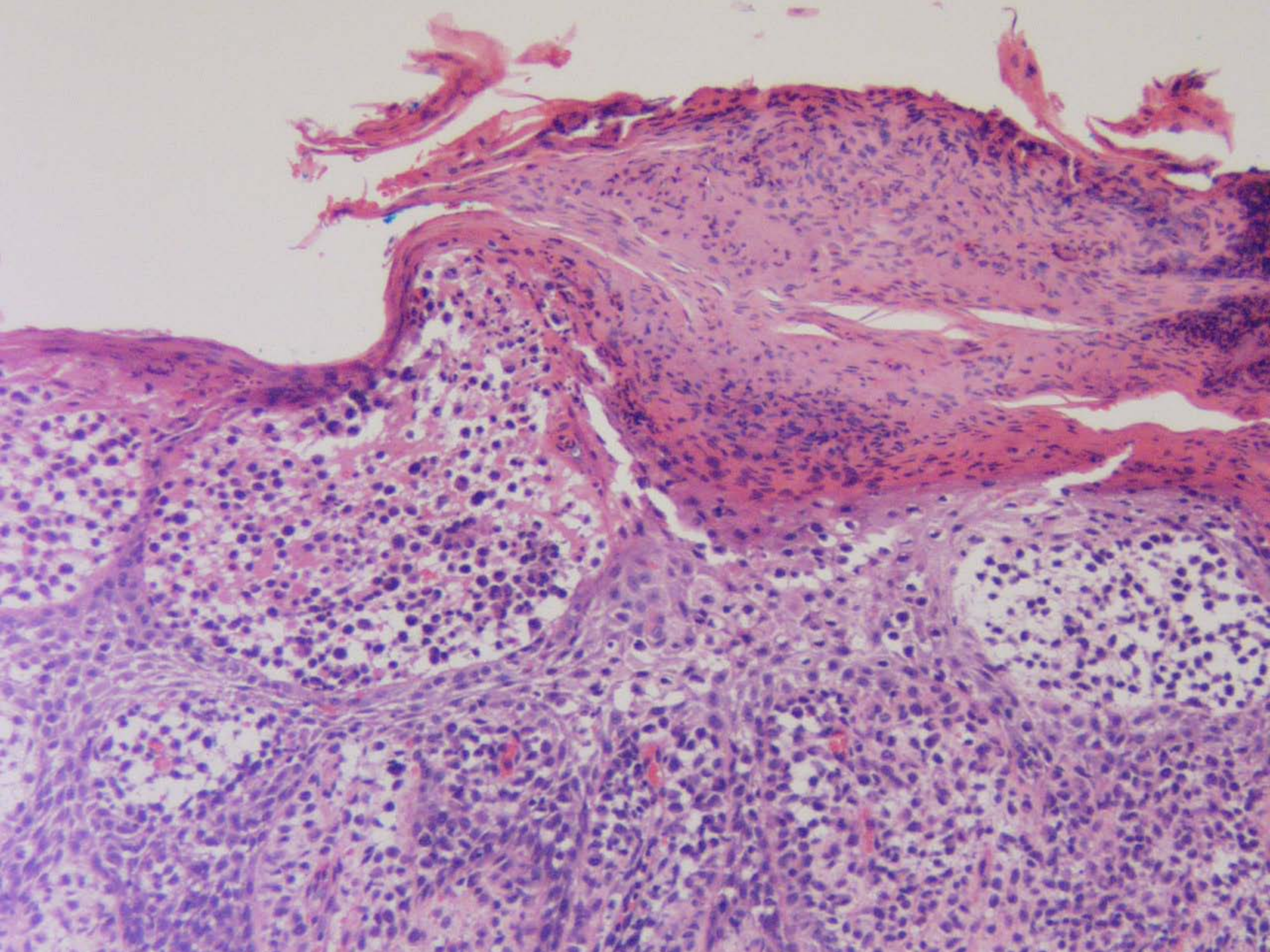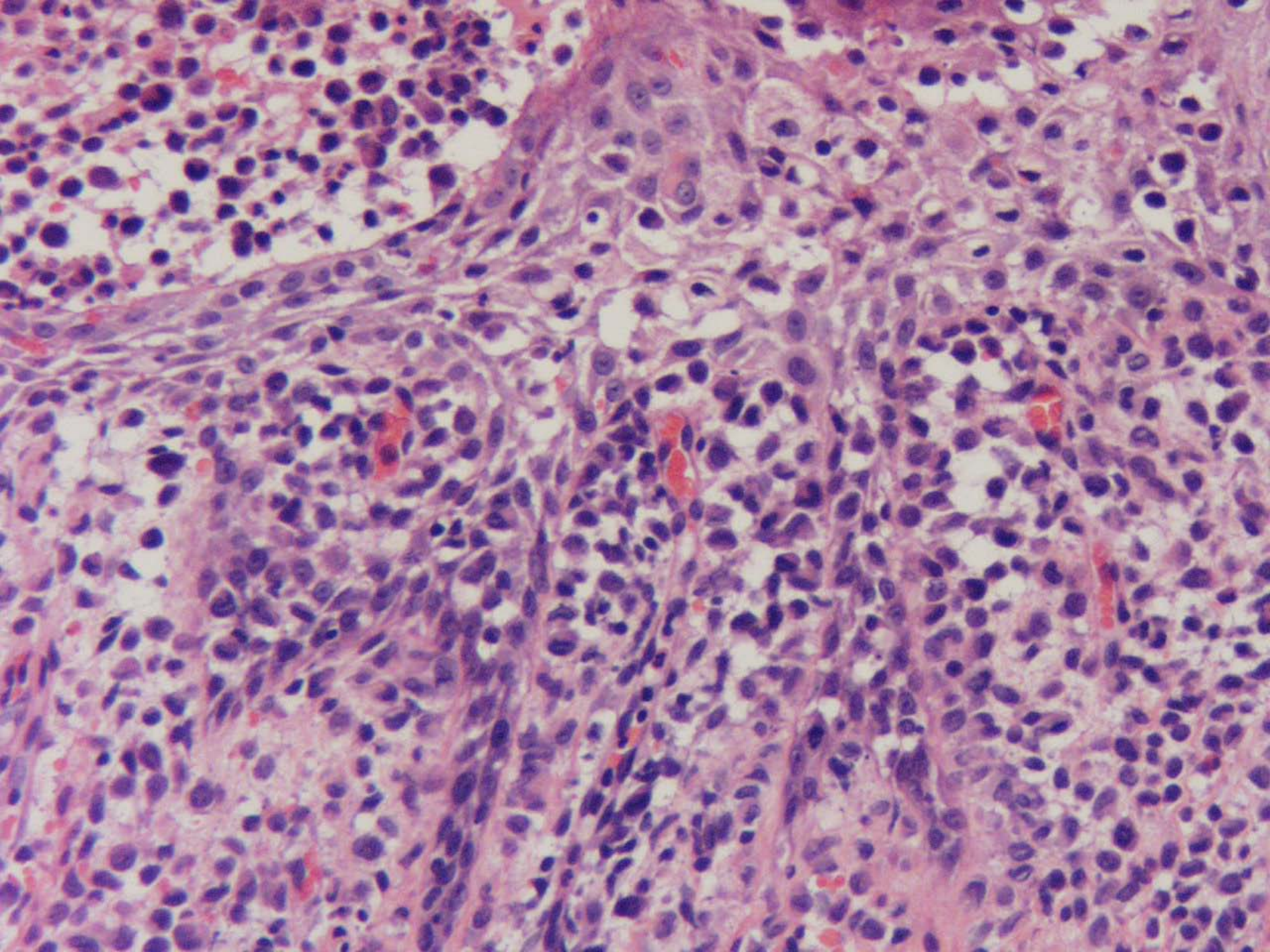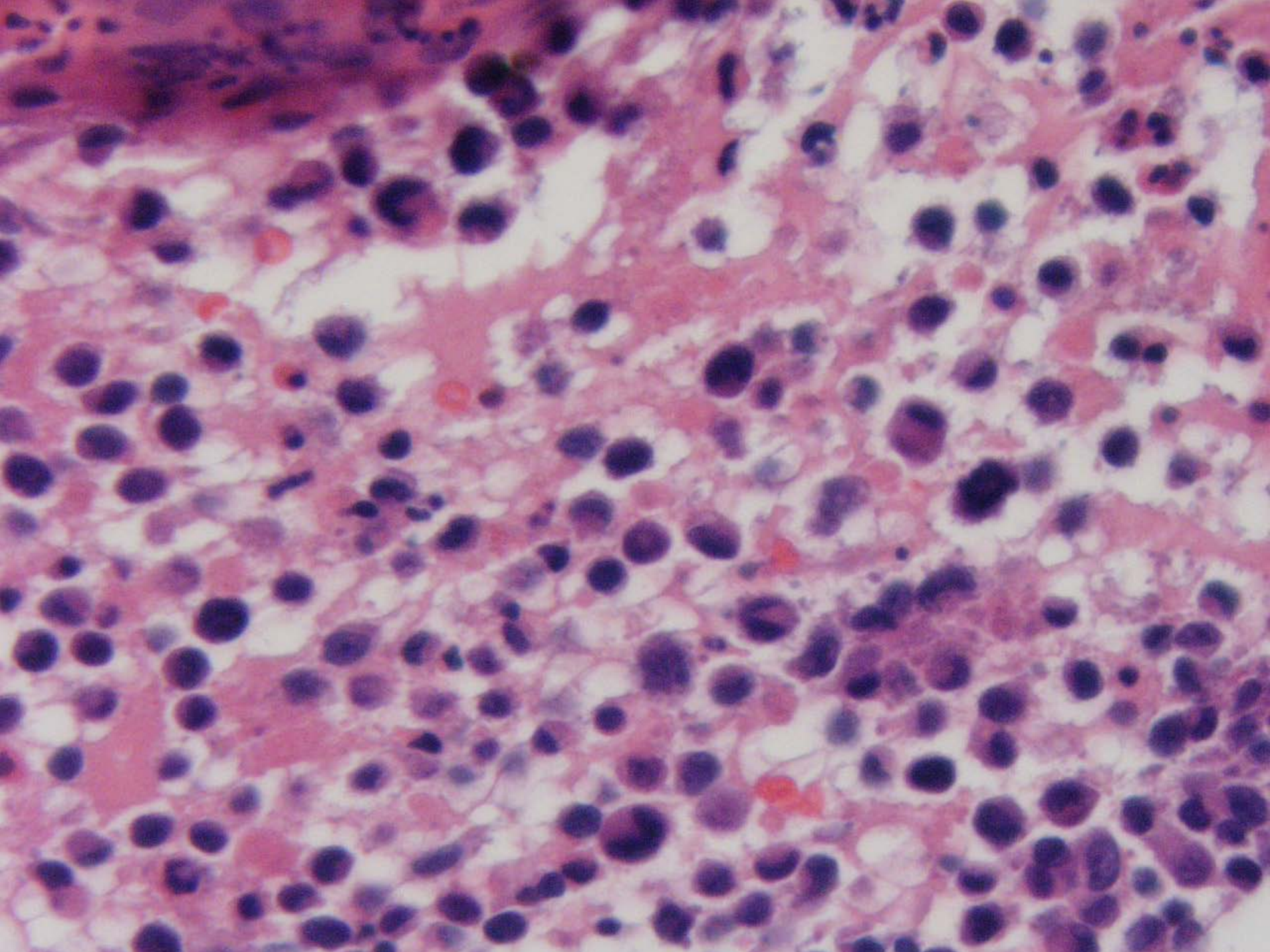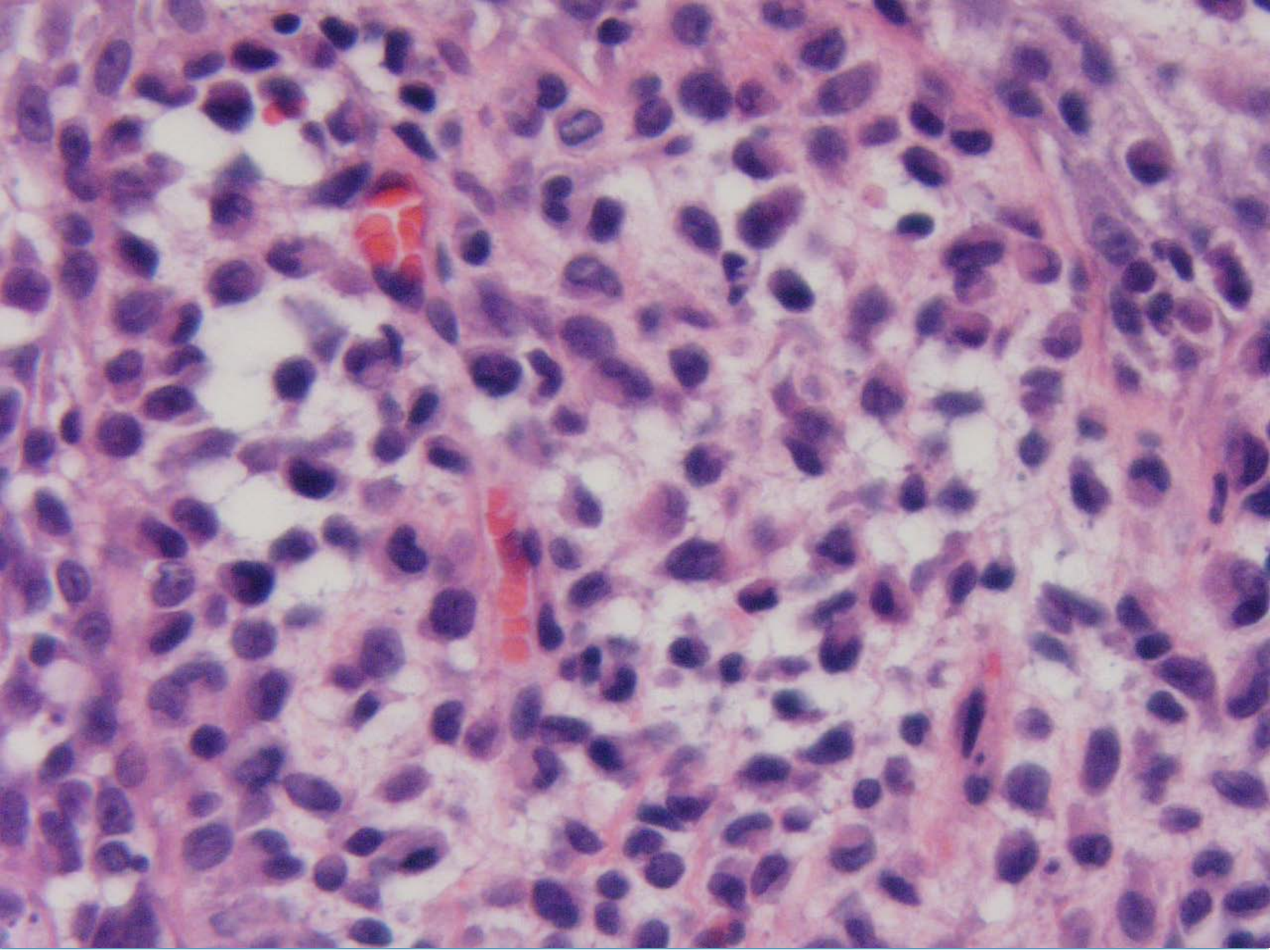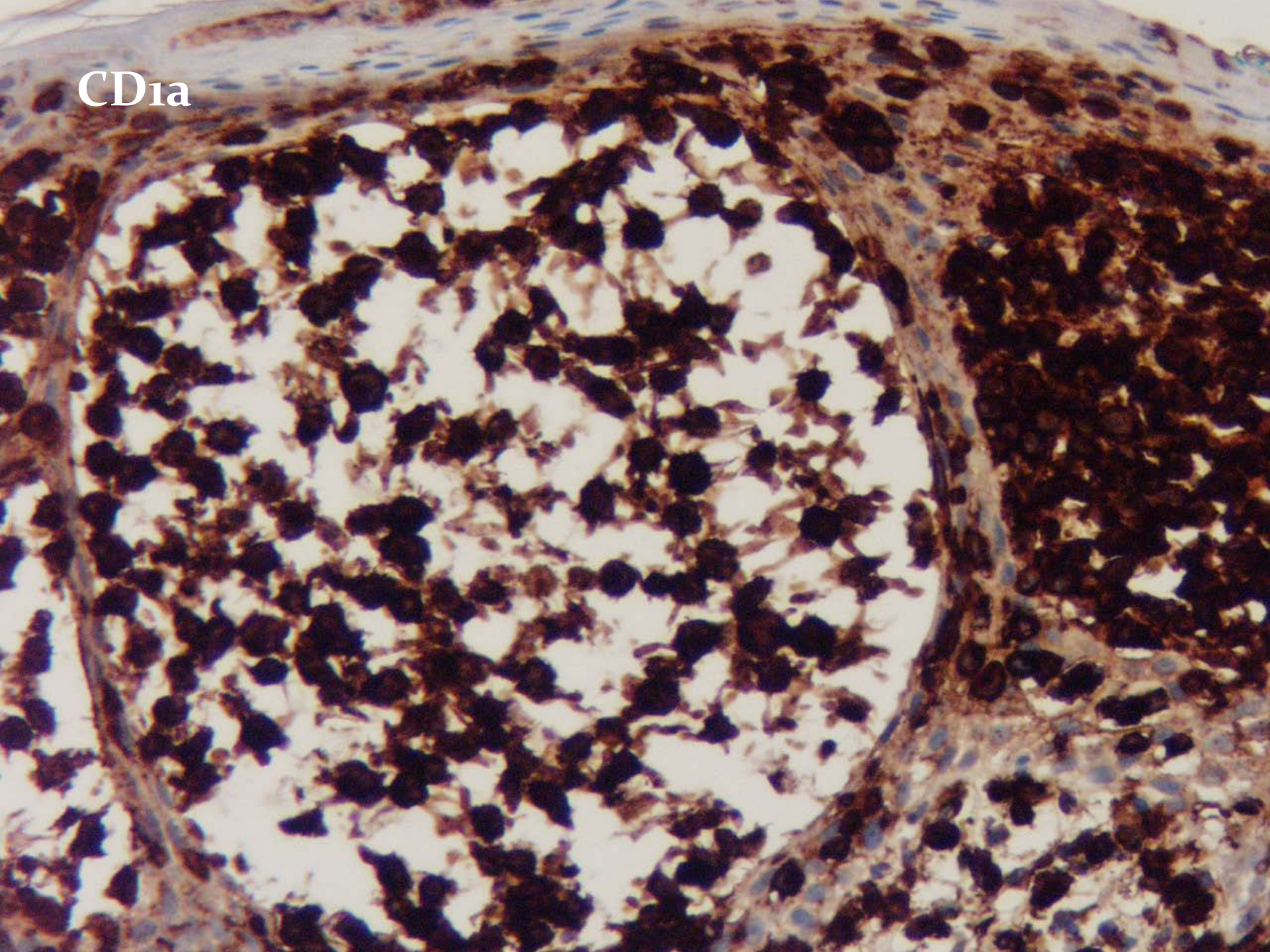


# Langerhans Cell Histiocytosis (Histiocytosis X)

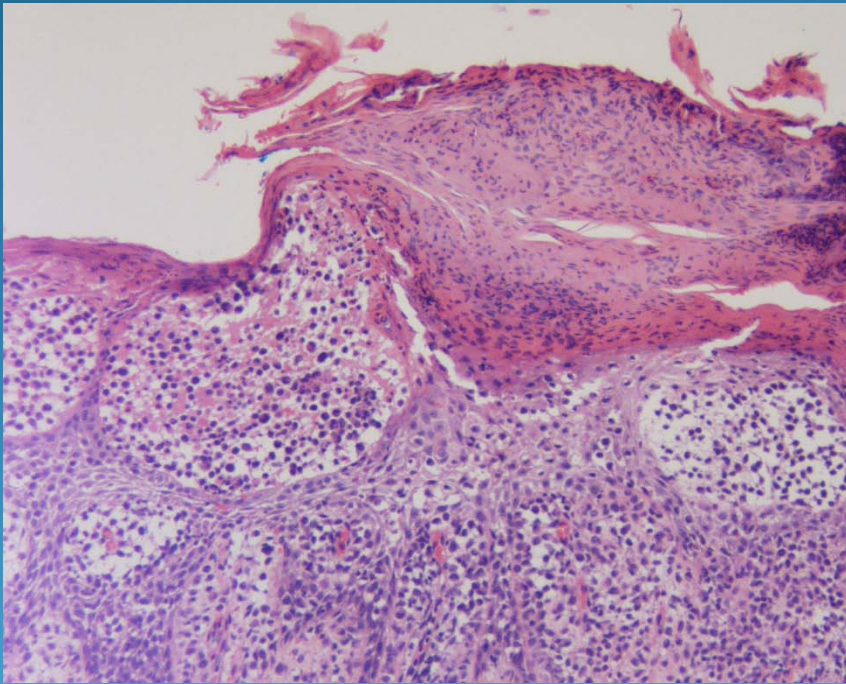


CD1a





# Pearls



- Lichenoid infiltrate
- May have extensive dermal edema
- Large cells with reniform nuclei (kidney bean shaped)